

CHIRURGIE

# Základní operace tlustého střeva a konečníku

Prof. MUDr. Mojmír Kasalický, CSc.

---

---

---

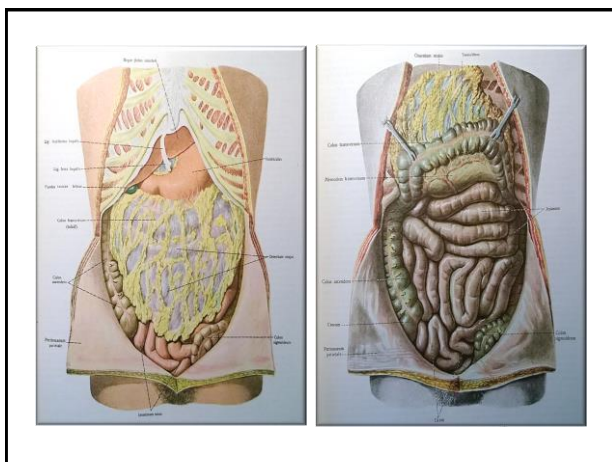
---

---

---

---

---



---

---

---

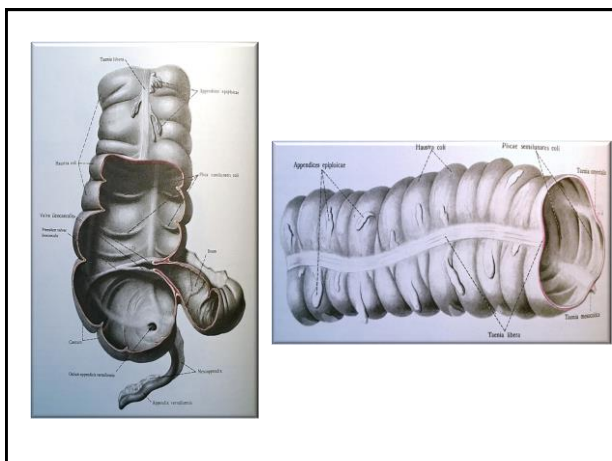
---

---

---

---

---



---

---

---

---

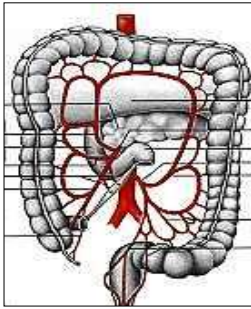
---

---

---

---

## Cévní zásobení



- A. mesenterica superior
- A. mesenterica inferior
- A. rectalis inferior
  - (a. ilica int.-a. pudenda int.)

---

---

---

---

---

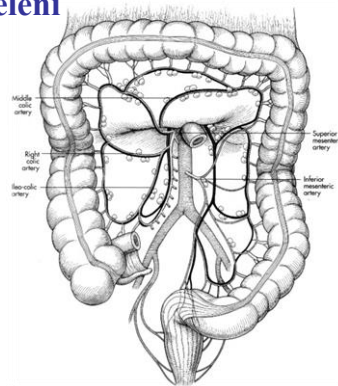
---

---

---

## Anatomické dělení

- Caecum
  - Appendix vermiformis
- Colon ascendens
- Colon transversum
- Colon descendens
- Colon sigmoideum
- Rectum




---

---

---

---

---

---

---

---

## Typy operací

- Appendectomy
- Colotomy
  - polypectomy
- Colostomy
  - Axialis
  - Terminalis
  - Biluminalis
- Hemicolectomy
- Colectomy
- Resectio
  - Transversi
  - Sigmoidei
  - Recti
- Amputatio
  - recti abdomino-perinealis

---

---

---

---

---

---

---

---

## Radikální chirurgické výkony

- Resekční výkon– dostatečně radikální rozsah resekce
- Snaha o provedení co nejradikálnější lymfadenectomie

---



---



---



---



---

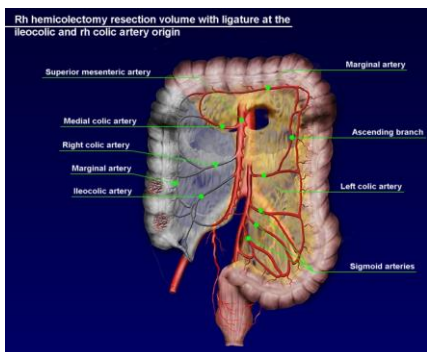


---



---

## Hemicolektomia dextra




---



---



---



---



---

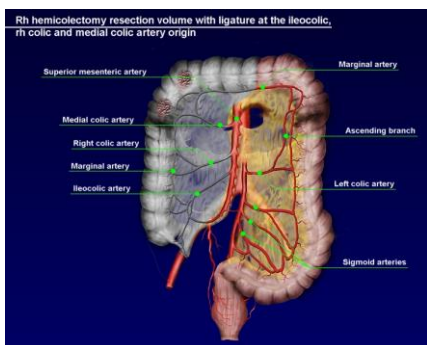


---



---

## Hemicolektomia dextra




---



---



---



---



---

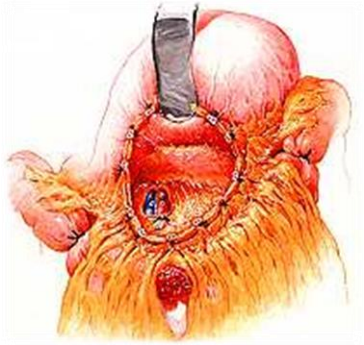

---



---

### Resectio transversi



---

---

---

---

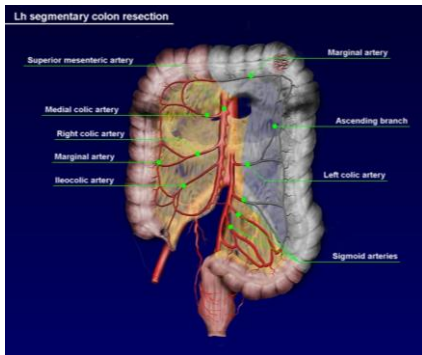
---

---

---

---

### Hemicolectomia sinistra



---

---

---

---

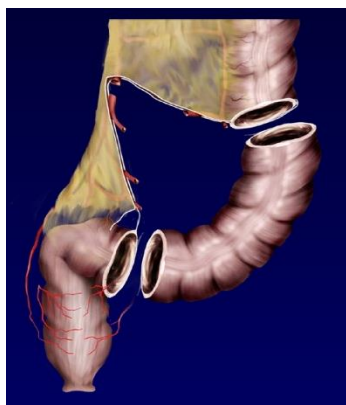---

---

---

---

### Resectio sigmoidei



---

---

---

---

---

---

---

---

### Urgentní operace tlustého střeva

- Subtotální kolektomie
  - ileorekto-anastomosa
  - Ileostomie, slepý uzávěr rekta
- Akutní resekce
- Hartmannova operace
- Kolostomie

---

---

---

---

---

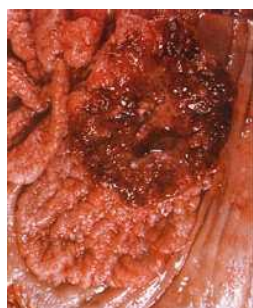---

---

---

### Urgentní operace tlustého střeva

- Ileus
- Zánět
- Tumor
  - Perforace
  - Nekróza




---

---

---

---

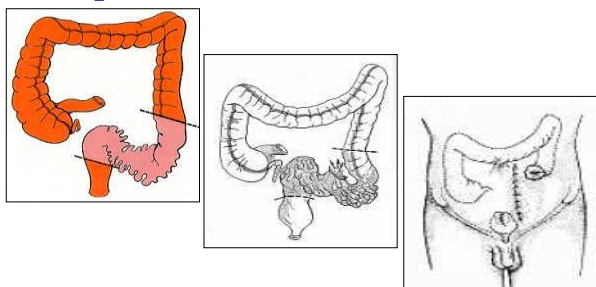
---

---

---

---

### Diverticulitis – Operatio sec Hartmann




---

---

---

---

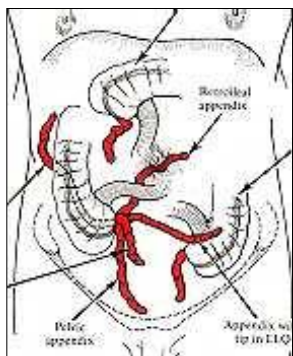
---

---

---

---

### Lokalizace appendixu



---

---

---

---

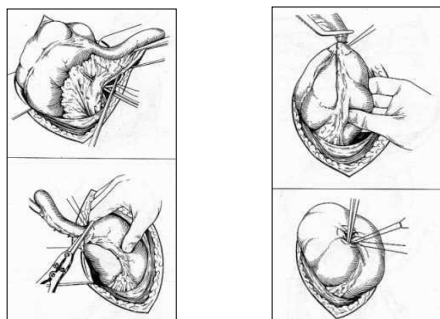
---

---

---

---

### Appendectomy



---

---

---

---

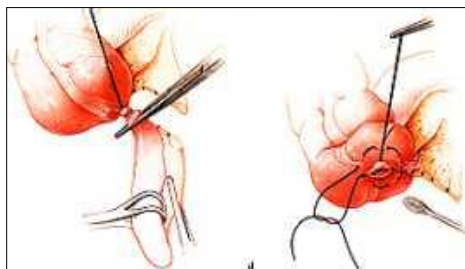
---

---

---

---

### Appendectomy



---

---

---

---

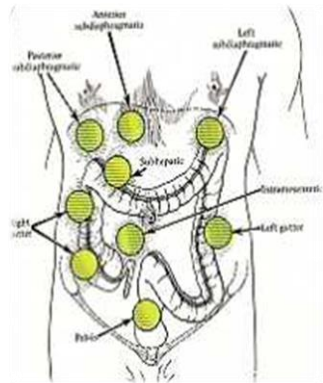
---

---

---

---

Appendectomy  
- komplikace




---

---

---

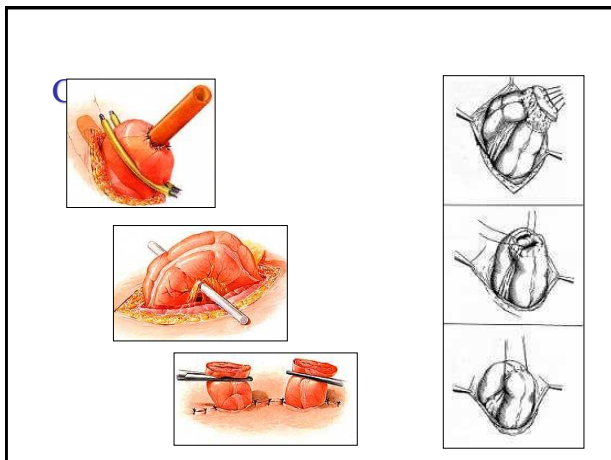
---

---

---

---

---




---

---

---

---

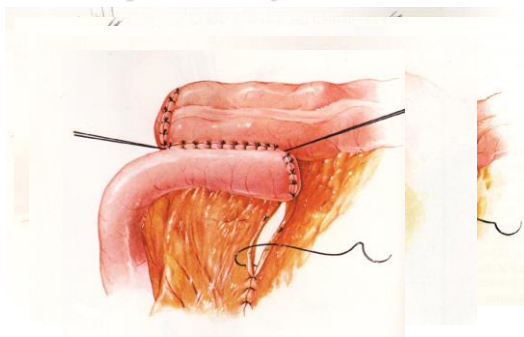
---

---

---

---

Anastomóza - obnovení kontinuity  
střeva po resekci jeho části




---

---

---

---

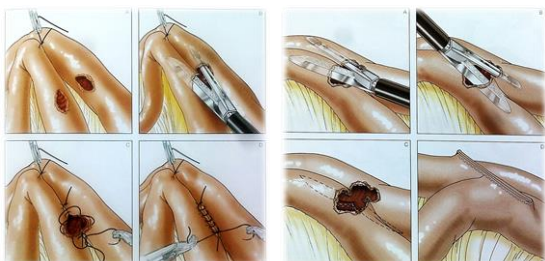
---

---

---

---

### Anastomóza – mechanická (staplerová)



---

---

---

---

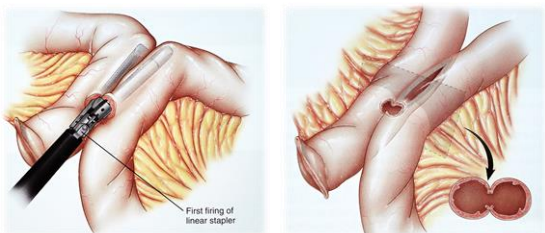
---

---

---

---

### Anastomóza – mechanická (staplerová)



---

---

---

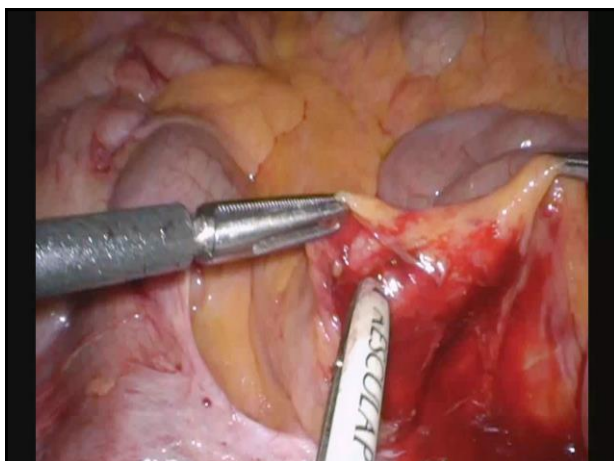
---

---

---

---

---



---

---

---

---

---

---

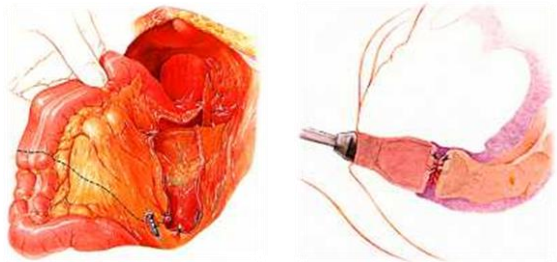
---

---





## Nízká resekce rekta




---



---



---



---



---



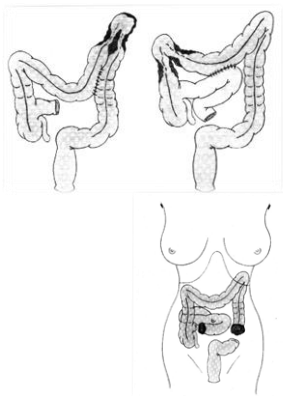
---



---

## Paliativní výkony

- Paliativní resekční výkony
- Bypassová operace
  - anastomozy
- Derivační operace
  - stomie
- Kryalizace, elektrokoagulace, laser a pod.




---



---



---



---



---



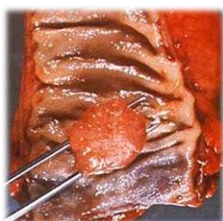---



---

## Anus

- Haemorrhoides
- Fissura ani
  - Acuta, chronica
- Abscessus
  - perianalis, periproctalis
- Fistula perianalis, periproctalis
- Prolapsus ani et recti
- Tumor
  - Benignus- adenoma, hamartom
  - Malignus - carcinoma




---



---



---



---



---



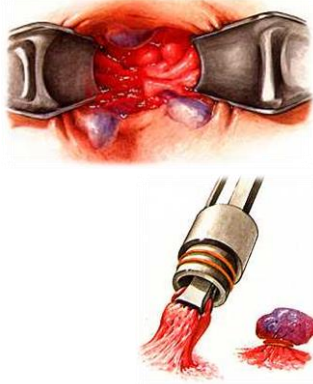
---



---

### Haemorhoides

- Sklerotizace
- Laser
- Elektrokoagulace
- Kryalizace
- Baronova ligatura




---

---

---

---

---

---

---

---

### Haemorhoides

- Incisio
- Whitehead
- Transcisio
  - Stapler
- Milligan-Morgan




---

---

---

---

---

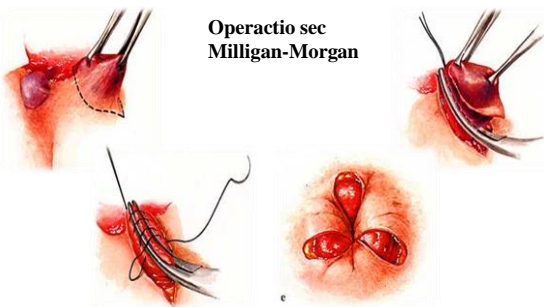
---

---

---

### Haemorhoides

Operactio sec  
Milligan-Morgan




---

---

---

---


---

---

---

---

### LONGOVA OPERACE



---

---

---

---

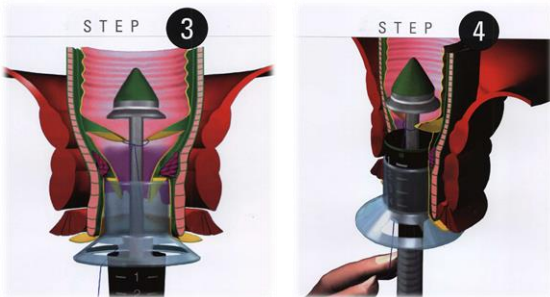
---

---

---

---

### LONGOVA OPERACE



---

---

---

---

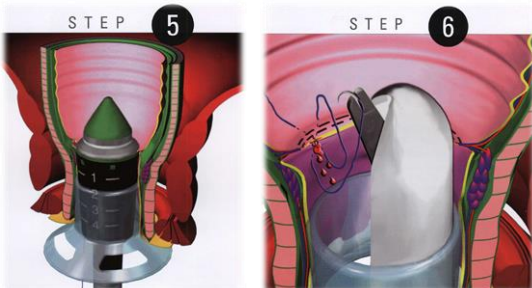
---

---

---

---

### LONGOVA OPERACE



---

---

---

---

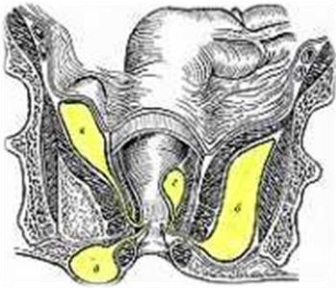
---

---

---

---

### Abscessus periproctalis



- Perianalis
- Pelvirectalis
- Ischioirectalis
- Submucosus

---

---

---

---

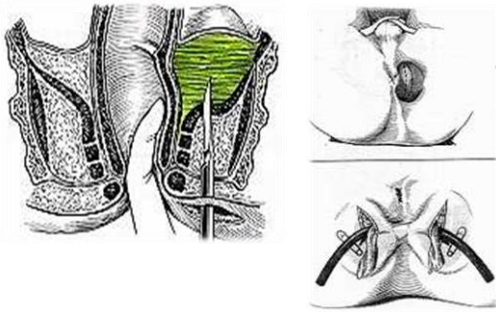
---

---

---

---

### Abscessus periproctalis



---

---

---

---

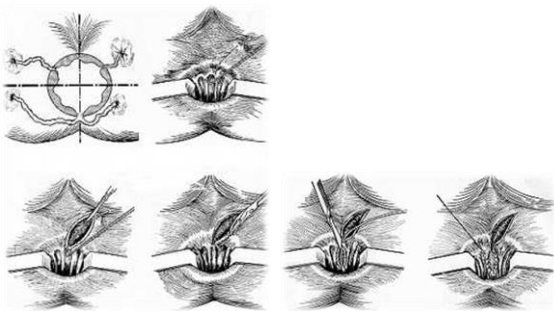
---

---

---

---

### Fistulas perianales



---

---

---

---

---

---

---

---