

Neuroradiologie

1/ lebka a mozek

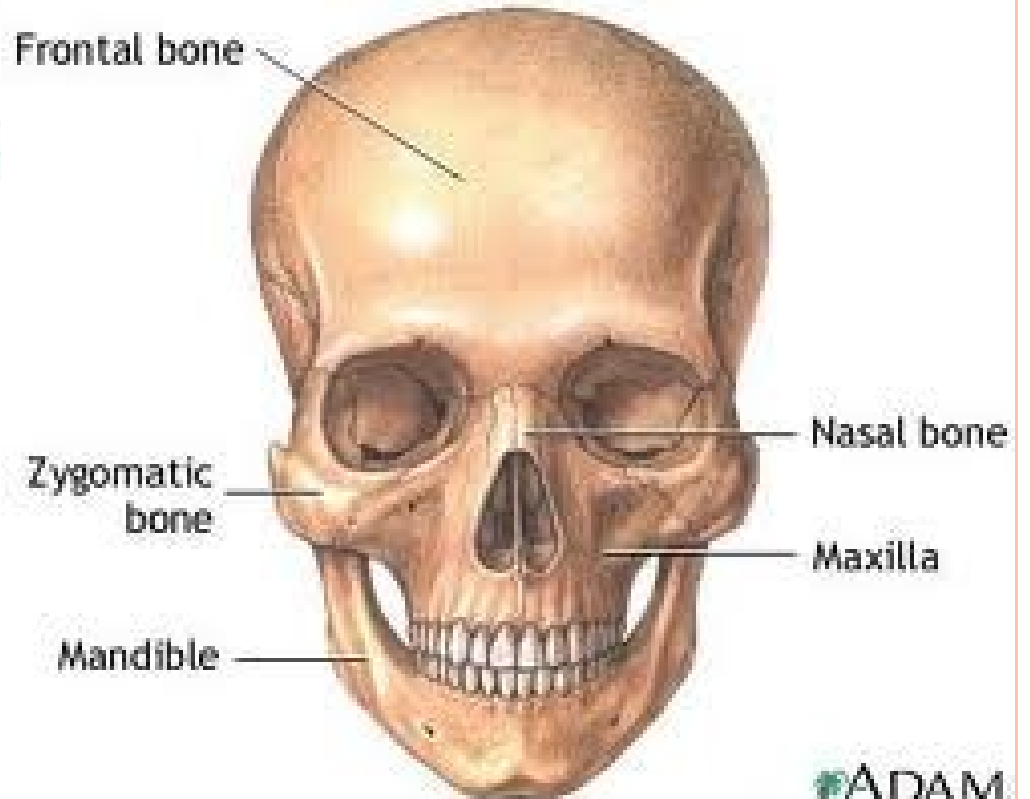
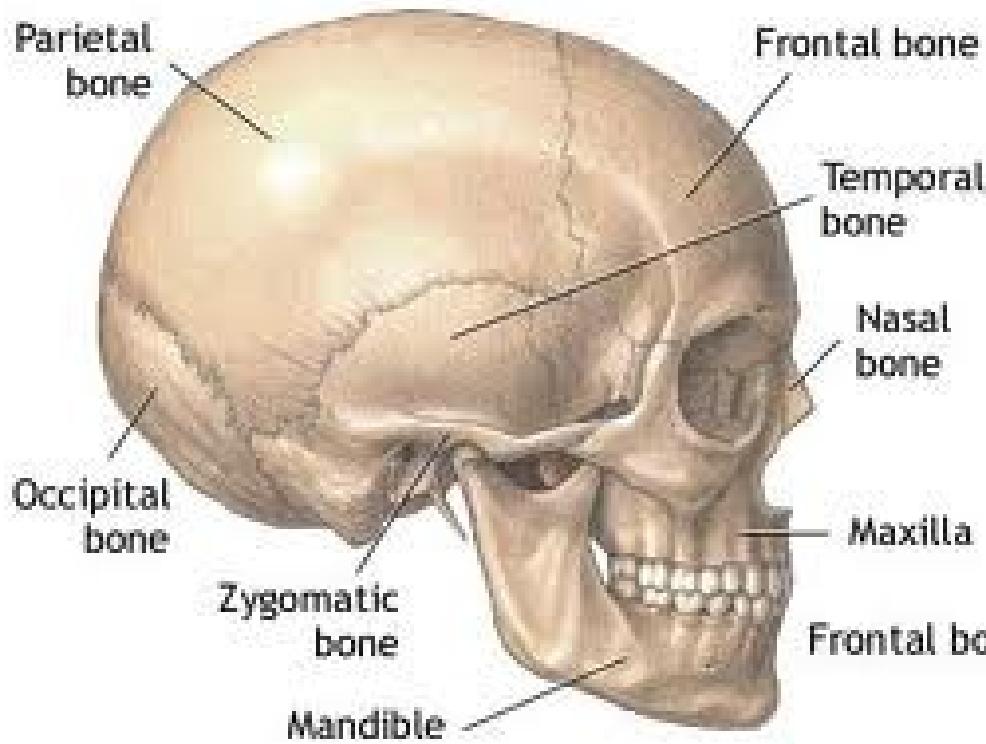
2/ páteř a páteřní kanál



ZOBRAZOVACÍ METODY

- Prostý snímek lebky
- CT
- MR
- AG
- Dopplerovská sonografie
- NM



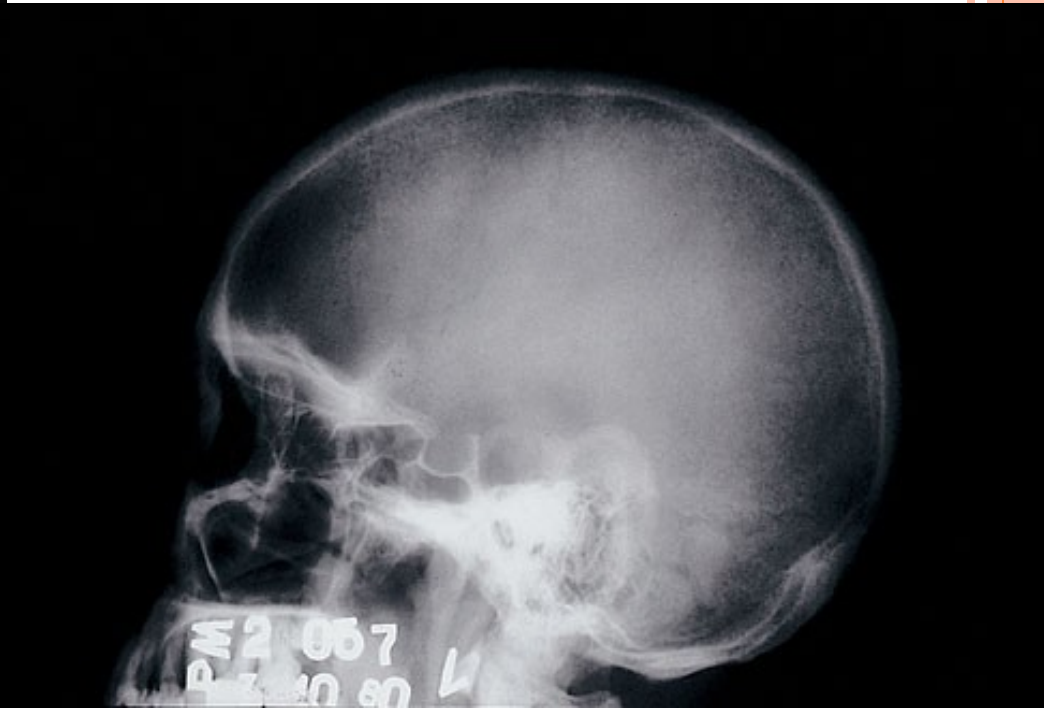
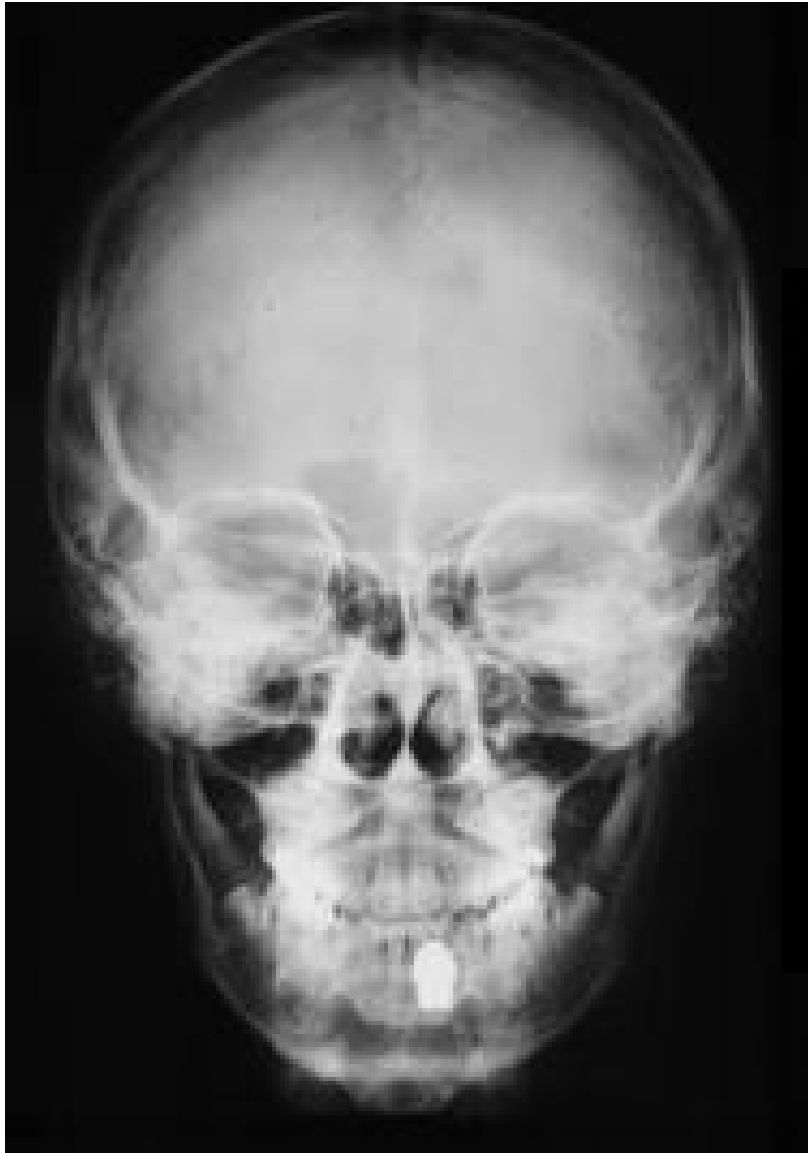
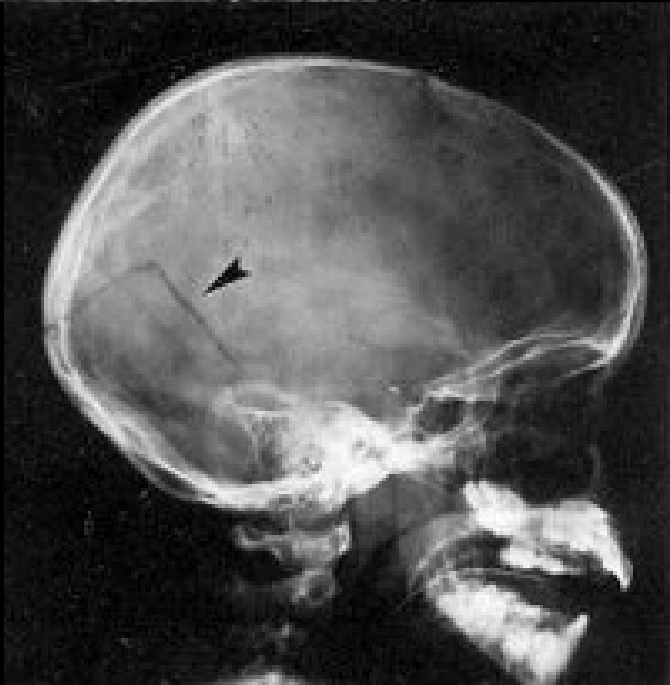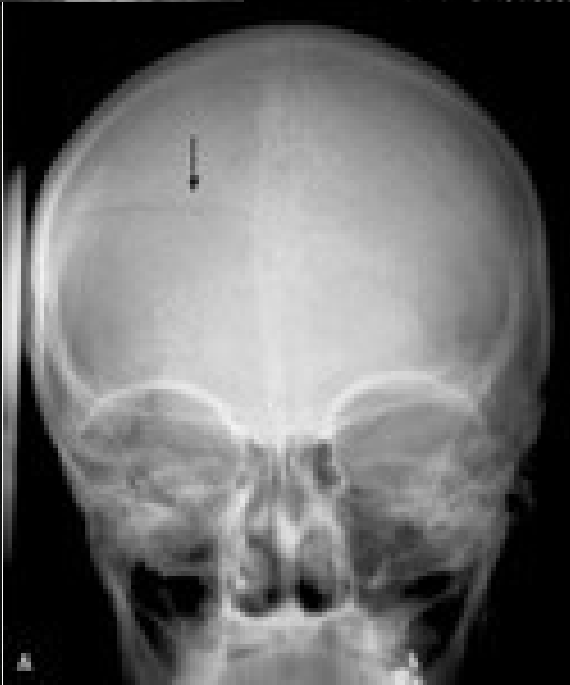
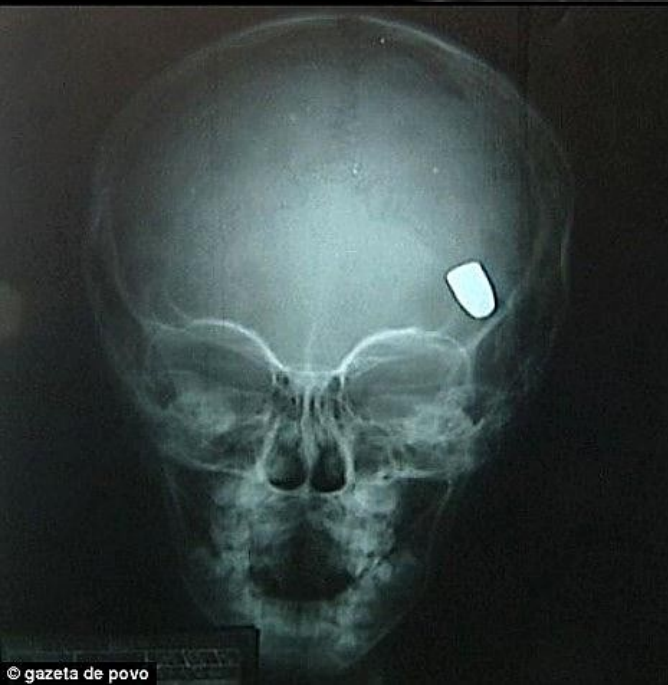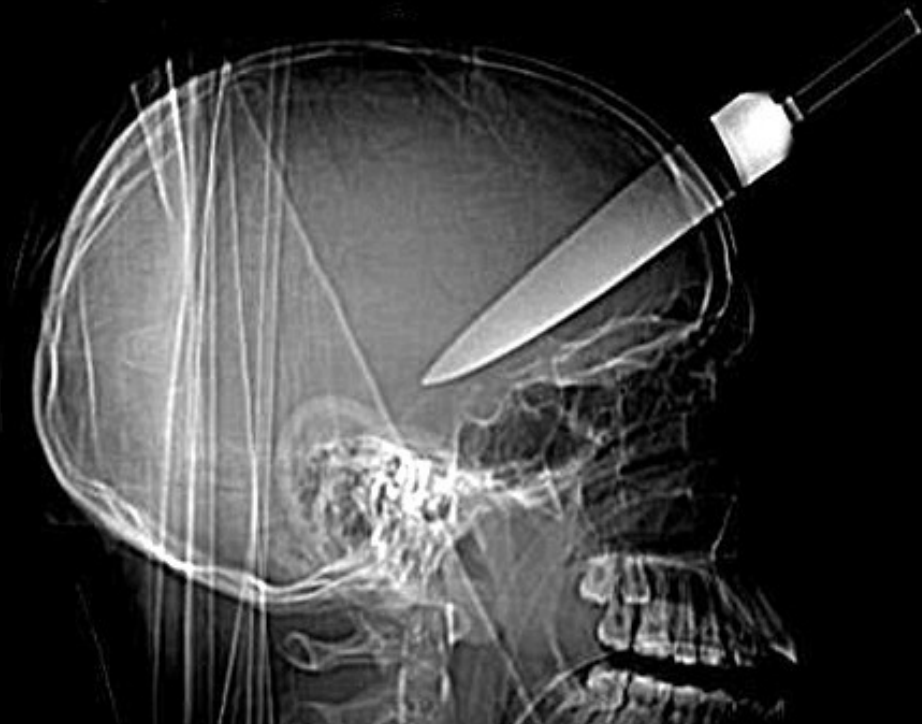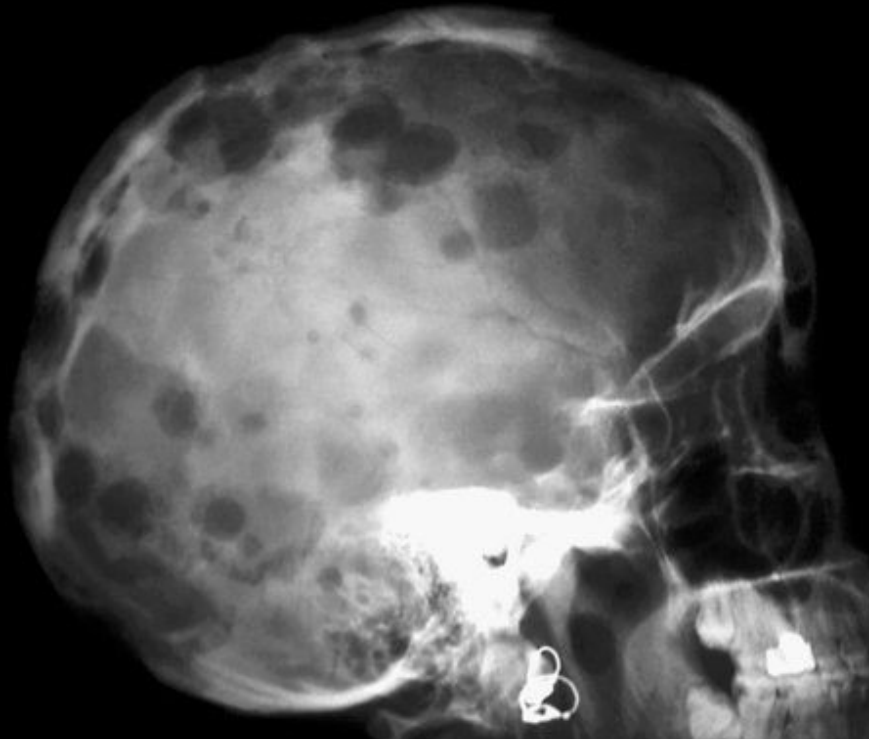PROSTÝ SNÍMEK LEBKY

- Traumatologie
- Základní onemocnění skeletu
- Zjišťování různých anomálií
- Fyziologická projasnění: švy, otisky tepen a mozkových gyrů
- Fyziologické kalcifikace



PA A BOČNÁ PROJEKCE





CT

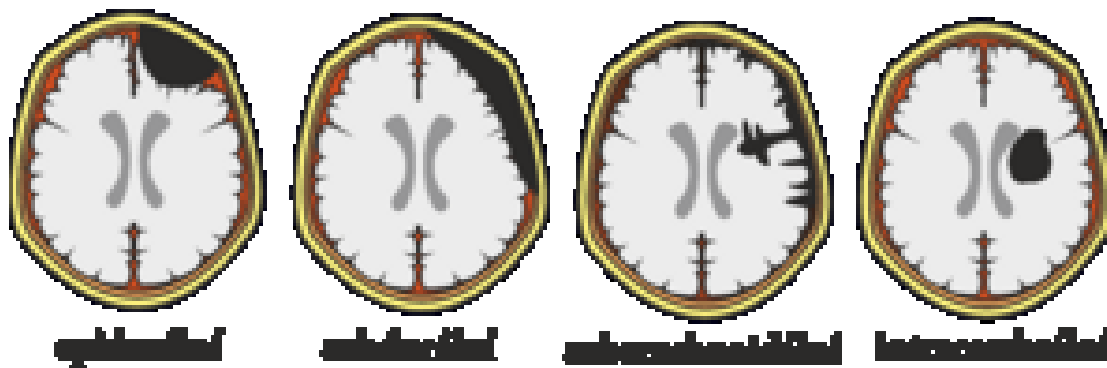
- Intrakraniální léze – TU, metastázy,
- Traumatologie – čerstvé krvácení
změny na skeletu
- CMP – perfúze
- CT AG – extrakraniální uzávěry a stenózy
cévní malformace

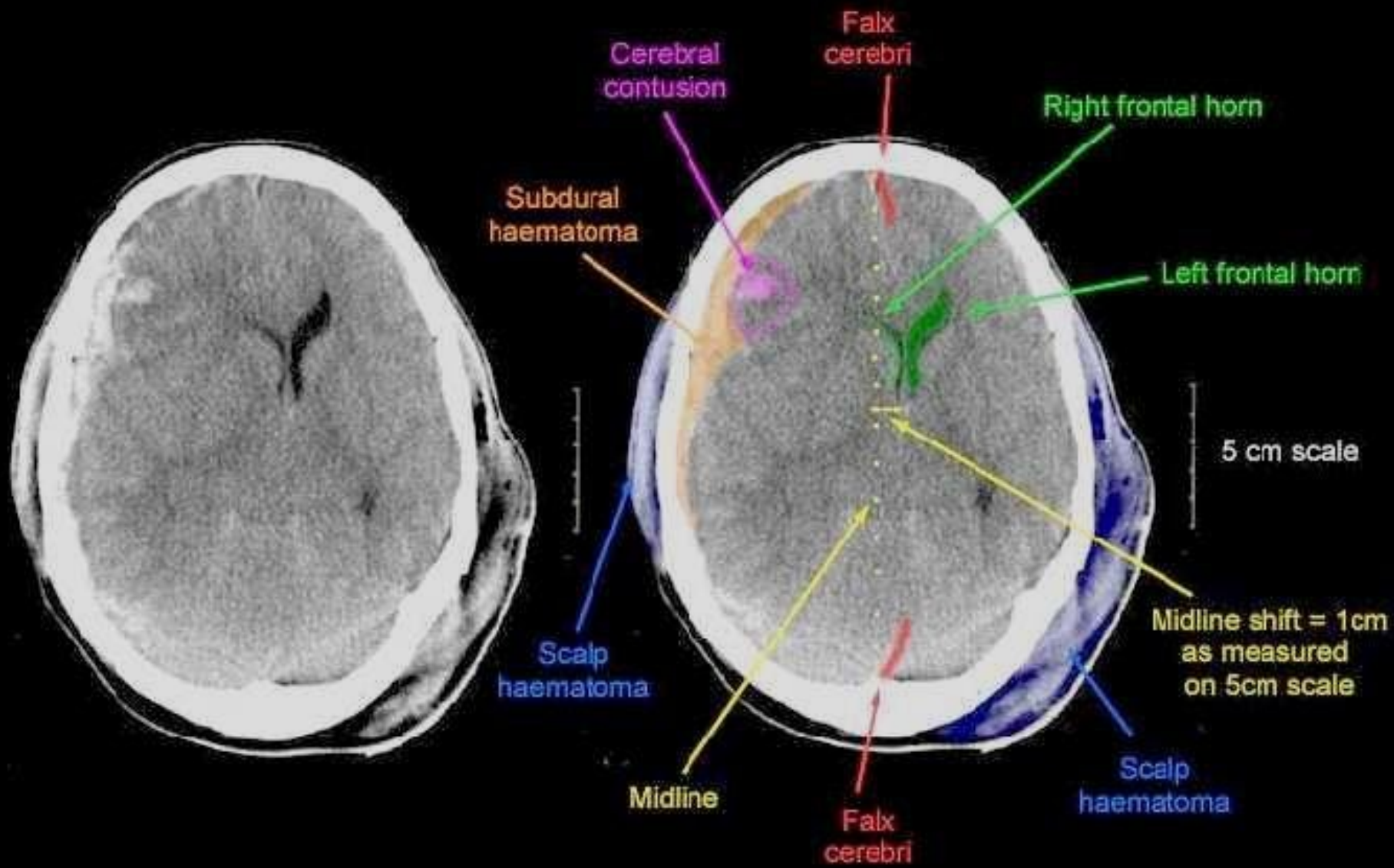


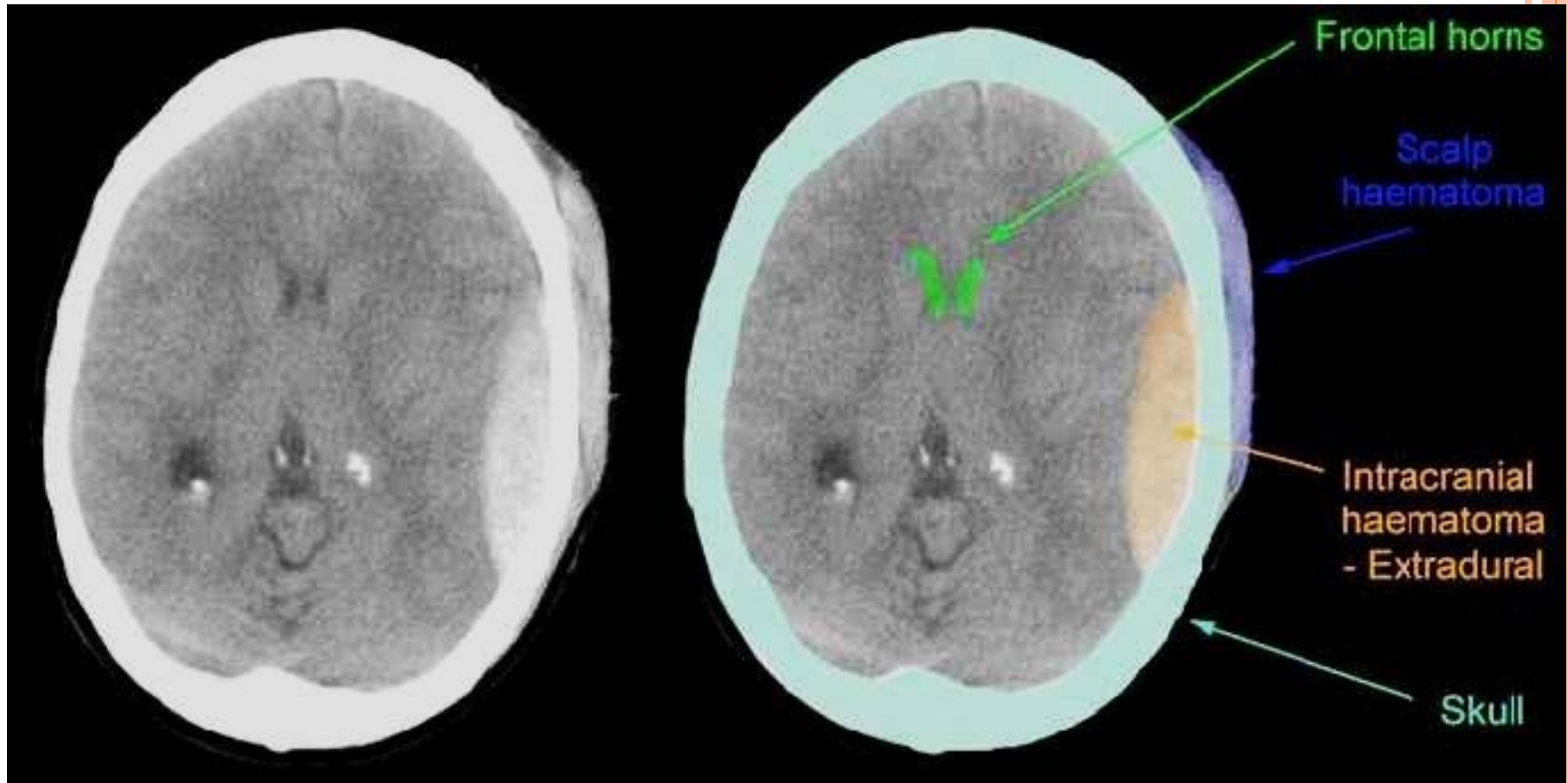
TRAUMATICKÁ KRVÁCENÍ

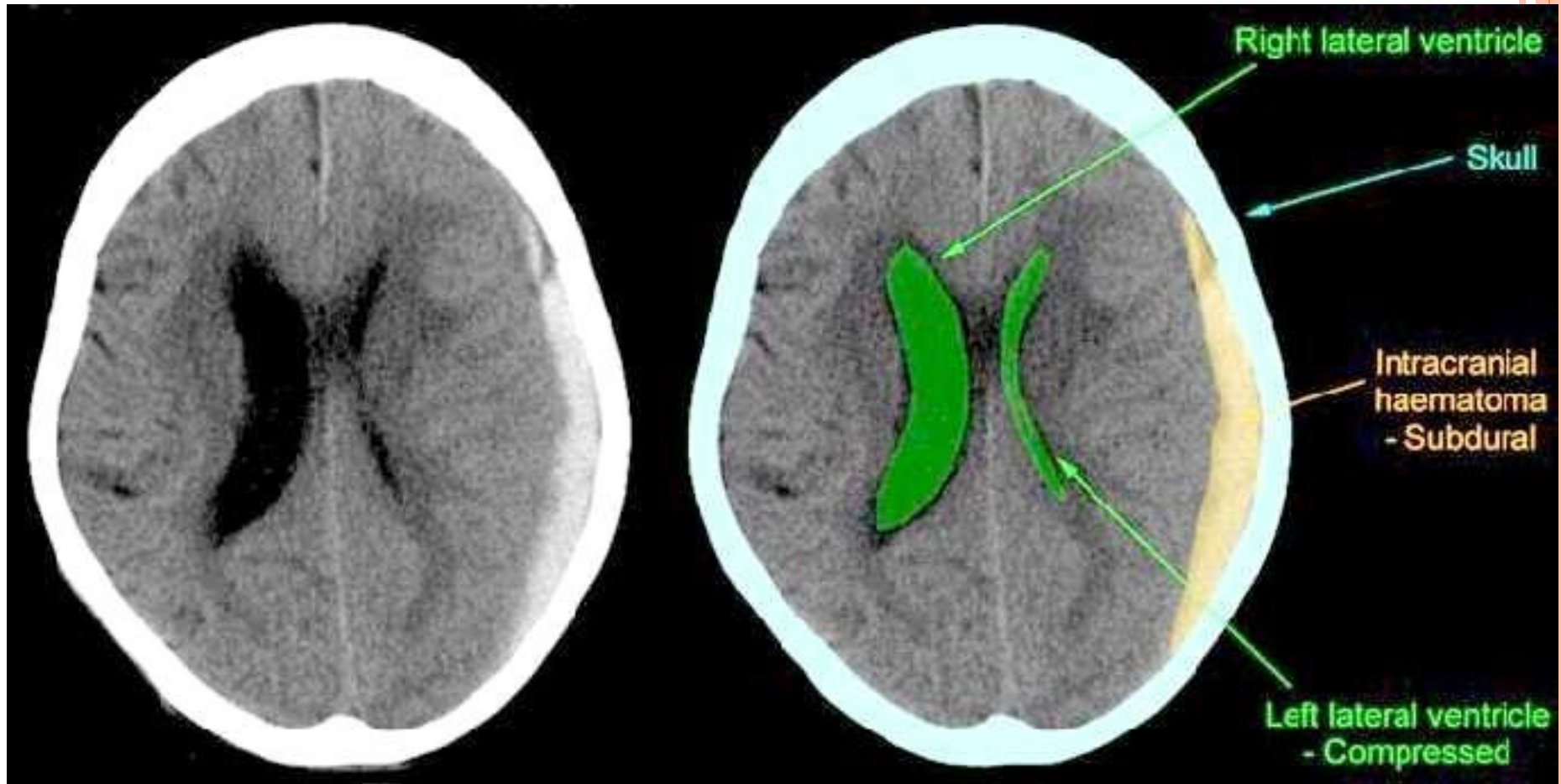
- Extraaxiální – epidurální a subdurální hematom, subarachnoideální krvácení
 - EDH – mezi kalvou a durou, často bublinky vzduchu
 - SDH – mezi durou a arachnoideou
- Intraaxiální – intracerebrální a intraventrikulární krvácení

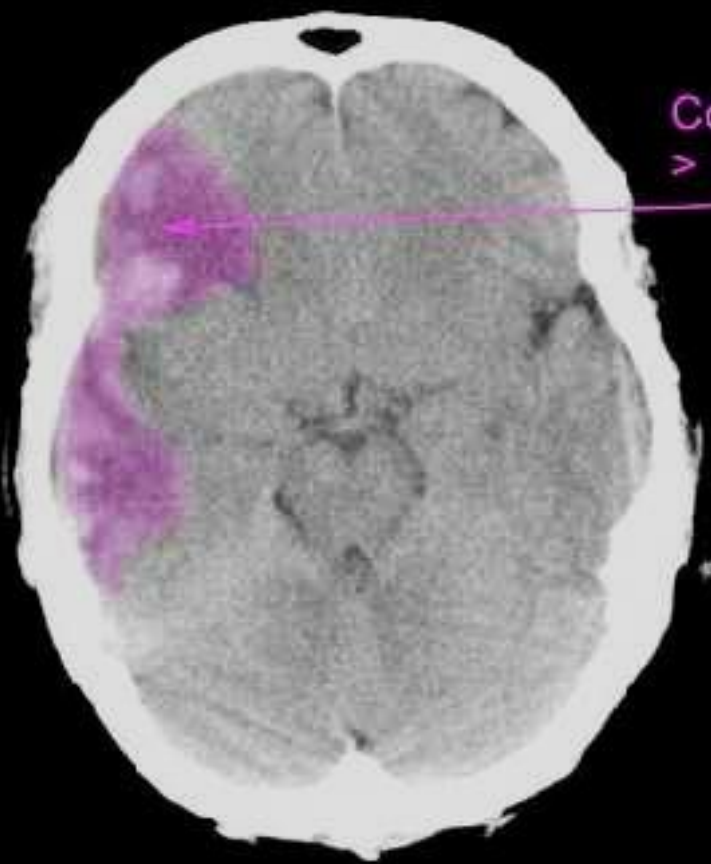
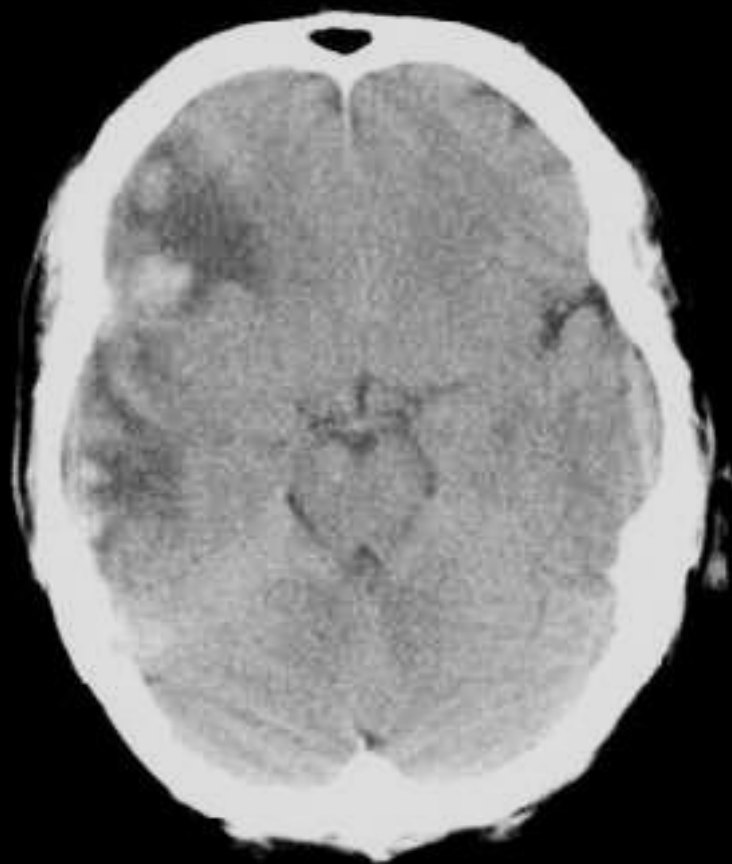
Klasifikace traumatického krvácení





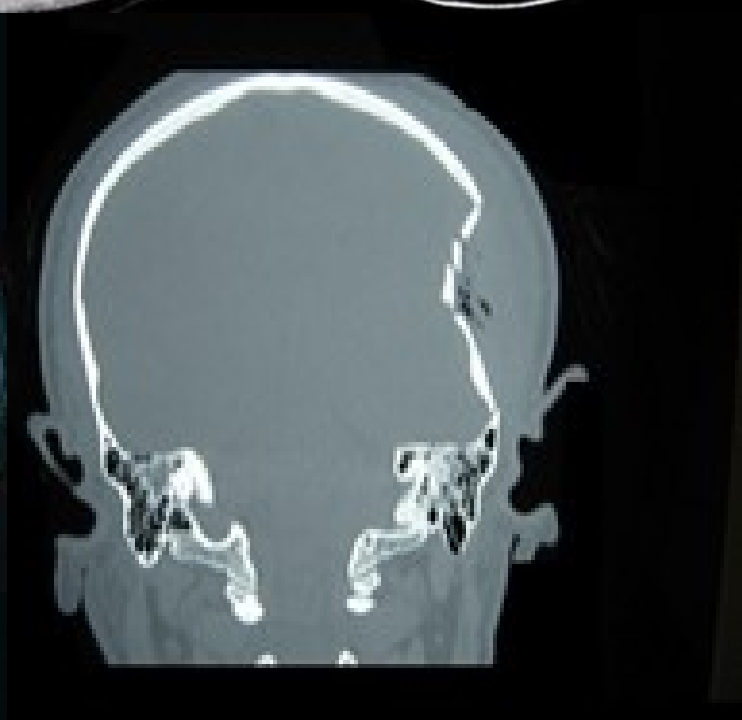
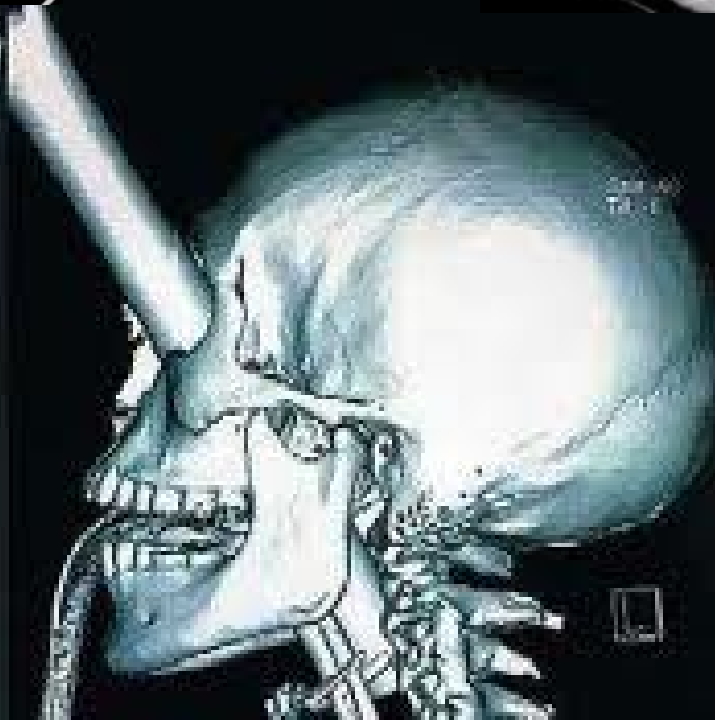
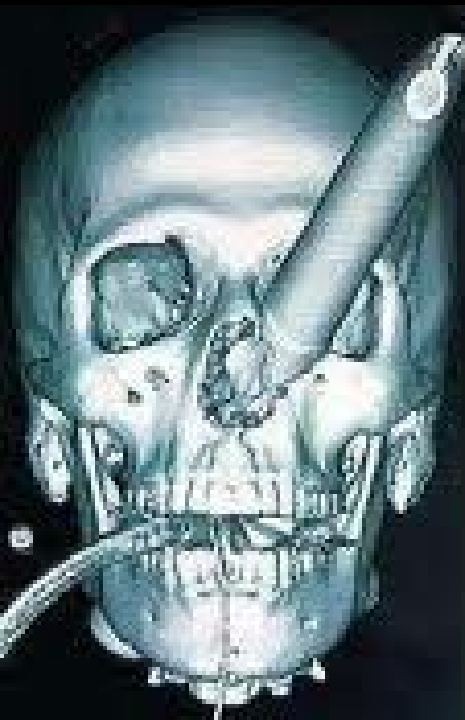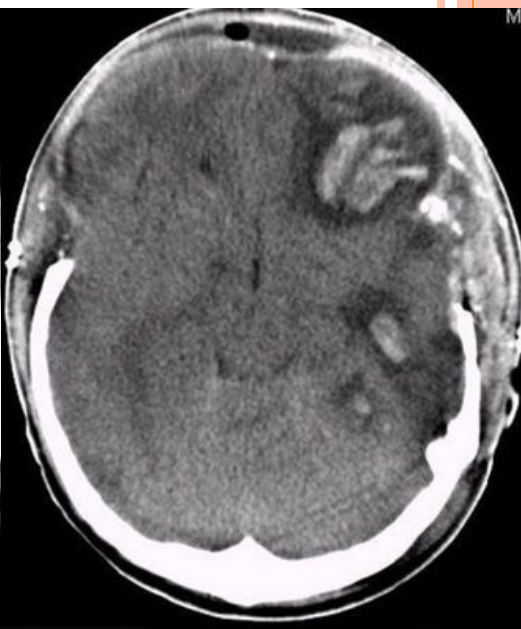
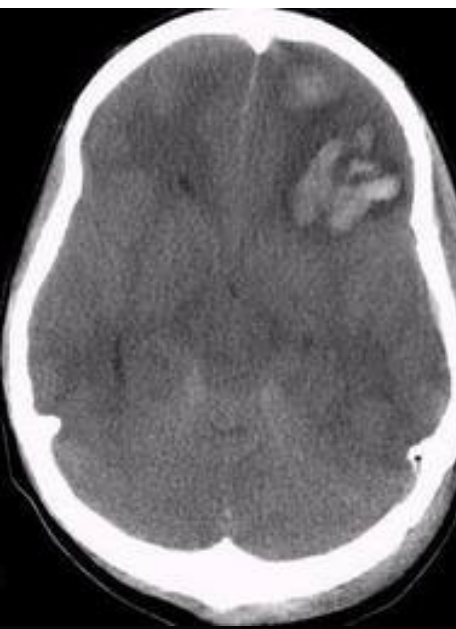
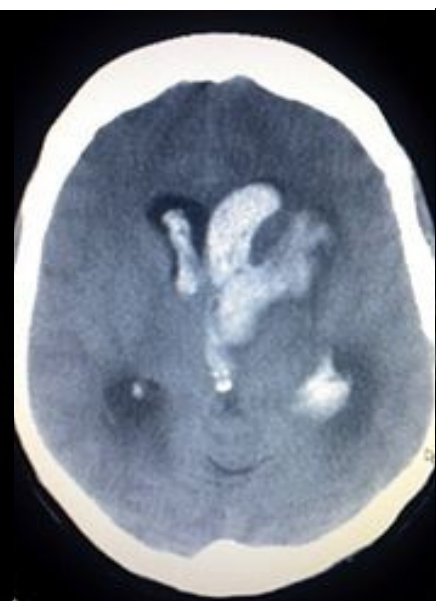
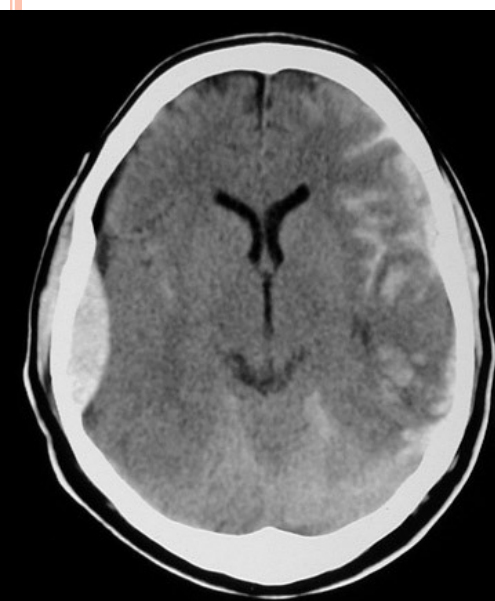


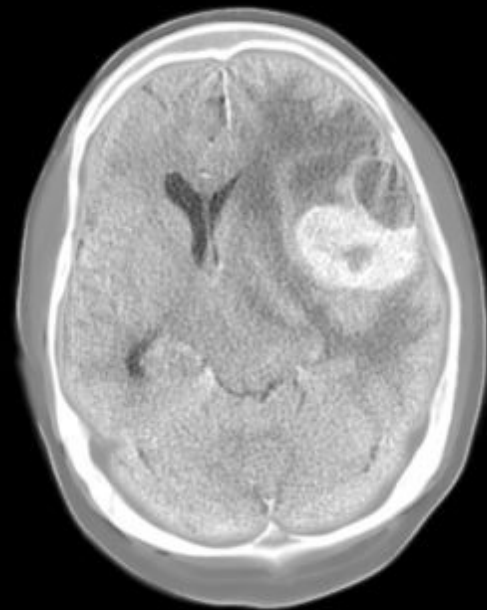

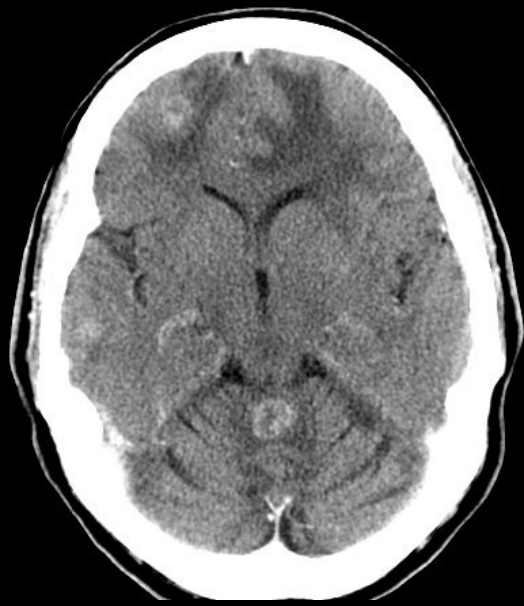
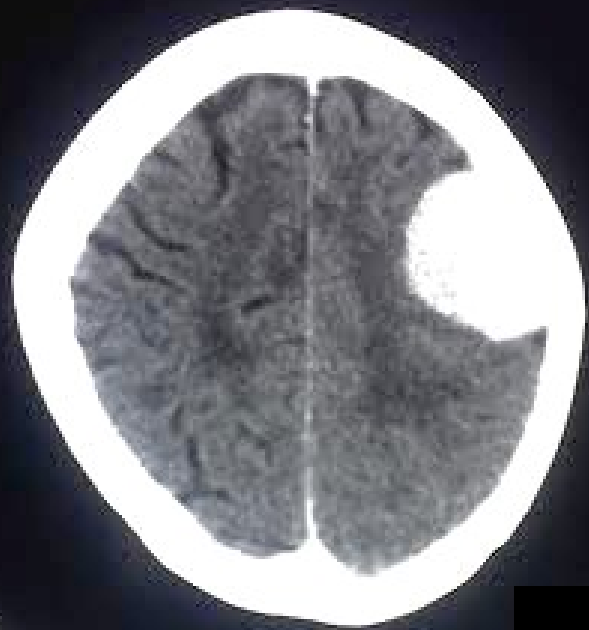

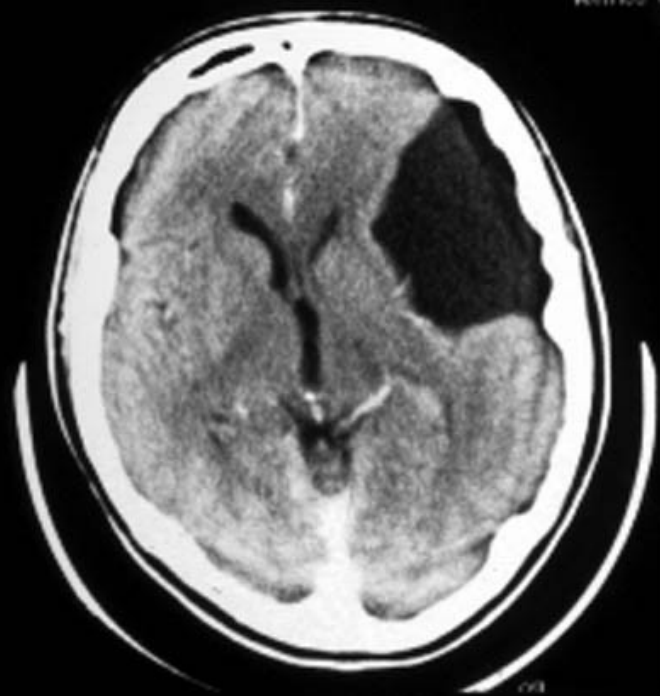
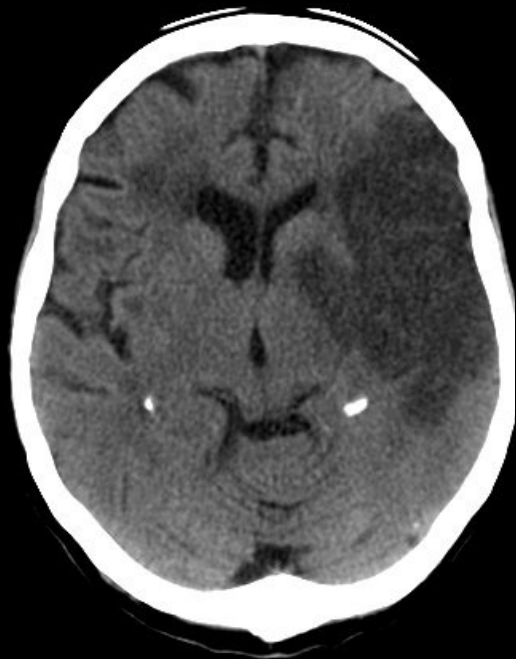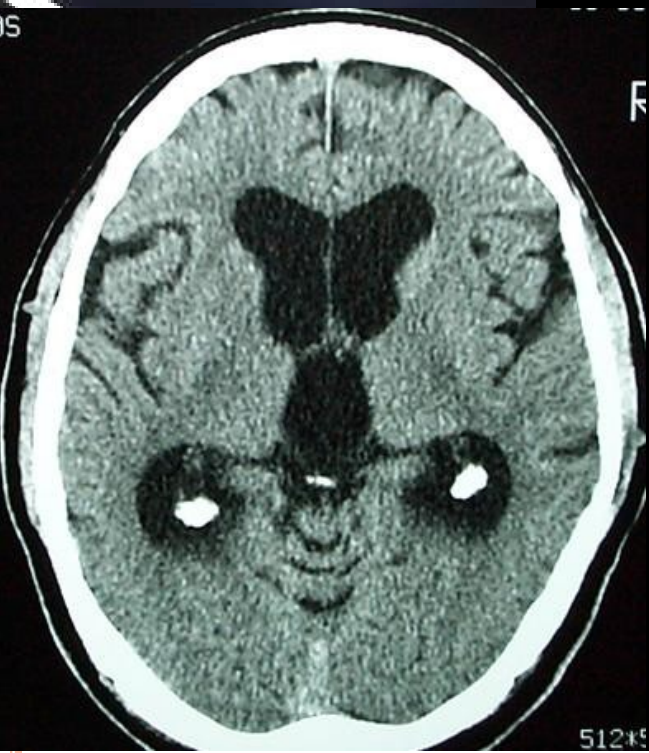Cortical contusion
> 1cm in diameter

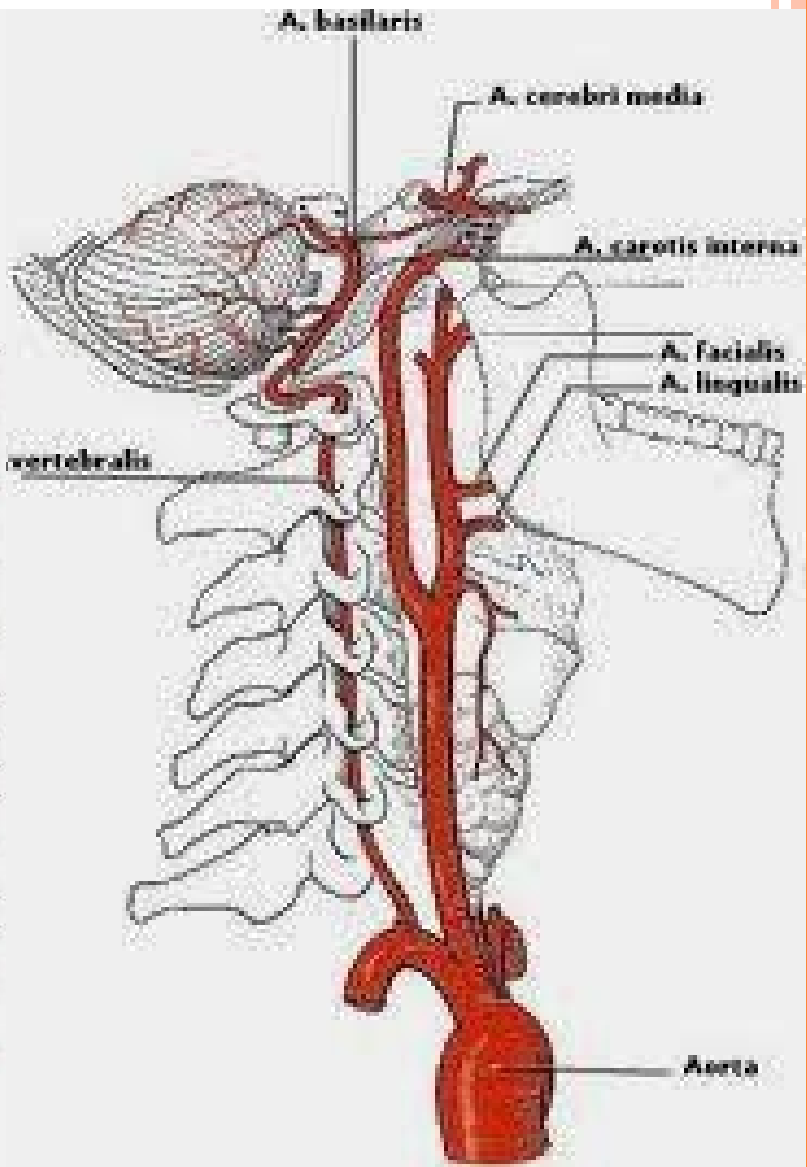
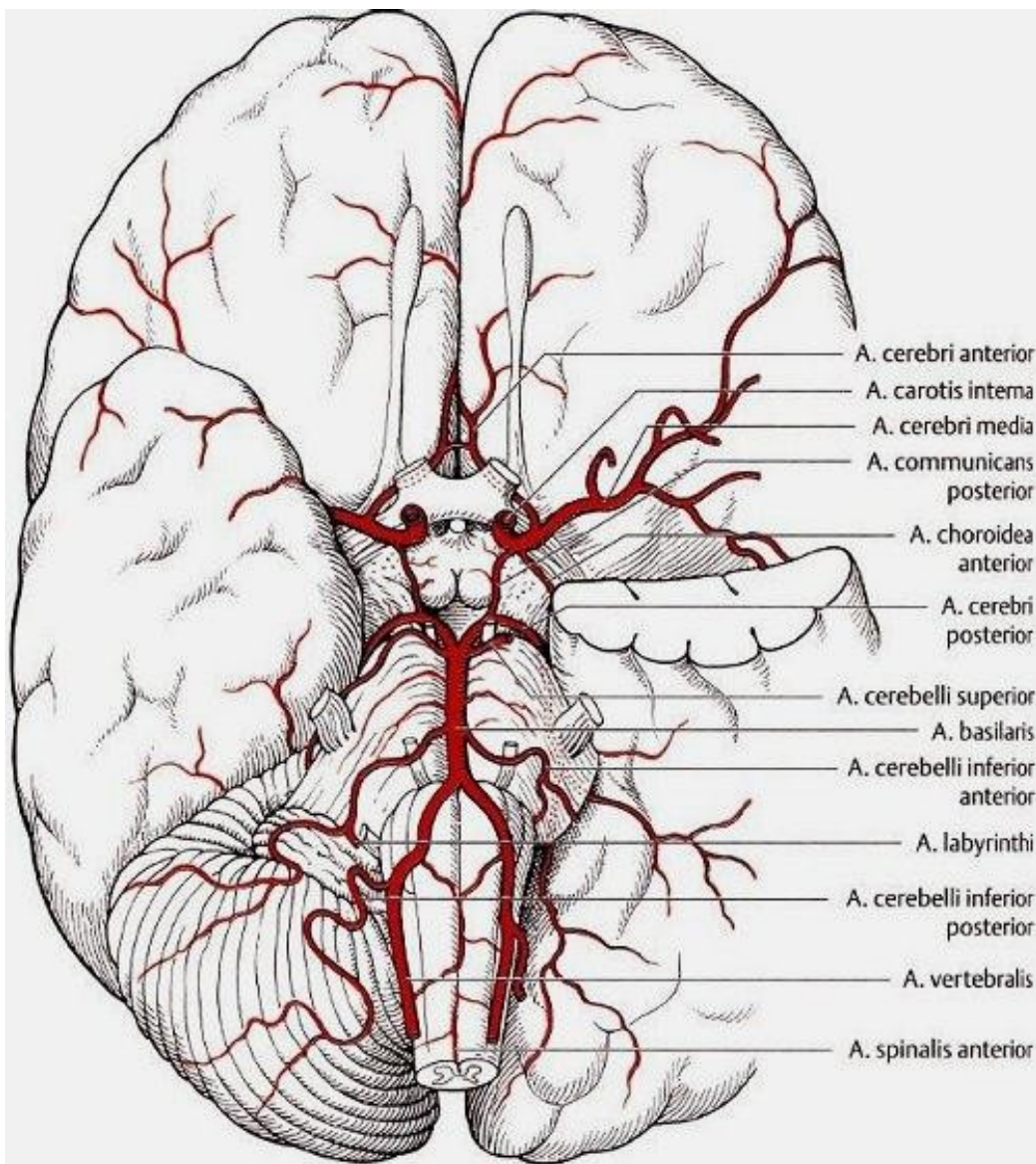


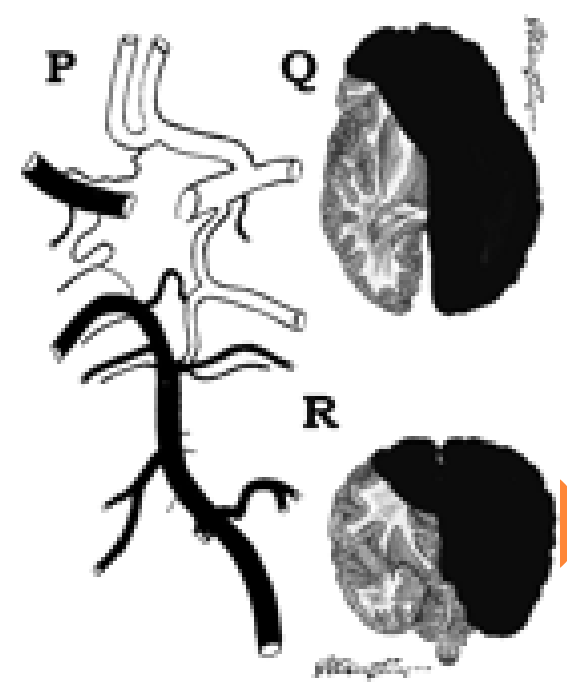
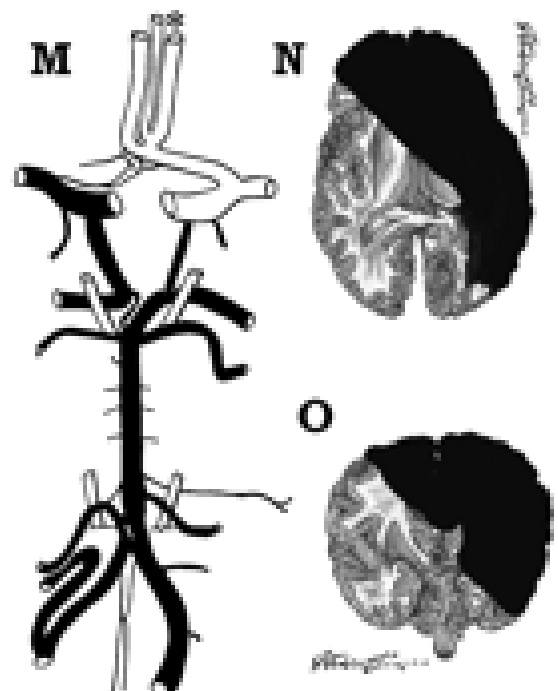
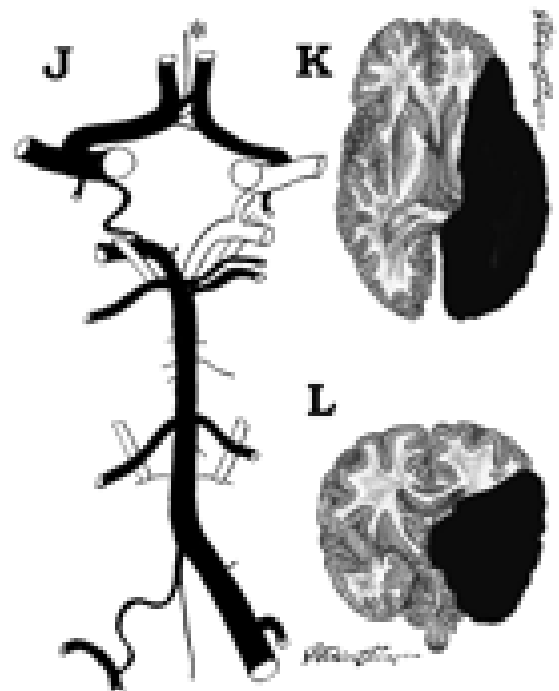
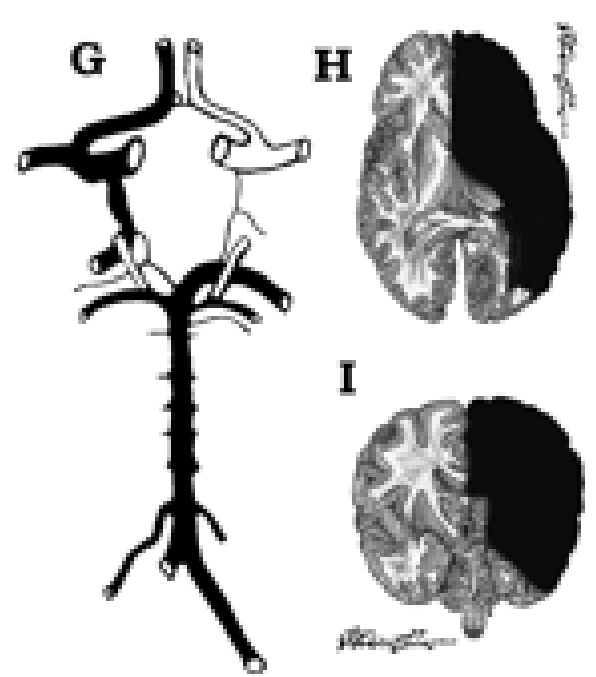
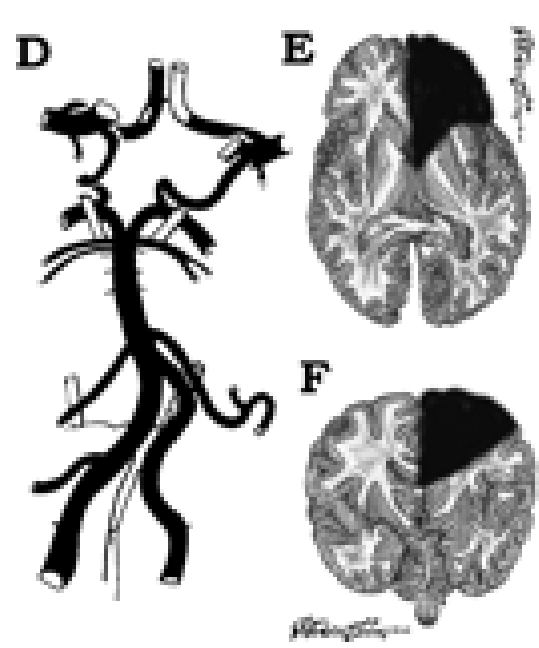
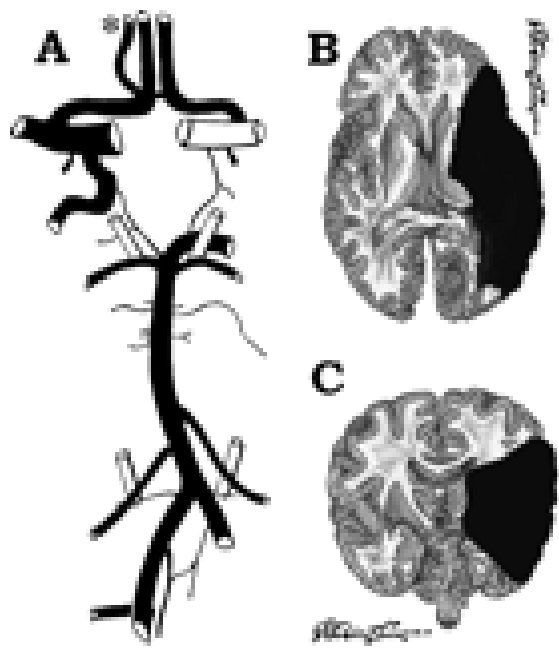


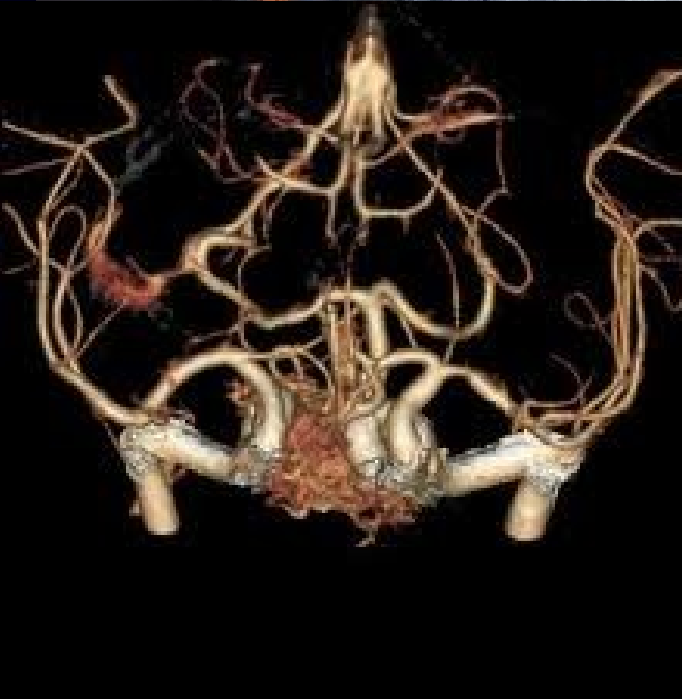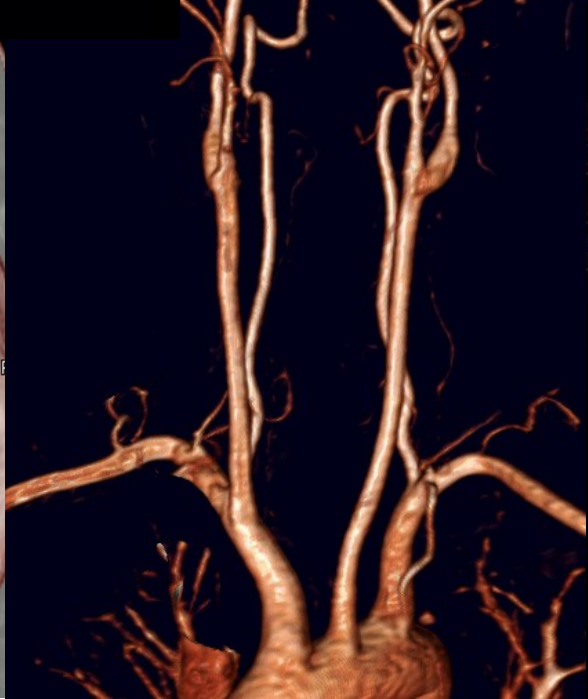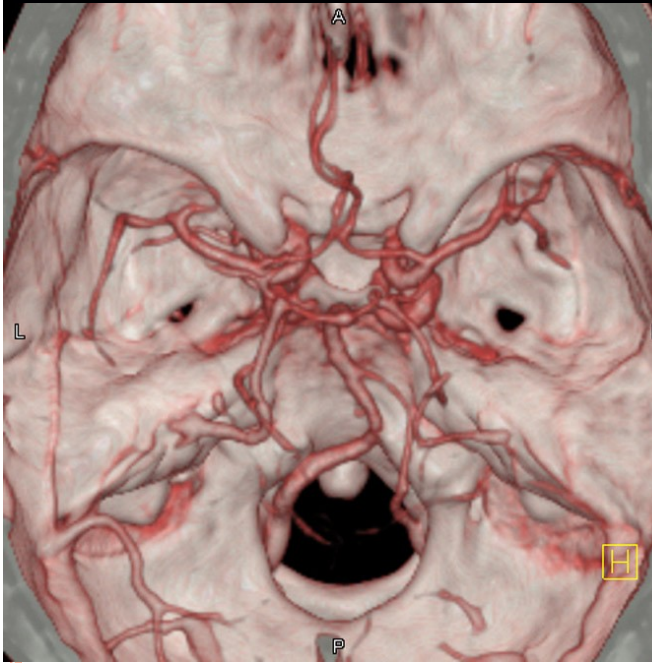
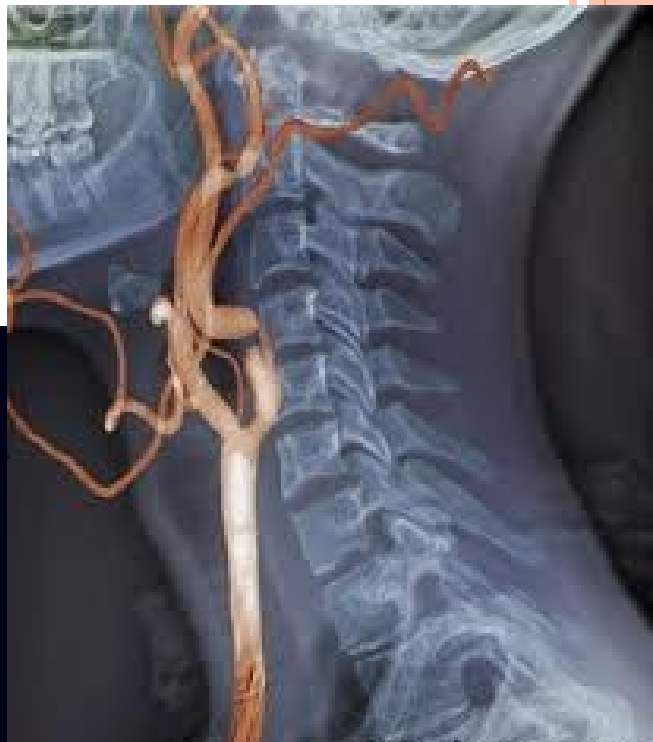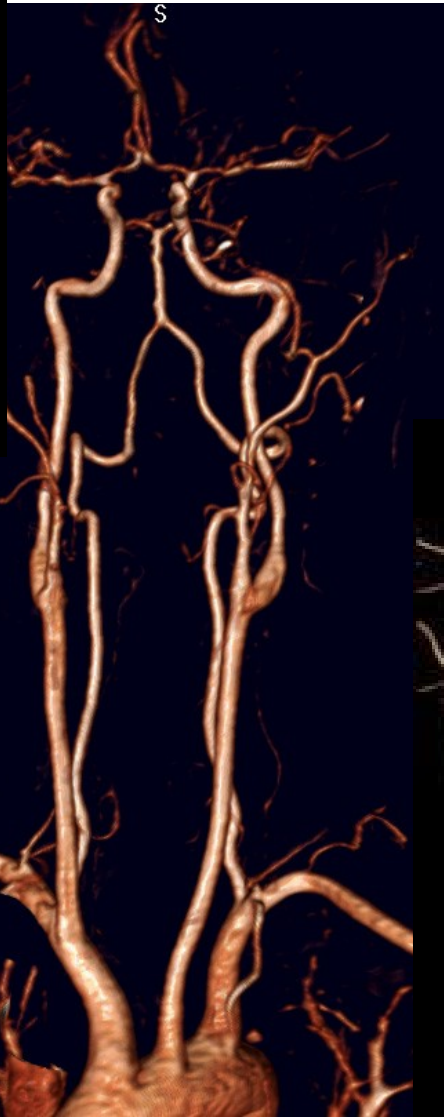


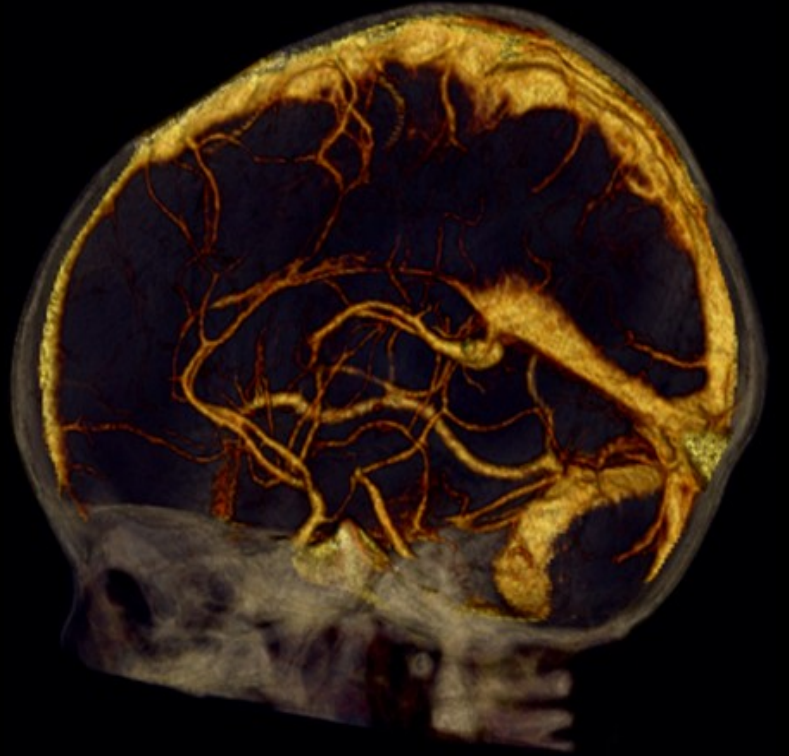SCIENCEPHOTOLIBRARY





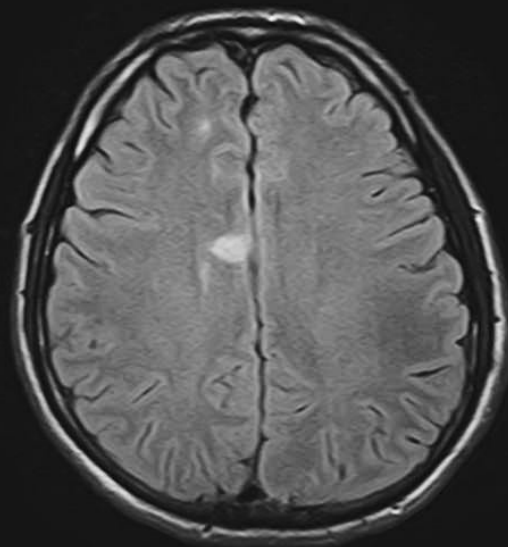
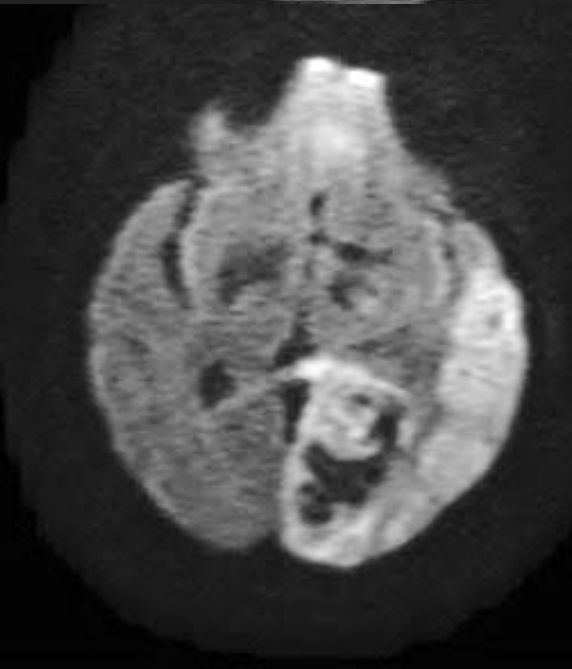
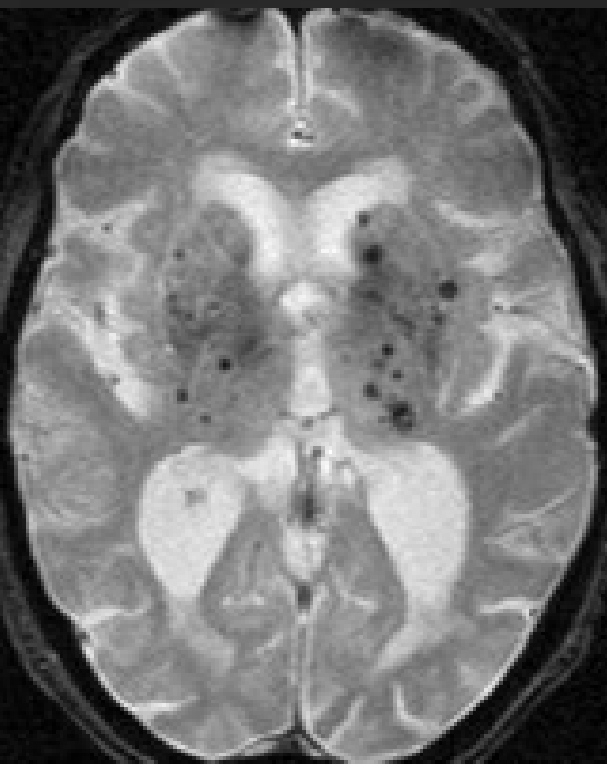
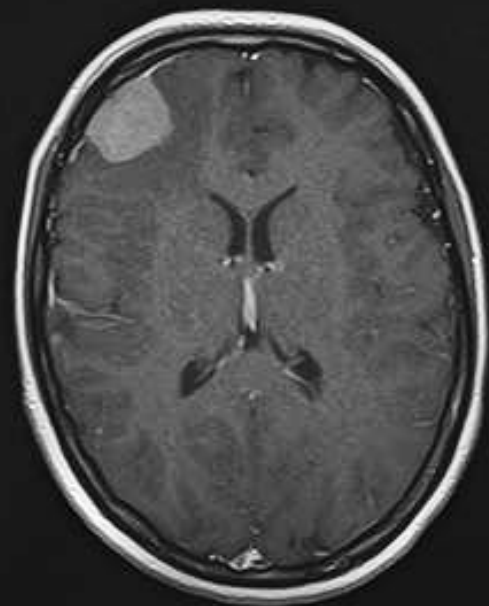
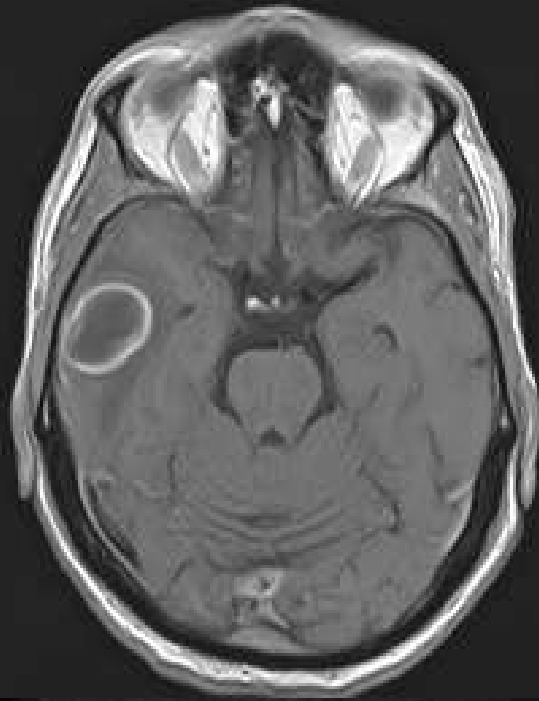
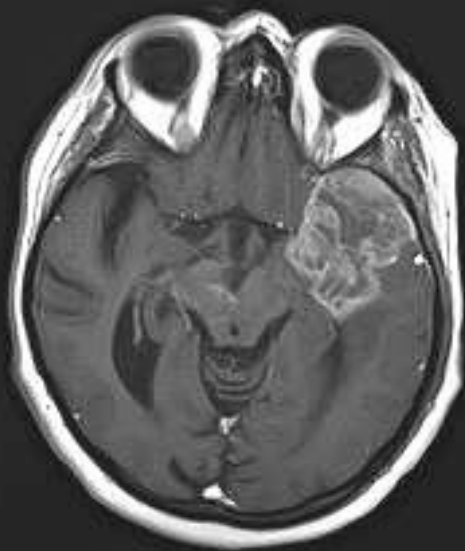

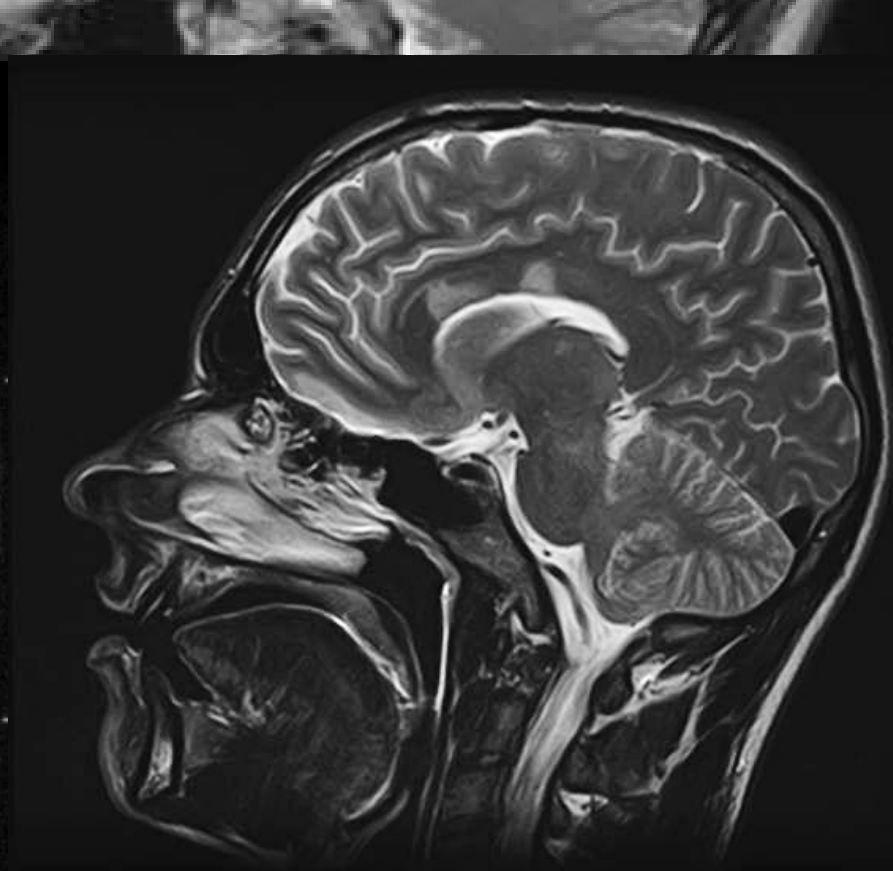
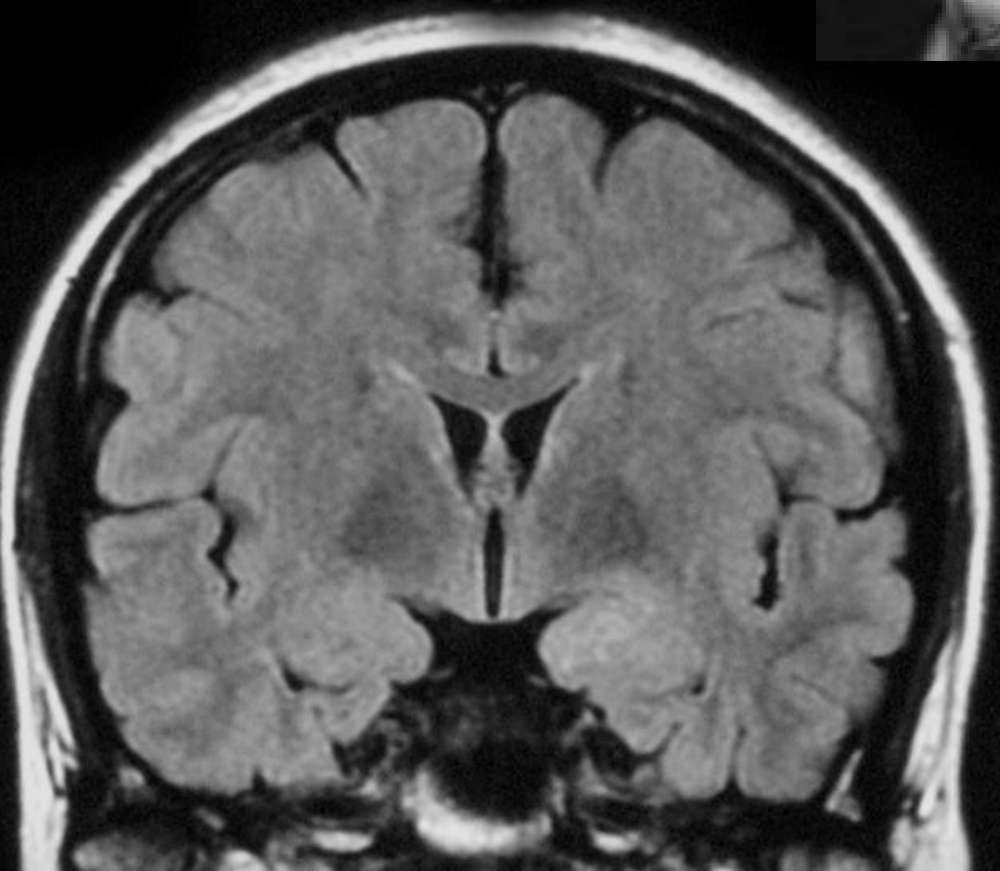
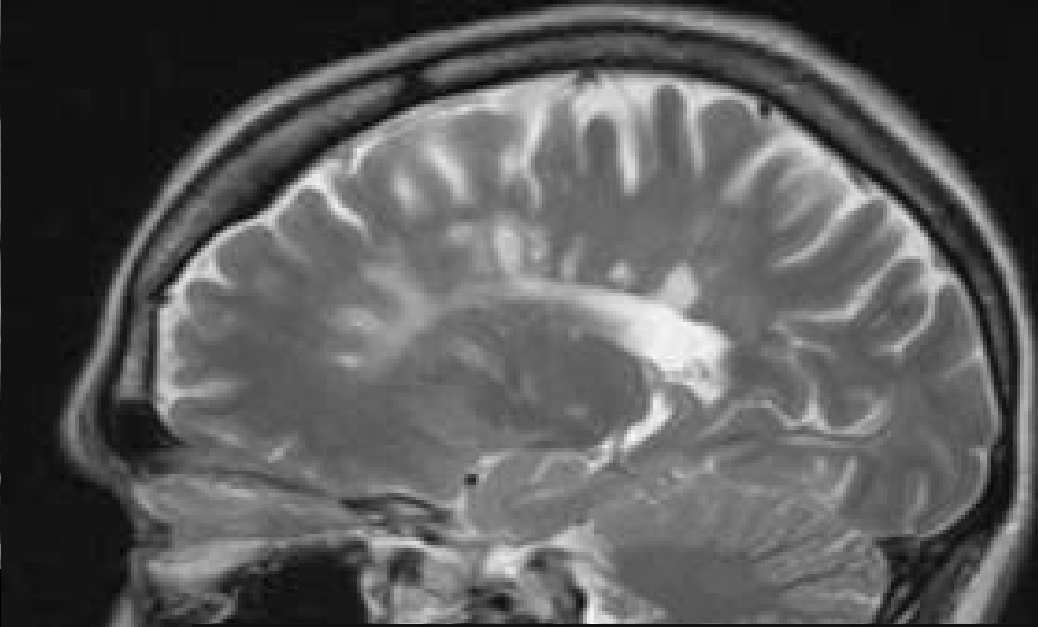
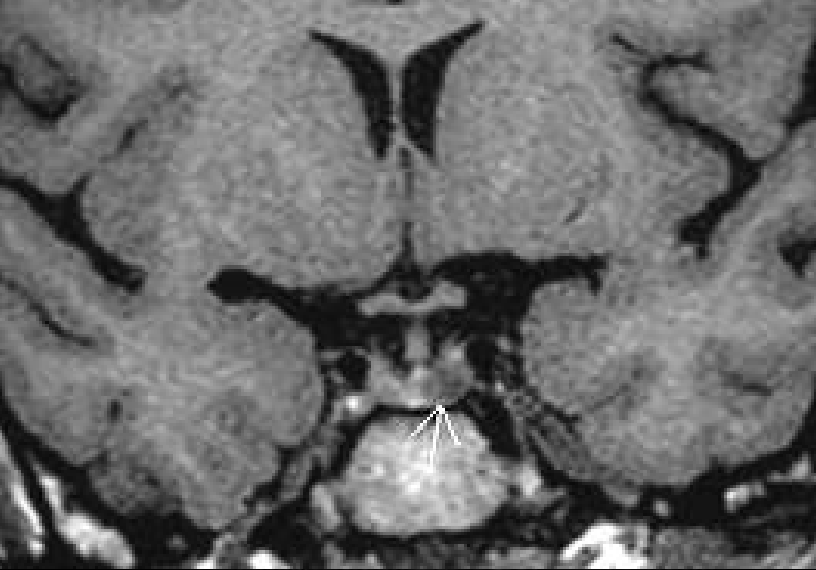


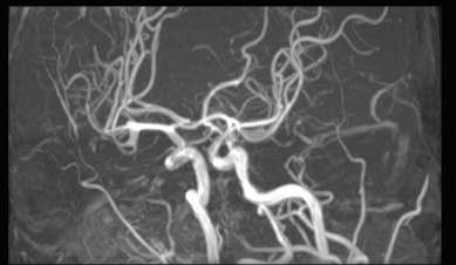
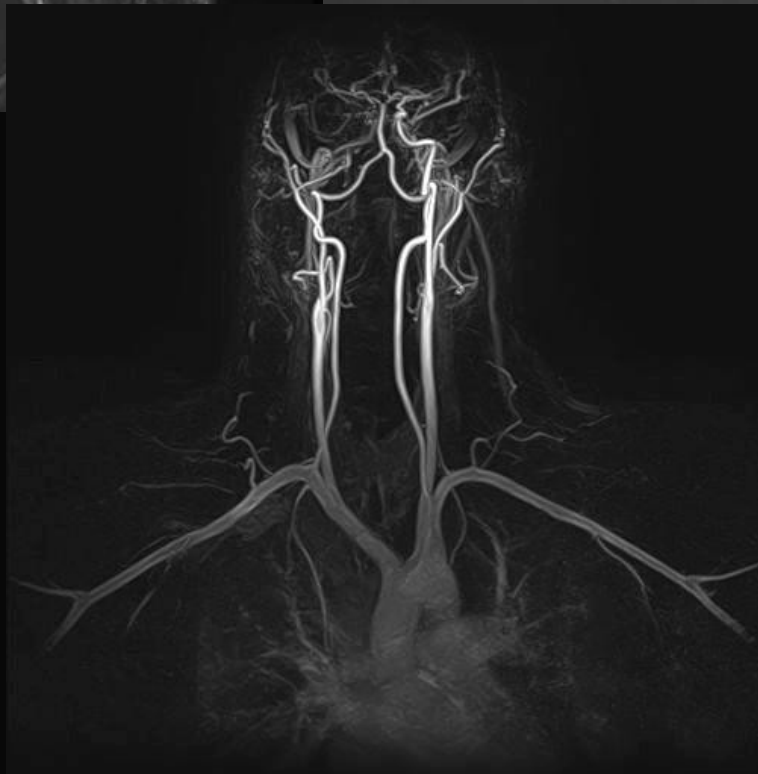
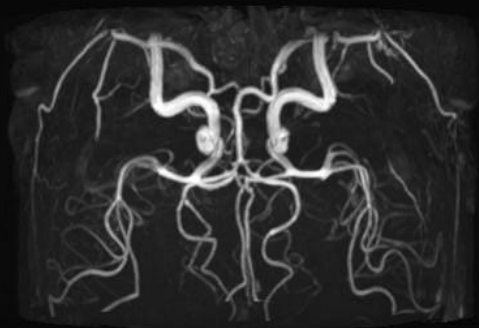
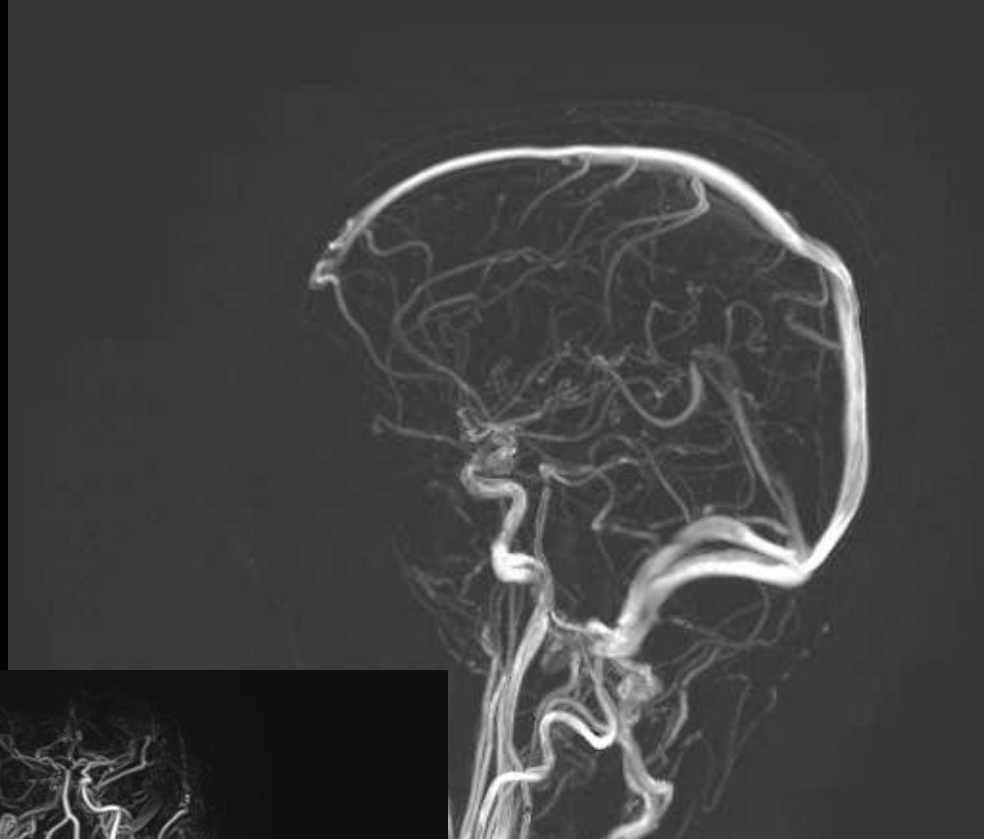
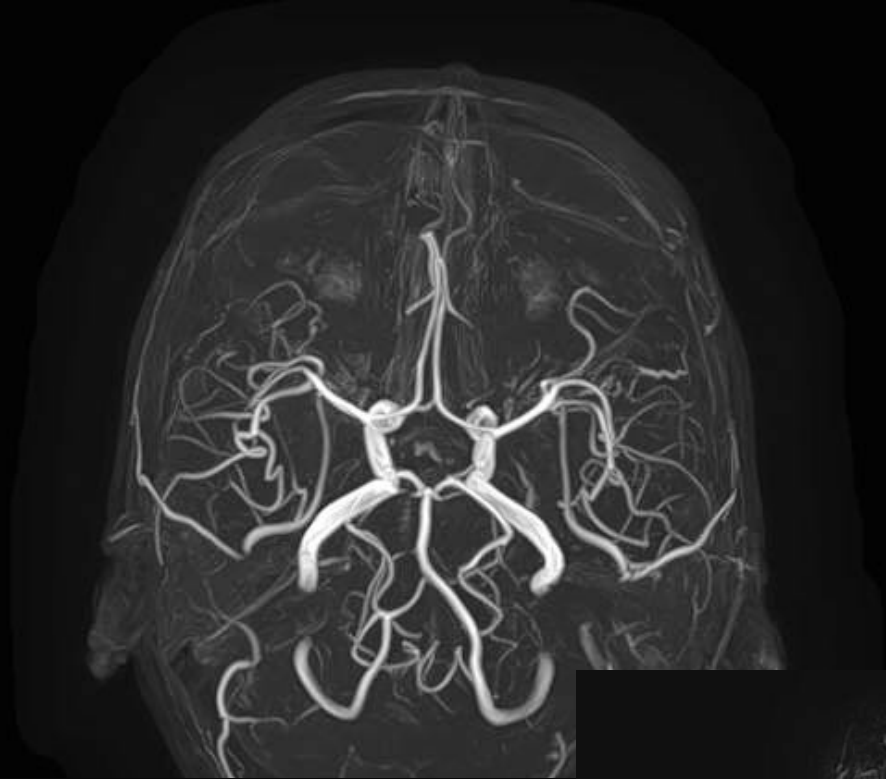MR

- **nádorová onemocnění**
- **zánětlivá onemocnění** - zvláště pak demyelinizační onemocnění bílé hmoty (roztoušená skleróza)
- **epilepsie**
- **cévní onemocnění** (malformace, aneuryzmata)
- **neurodegenerativní onemocnění**
- **vrozené vady**
- **hydrocephalus všech typů**
- **bolesti hlavy**
- **psychické změny**, včetně psychotických onemocnění
- **onemocnění hypofýzy a mozkových nervů**
- **následky úrazů hlavy**, zvláště se zaměřením na difusní axonální poranění a rozpadové produkty hemoglobinu
- MRI je možno provést u **akutních krvácení** a k posouzení fraktur lebky, vhodnější je ale provedení CT

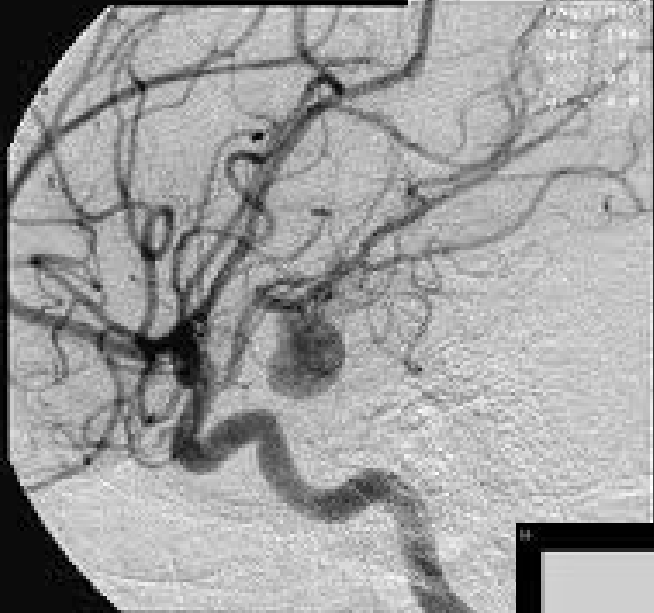



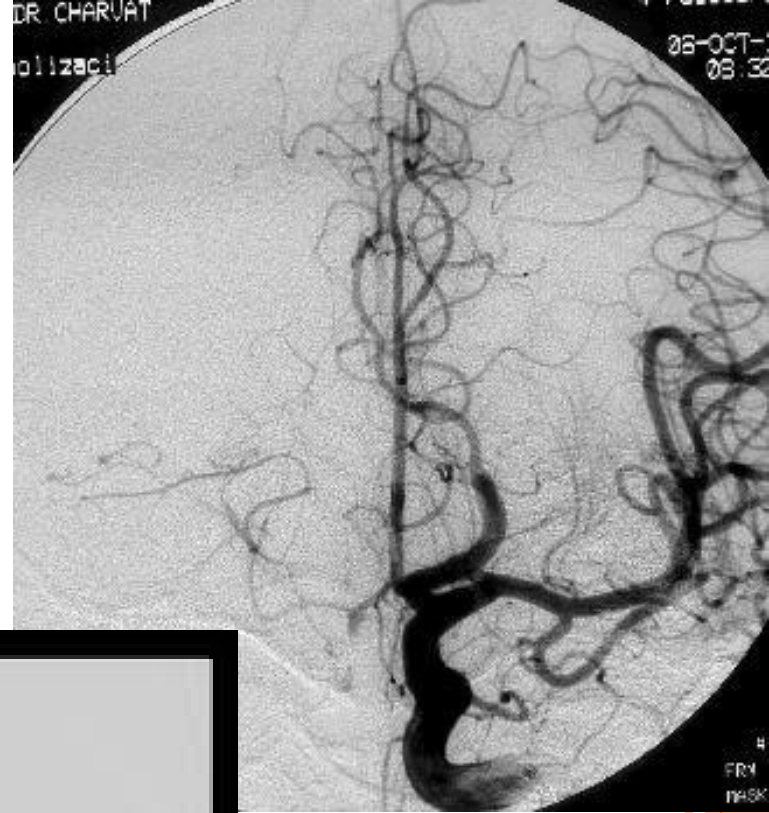




ENTR. CRAN. 80-78
21-JUL-88
10-44-35



AG

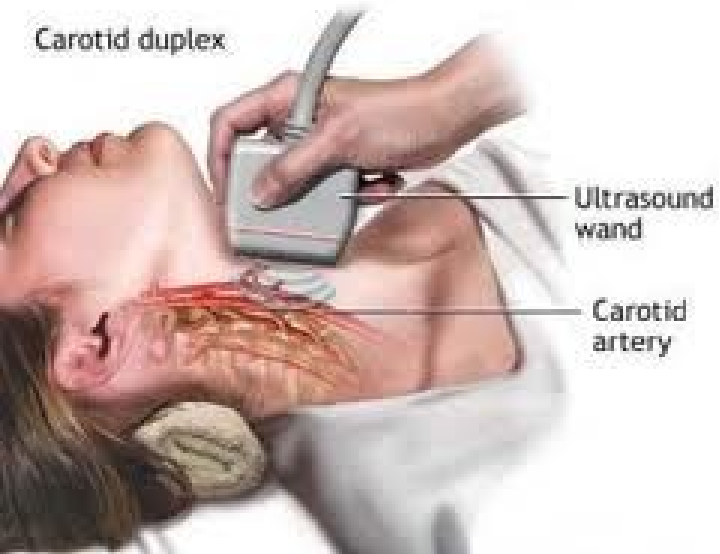


#CM LDC: WESTCINDE 204 1/2 CRANMAGE

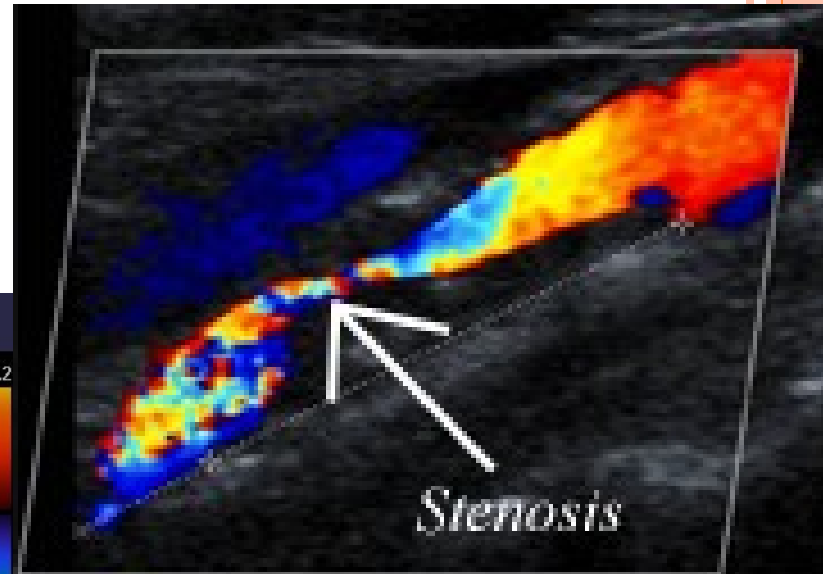
H
FRM
PASK



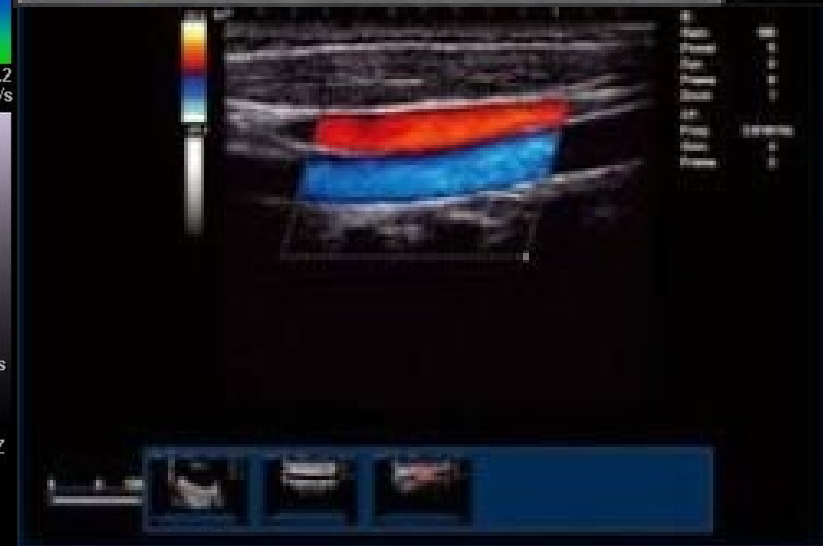
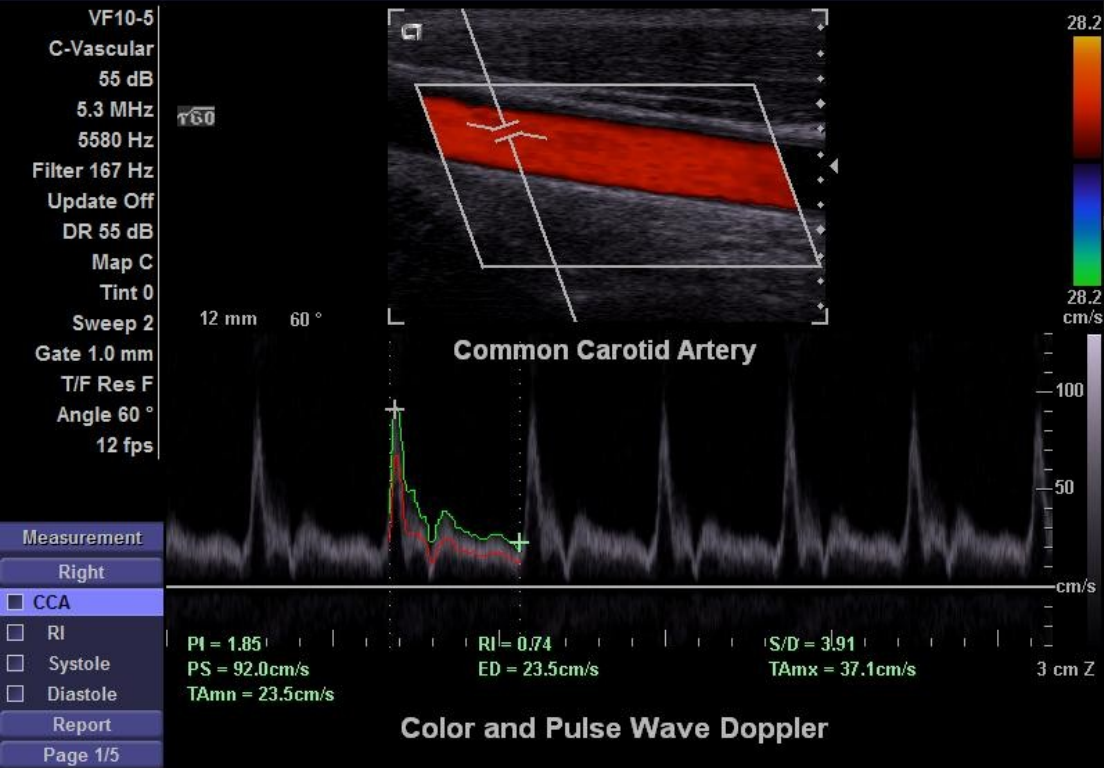
Carotid duplex



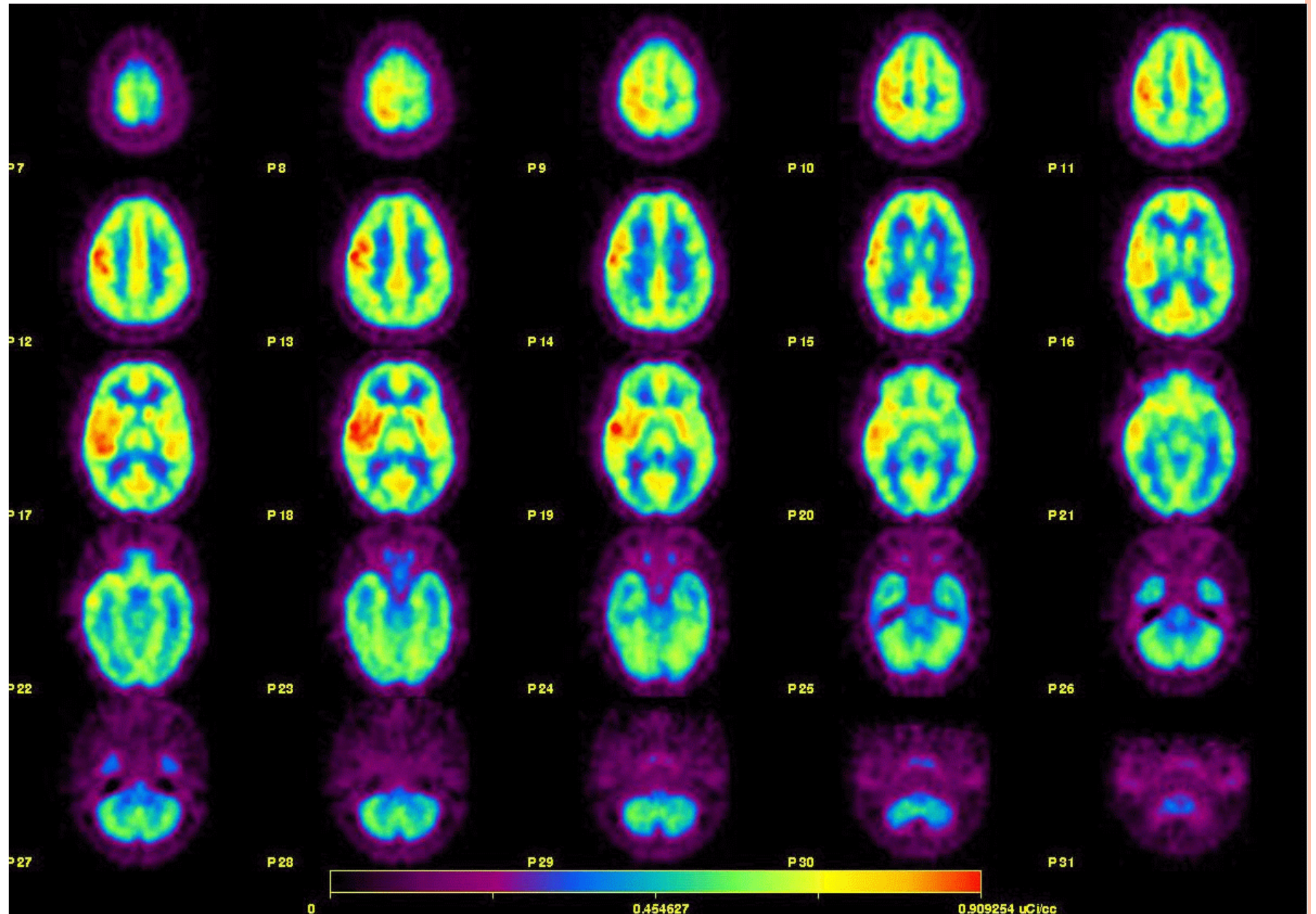
DOPPLER



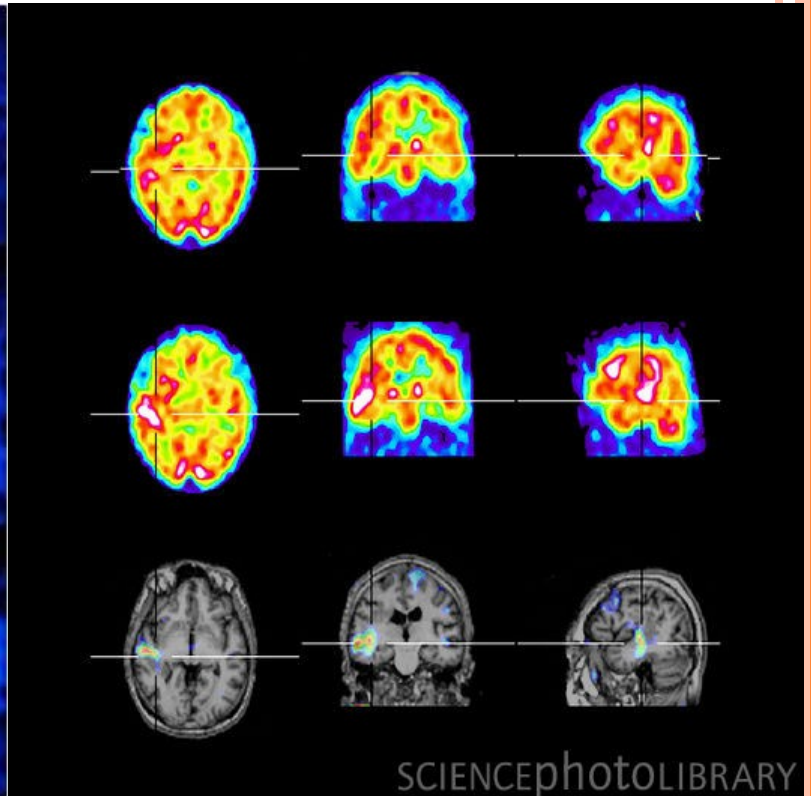
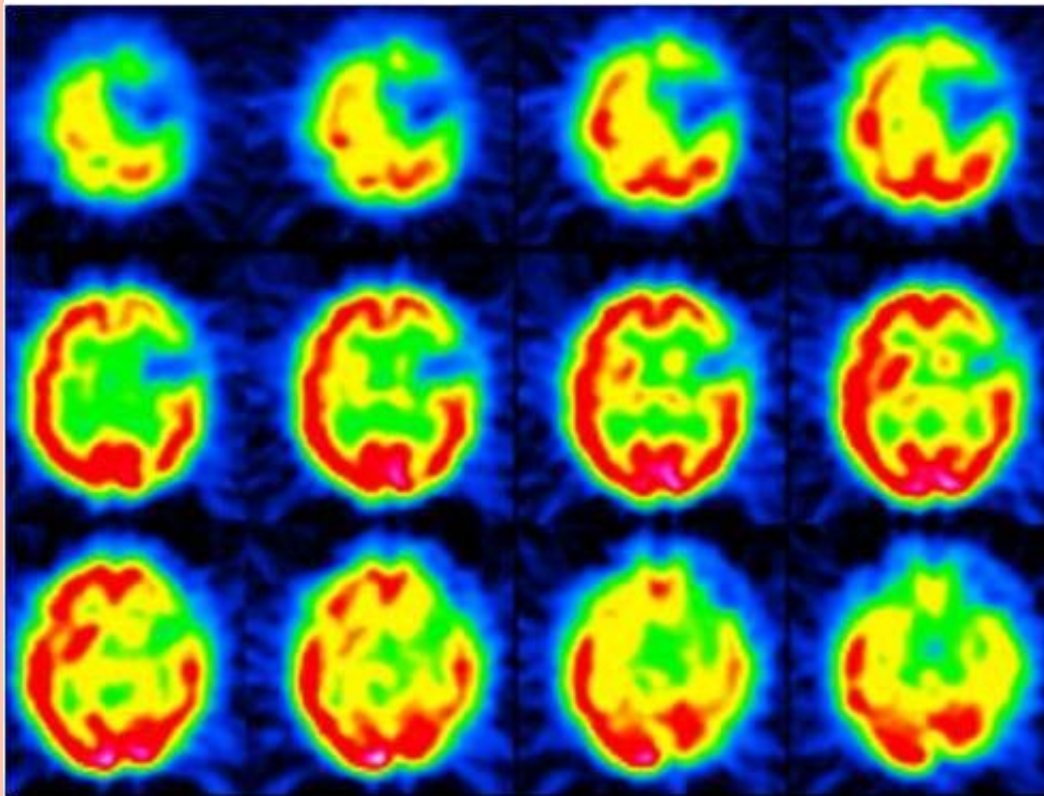
SIEMENS



PET



SPECT



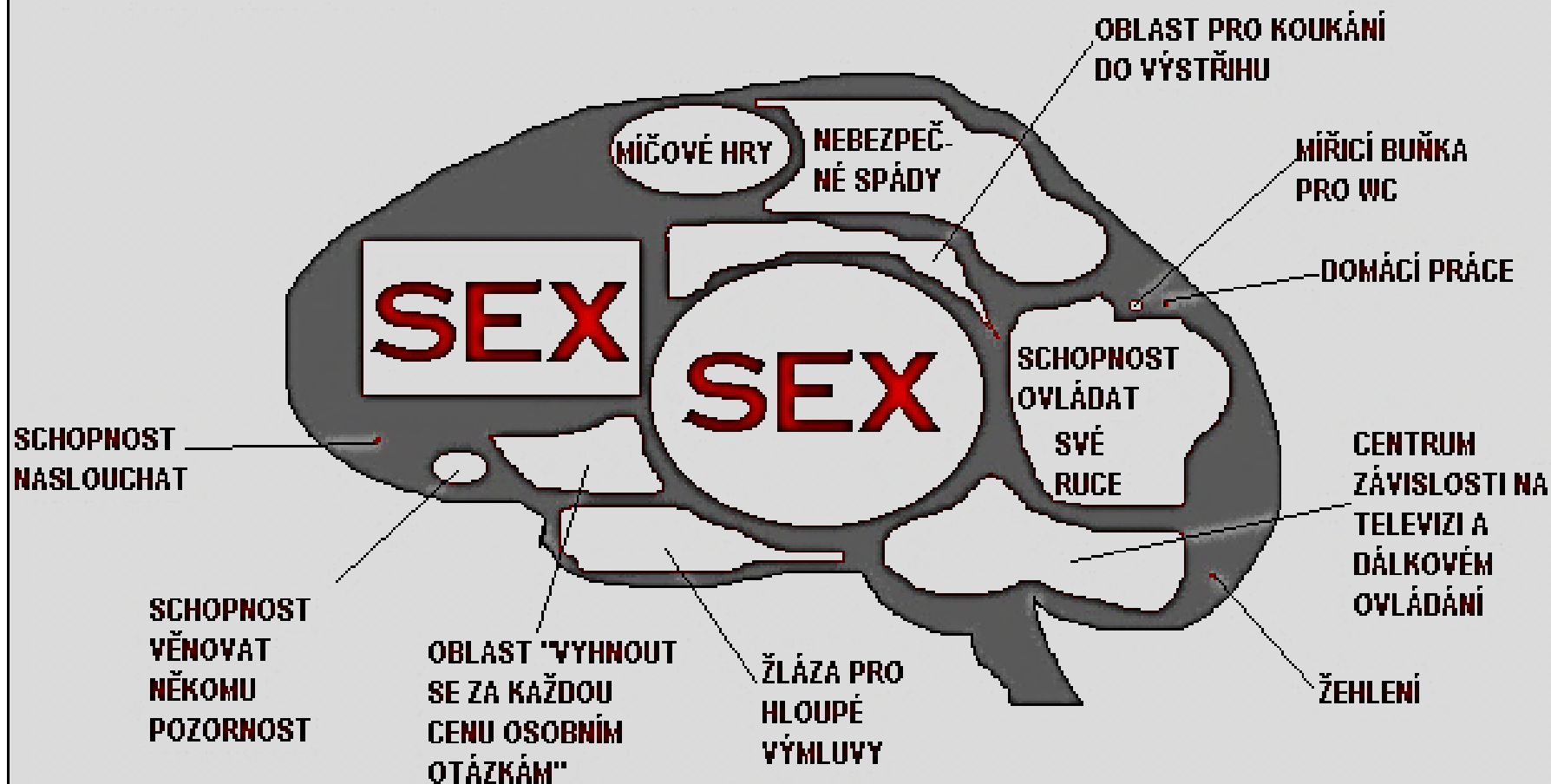
SCIENCEPHOTOLIBRARY



SMRT MOZKU - NM

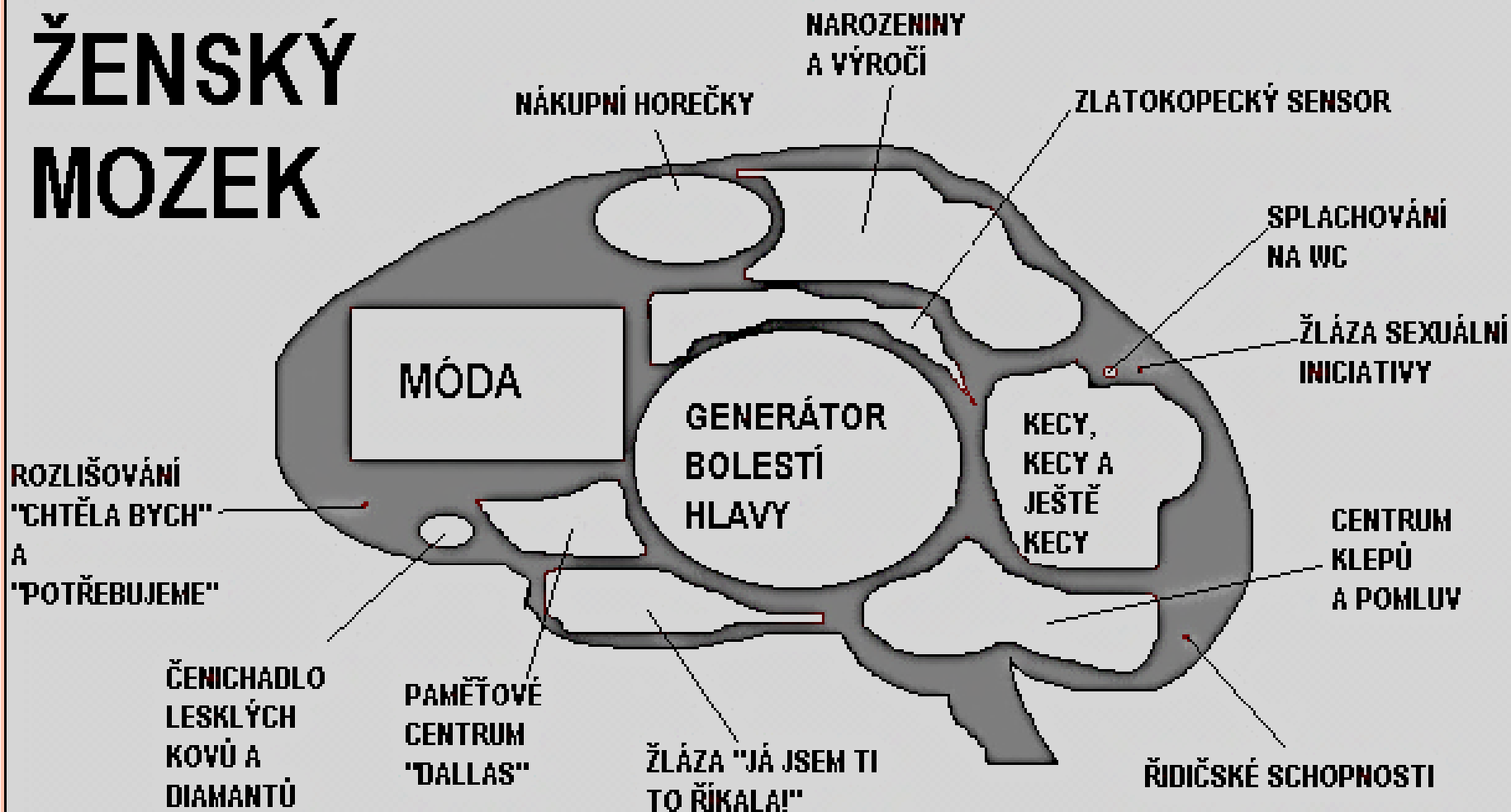
 Ph:1 Fr:1 4485cta 0sec Duration:2sec 64x64 Pic:9.6mm 99m Technetium	 Ph:1 Fr:2 8540cta 3sec Duration:2sec 64x64 Pic:9.6mm 99m Technetium	 Ph:1 Fr:3 8593cta 4sec Duration:2sec 64x64 Pic:9.6mm 99m Technetium	 Ph:1 Fr:4 10K 6sec Duration:2sec 64x64 Pic:9.6mm 99m Technetium	 Ph:1 Fr:5 11K 8sec Duration:2sec 64x64 Pic:9.6mm 99m Technetium	 Ph:1 Fr:6 12K 10sec Duration:2sec 64x64 Pic:9.6mm 99m Technetium	 Ph:1 Fr:7 13K 12sec Duration:2sec 64x64 Pic:9.6mm 99m Technetium	 Ph:1 Fr:8 13K 14sec Duration:2sec 64x64 Pic:9.6mm 99m Technetium
 Ph:1 Fr:9 13K 16sec Duration:2sec 64x64 Pic:9.6mm 99m Technetium	 Ph:1 Fr:10 13K 18sec Duration:2sec 64x64 Pic:9.6mm 99m Technetium	 Ph:1 Fr:11 13K 20sec Duration:2sec 64x64 Pic:9.6mm 99m Technetium	 Ph:1 Fr:12 13K 22sec Duration:2sec 64x64 Pic:9.6mm 99m Technetium	 Ph:1 Fr:13 13K 24sec Duration:2sec 64x64 Pic:9.6mm 99m Technetium	 Ph:1 Fr:14 13K 26sec Duration:2sec 64x64 Pic:9.6mm 99m Technetium	 Ph:1 Fr:15 12K 28sec Duration:2sec 64x64 Pic:9.6mm 99m Technetium	 Ph:1 Fr:16 12K 30sec Duration:2sec 64x64 Pic:9.6mm 99m Technetium
 Ph:1 Fr:17 12K 32sec Duration:2sec 64x64 Pic:9.6mm 99m Technetium	 Ph:1 Fr:18 12K 34sec Duration:2sec 64x64 Pic:9.6mm 99m Technetium	 Ph:1 Fr:19 12K 36sec Duration:2sec 64x64 Pic:9.6mm 99m Technetium	 Ph:1 Fr:20 12K 38sec Duration:2sec 64x64 Pic:9.6mm 99m Technetium	 Ph:1 Fr:21 13K 40sec Duration:2sec 64x64 Pic:9.6mm 99m Technetium	 Ph:1 Fr:22 13K 42sec Duration:2sec 64x64 Pic:9.6mm 99m Technetium	 Ph:1 Fr:23 13K 44sec Duration:2sec 64x64 Pic:9.6mm 99m Technetium	 Ph:1 Fr:24 11K 46sec Duration:2sec 64x64 Pic:9.6mm 99m Technetium
 Ph:1 Fr:25 11K 48sec Duration:2sec 64x64 Pic:9.6mm 99m Technetium	 Ph:1 Fr:26 11K 50sec Duration:2sec 64x64 Pic:9.6mm 99m Technetium	 Ph:1 Fr:27 12K 52sec Duration:2sec 64x64 Pic:9.6mm 99m Technetium	 Ph:1 Fr:28 12K 54sec Duration:2sec 64x64 Pic:9.6mm 99m Technetium	 Ph:1 Fr:29 11K 56sec Duration:2sec 64x64 Pic:9.6mm 99m Technetium	 Ph:1 Fr:30 11K 58sec Duration:2sec 64x64 Pic:9.6mm 99m Technetium		

MUŽSKÝ MOZEK



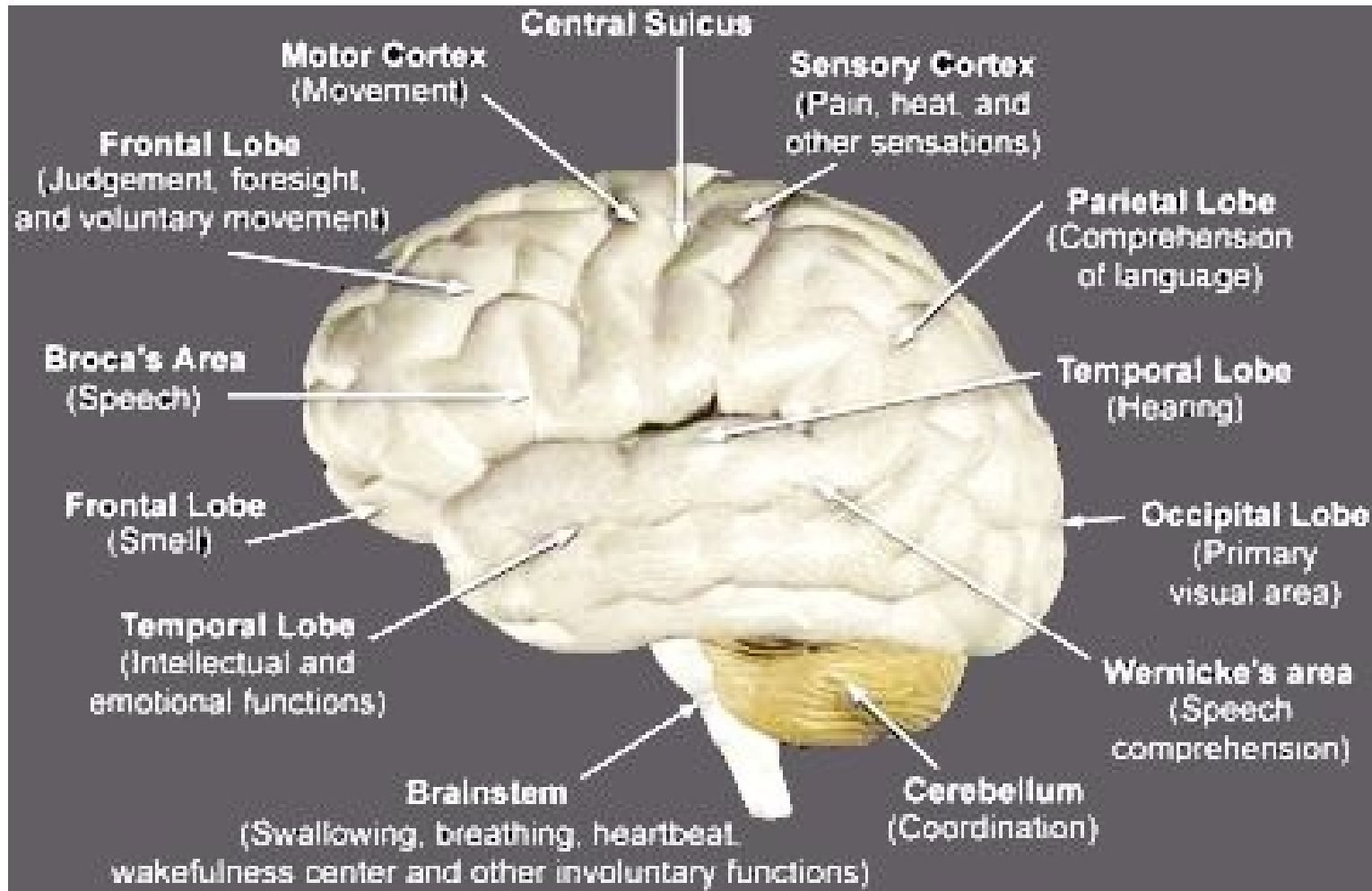
Poznámka: Žláza "poslouchání, jestli mimino v noci nepláče" není zobrazena, protože je zcela zakmělá a je viditelná pouze pod mikroskopem

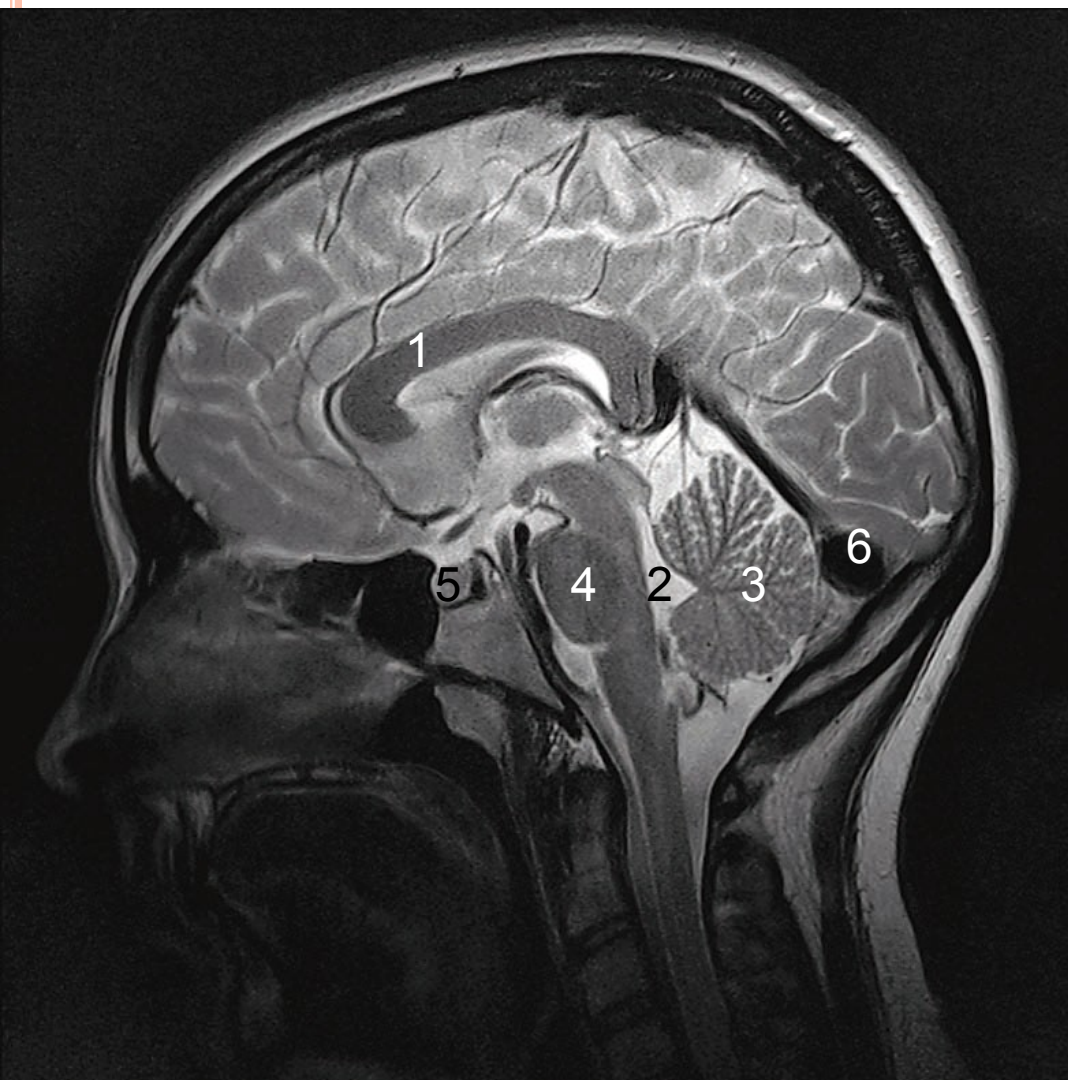
ŽENSKÝ MOZEK



Poznámka: Žlázy "vyměnit olej v autě" a "mlčet, dokud neskončil poločas" jsou aktivní pouze, je-li zaměstnáno čenichadlo lesklých kovů a diamantů, nebo probíhá-li poblíž výprodej textilu.

MOZKOVÁ CENTRA





- 1 – corpus callosum
- 2 – 4.komora
- 3 – mozeček
- 4 – Varolův most
- 5 – hypofýza
- 6 – soutok splavů



PÁTEŘ A PÁTEŘNÍ KANÁL

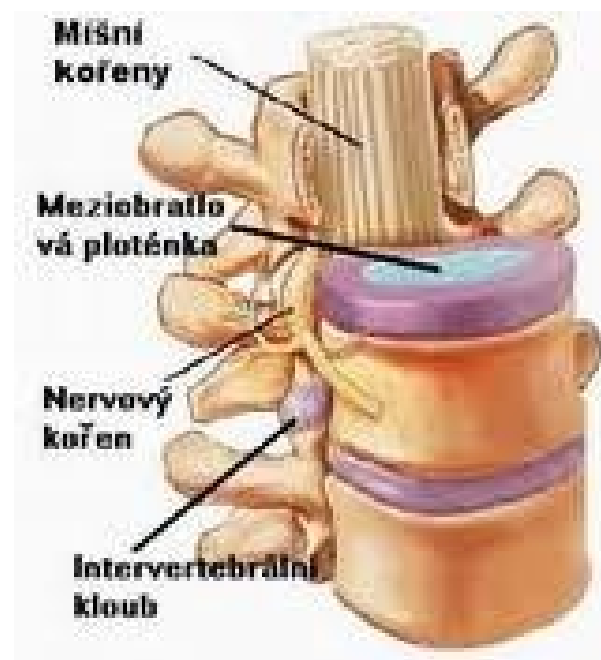
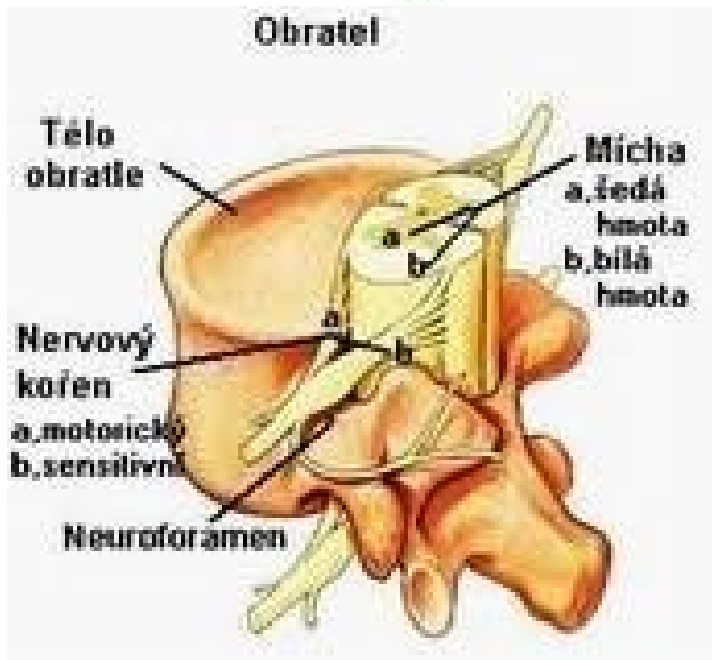
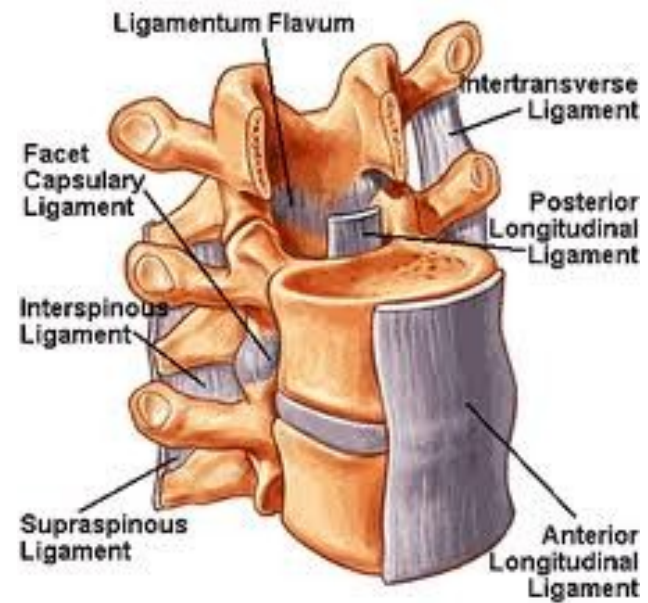
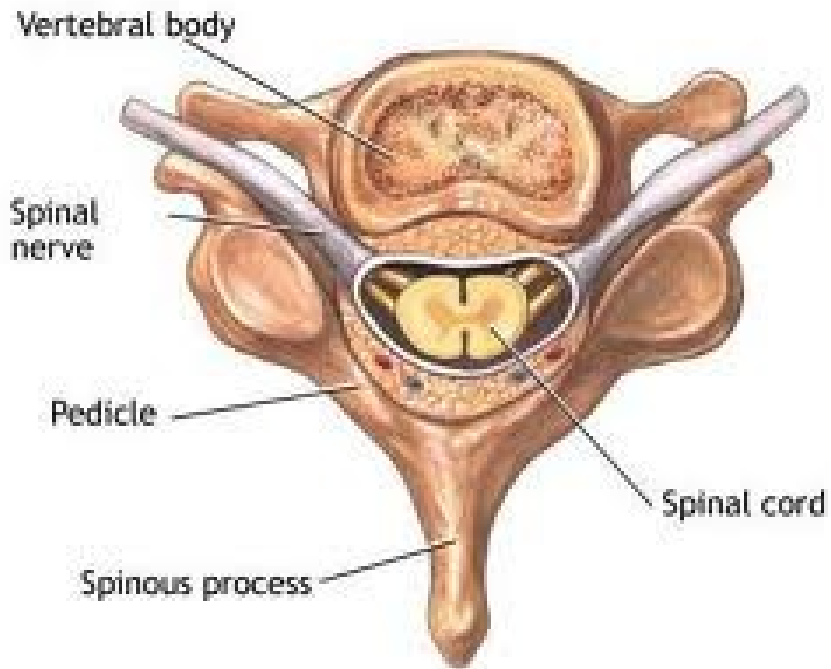
- RTG - AP a bočná projekce, u skoliózy vestoje
 - šikmé snímky
 - dynamické snímky
- CT
- MR
- PMG
- NM



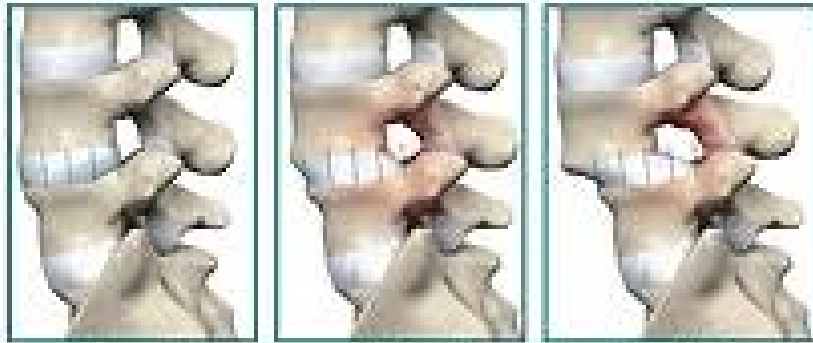RTG

- Postavení páteře (kyfóza, lordóza, skolióza)
- Obratlová těla
- Intervertebrální prostor
- Kloubní plošky obratlů
- Příčné a trnové výběžky
- Šířka páteřního kanálu
- Pooperační kontrola





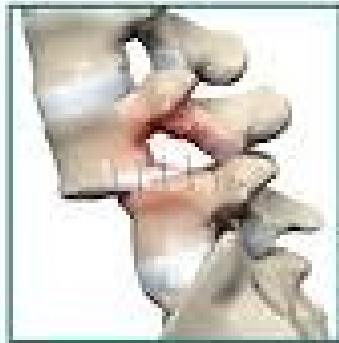Grades of spondylolisthesis



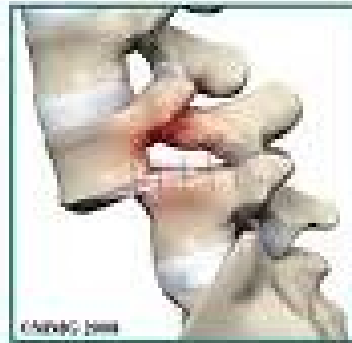Normal spine

Grade 1
<25% slippage

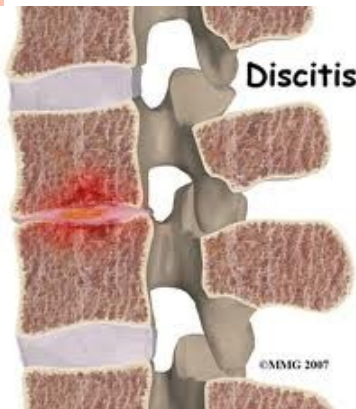
Grade 2
25-50% slippage



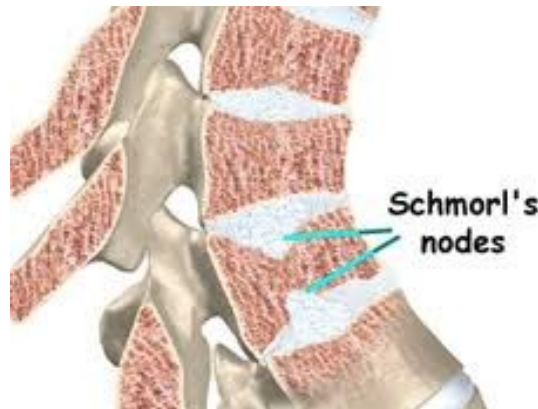Grade 3
50-75% slippage



Grade 4
>75% slippage

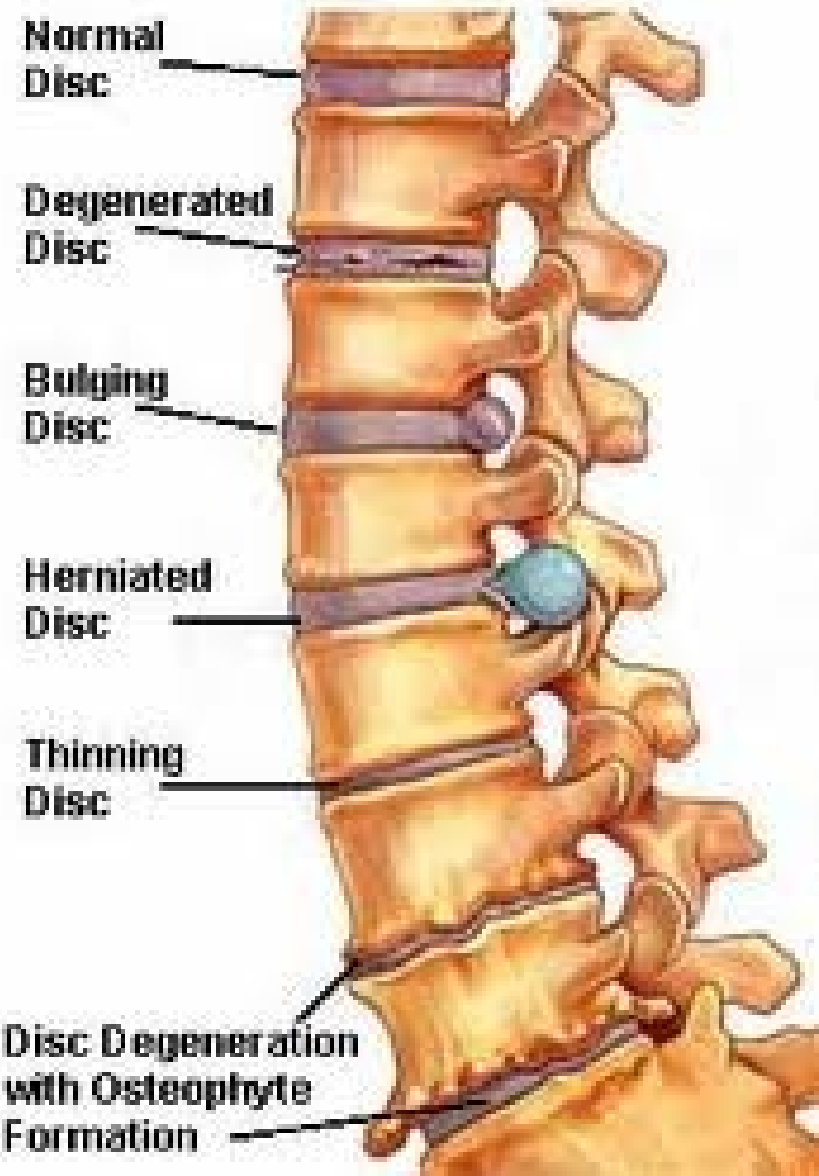


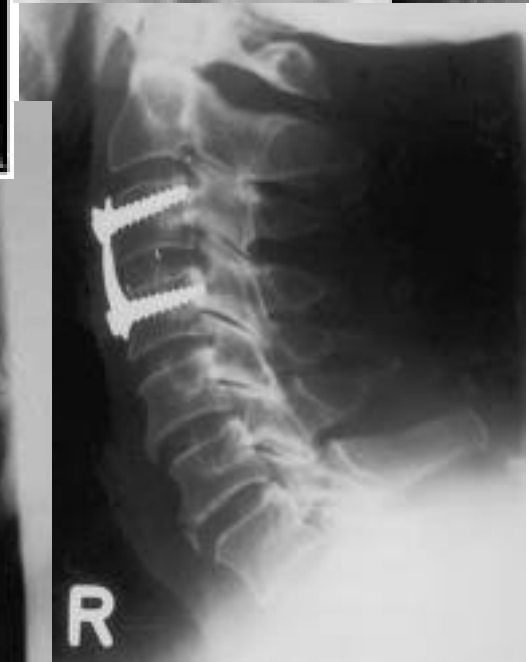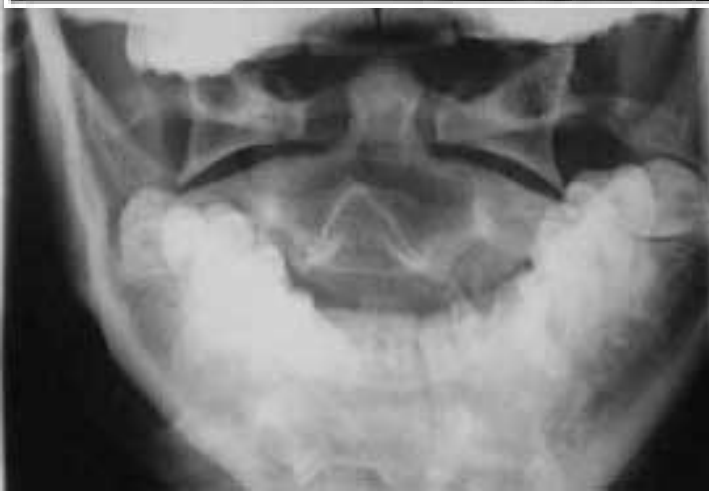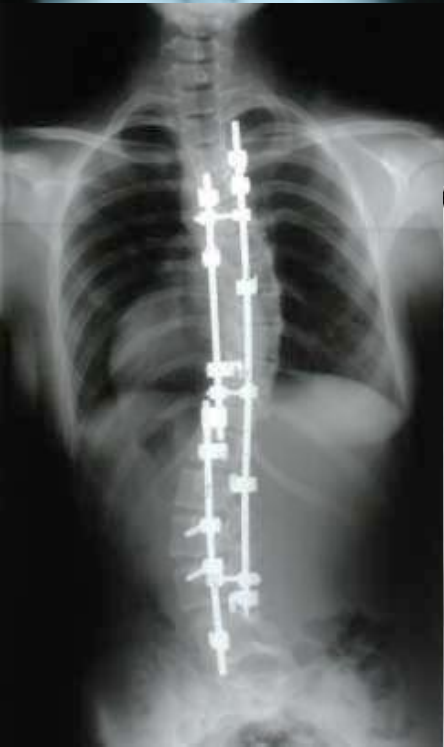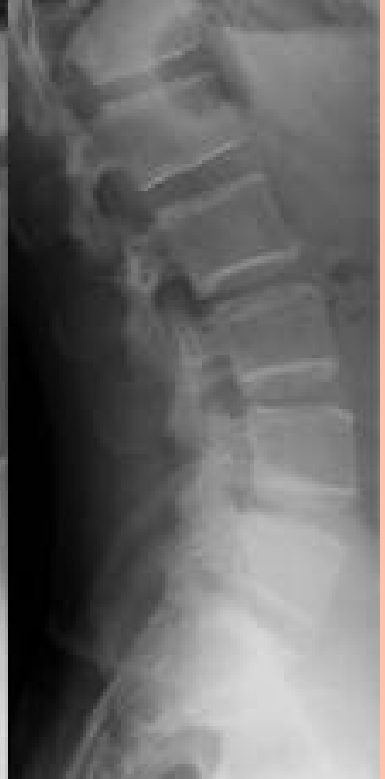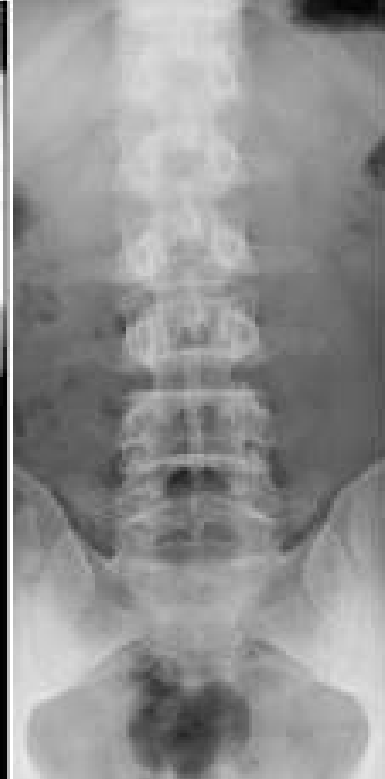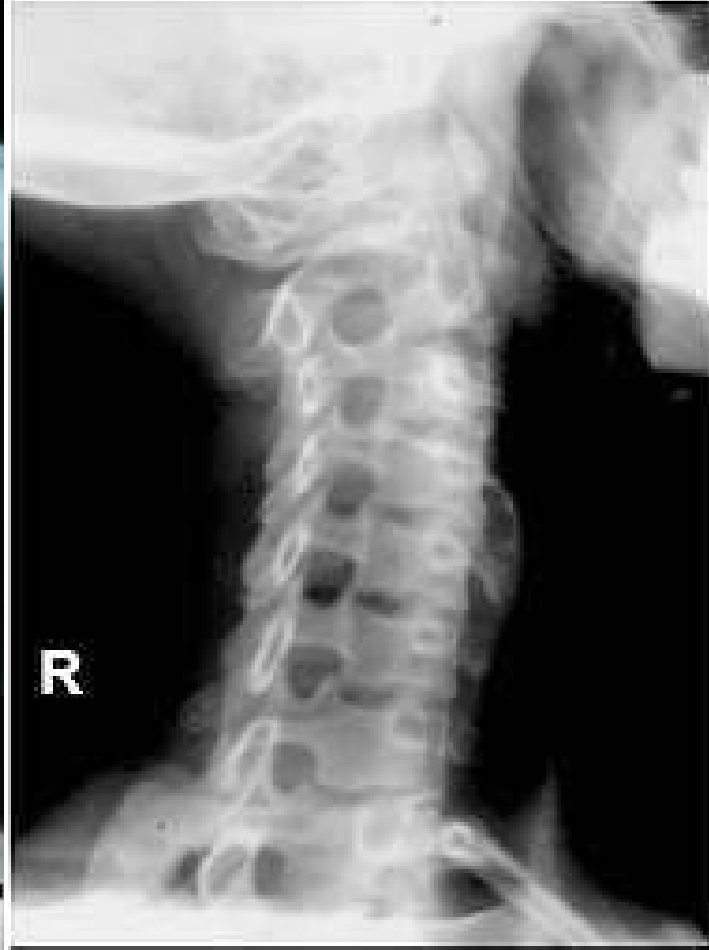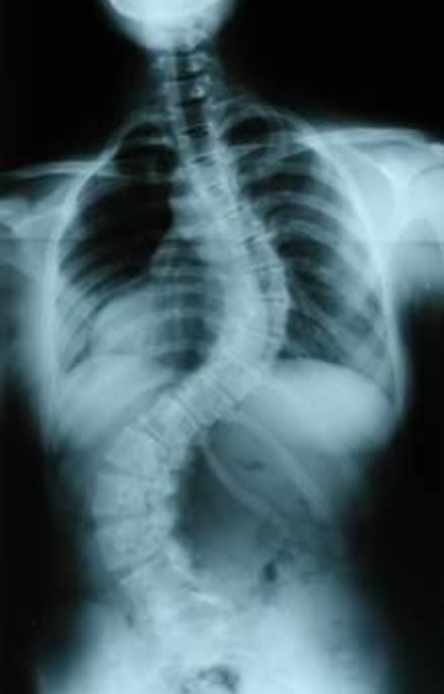Discitis



Schmorl's nodes

Examples of Disc Problems

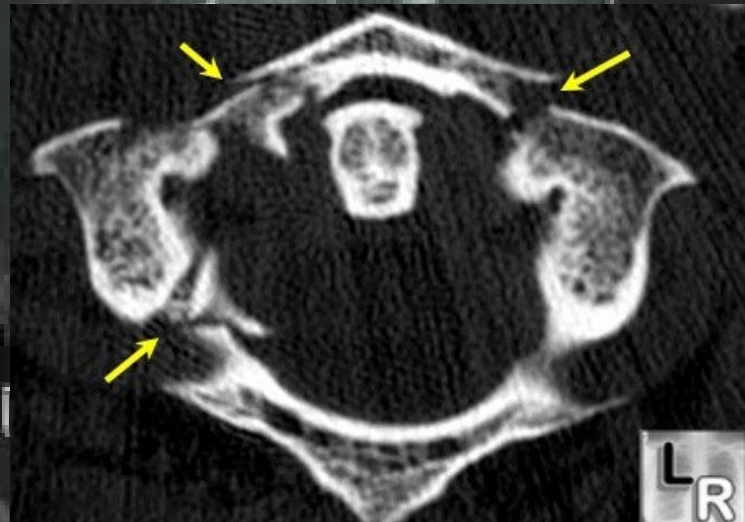
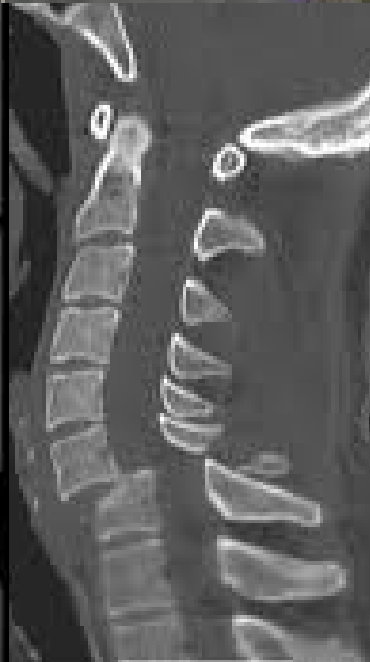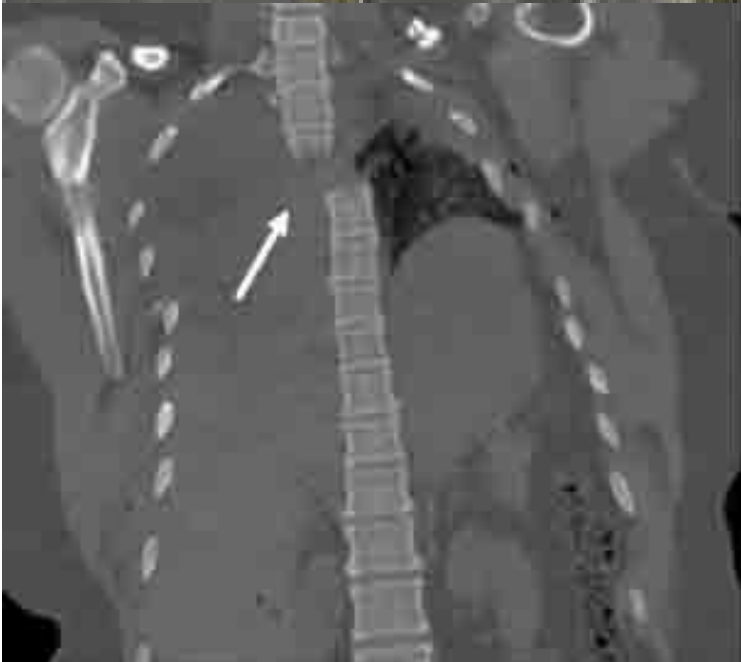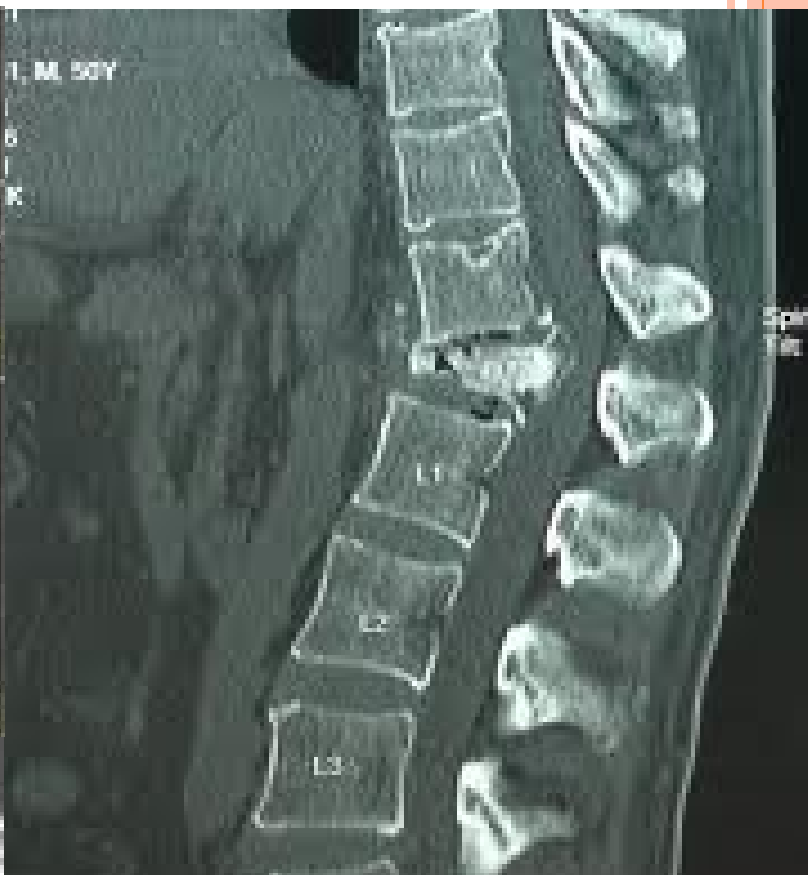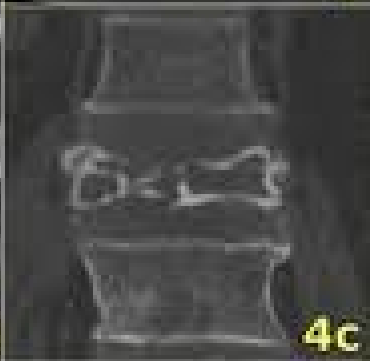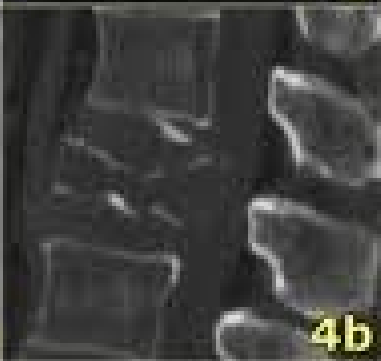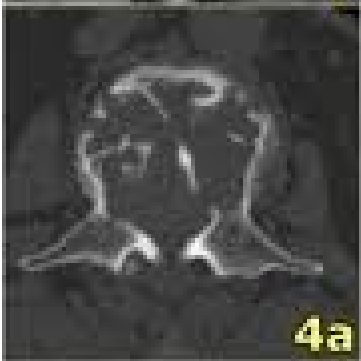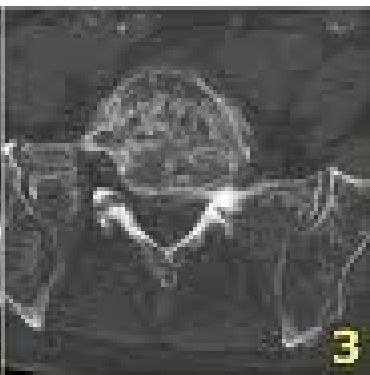
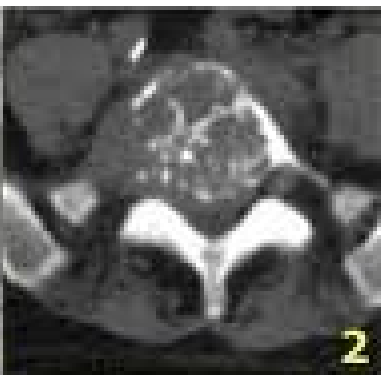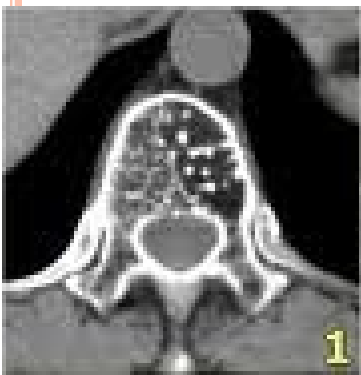




CT

- Onemocnění skeletu páteře a epidurálního prostoru (výhřezy meziobratlových plotének)
- Většinou vyšetřujeme 2-3 segmenty
- Traumatologie
- Tumory, metastázy
- CT - PMG

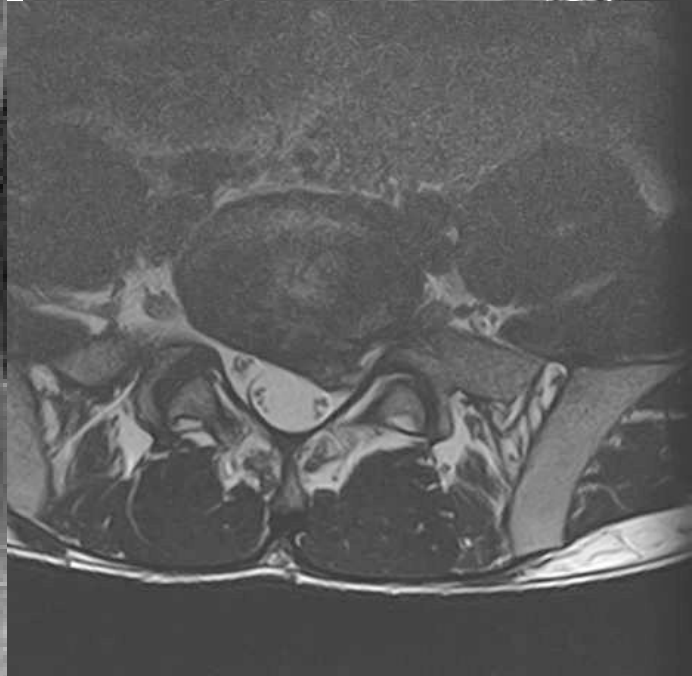
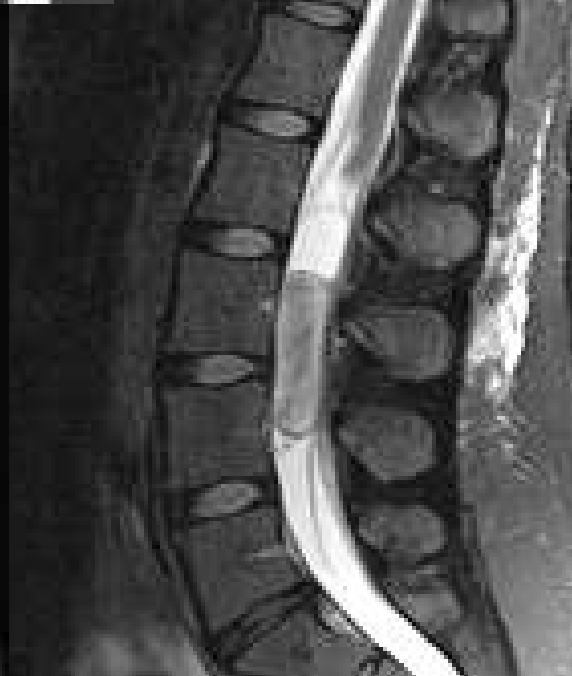
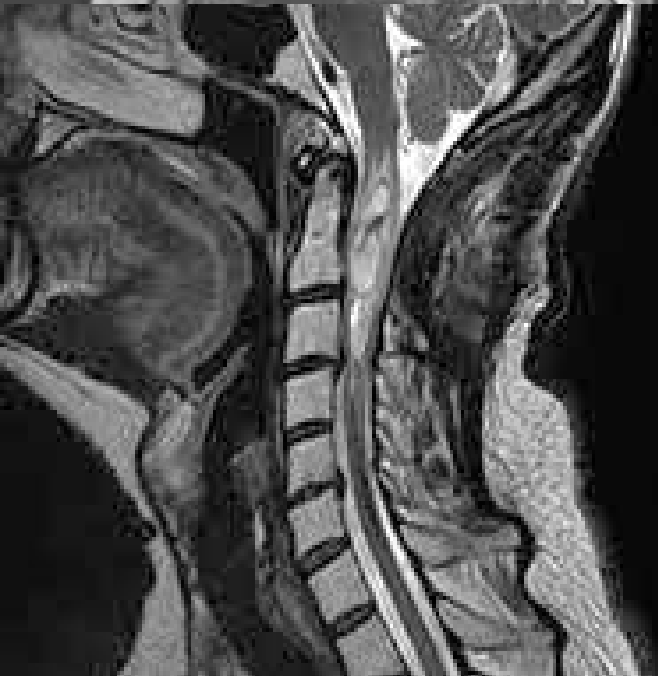
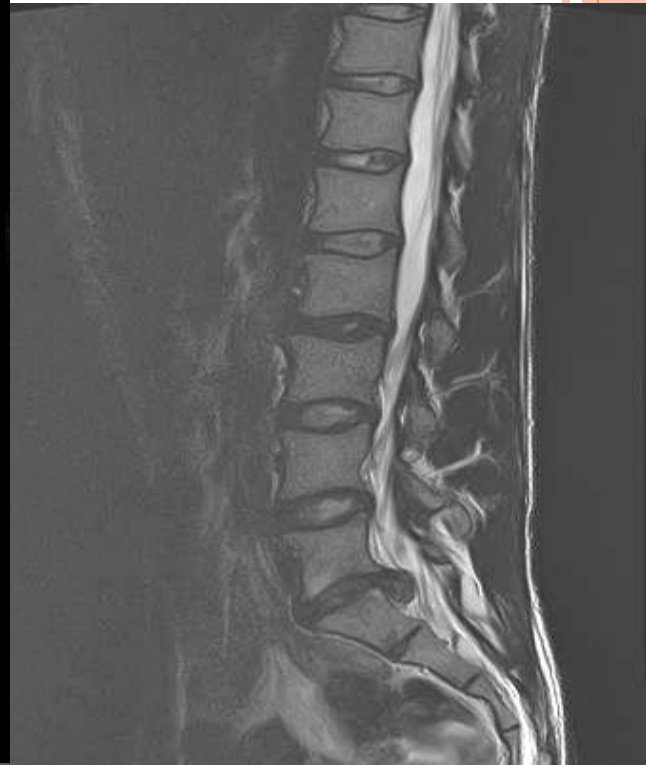
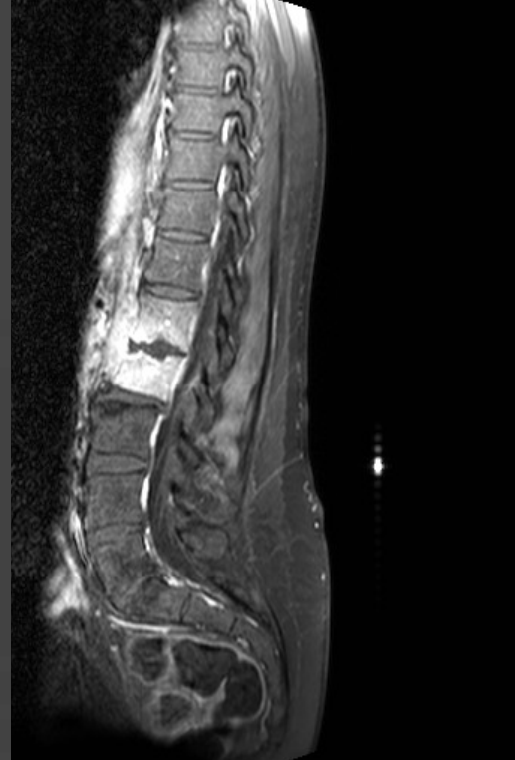
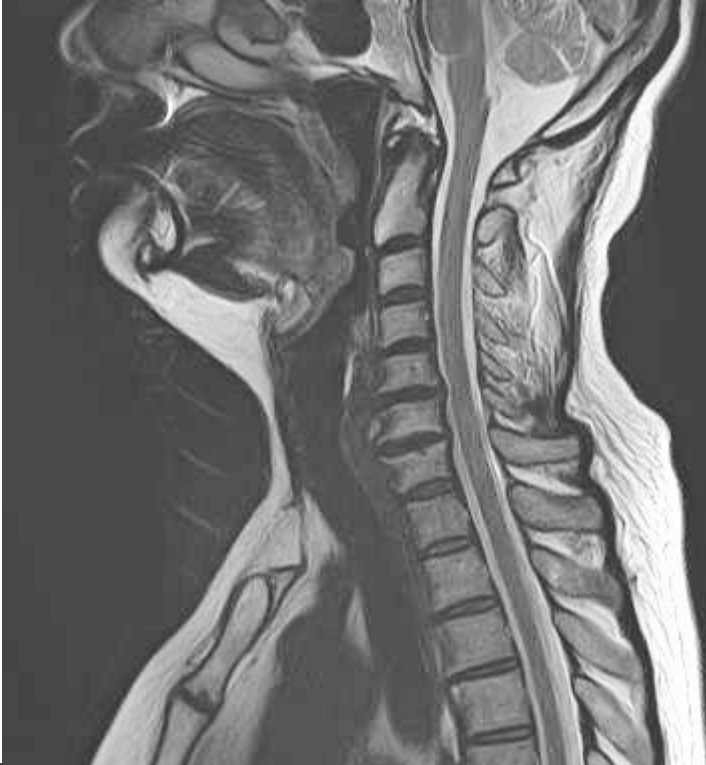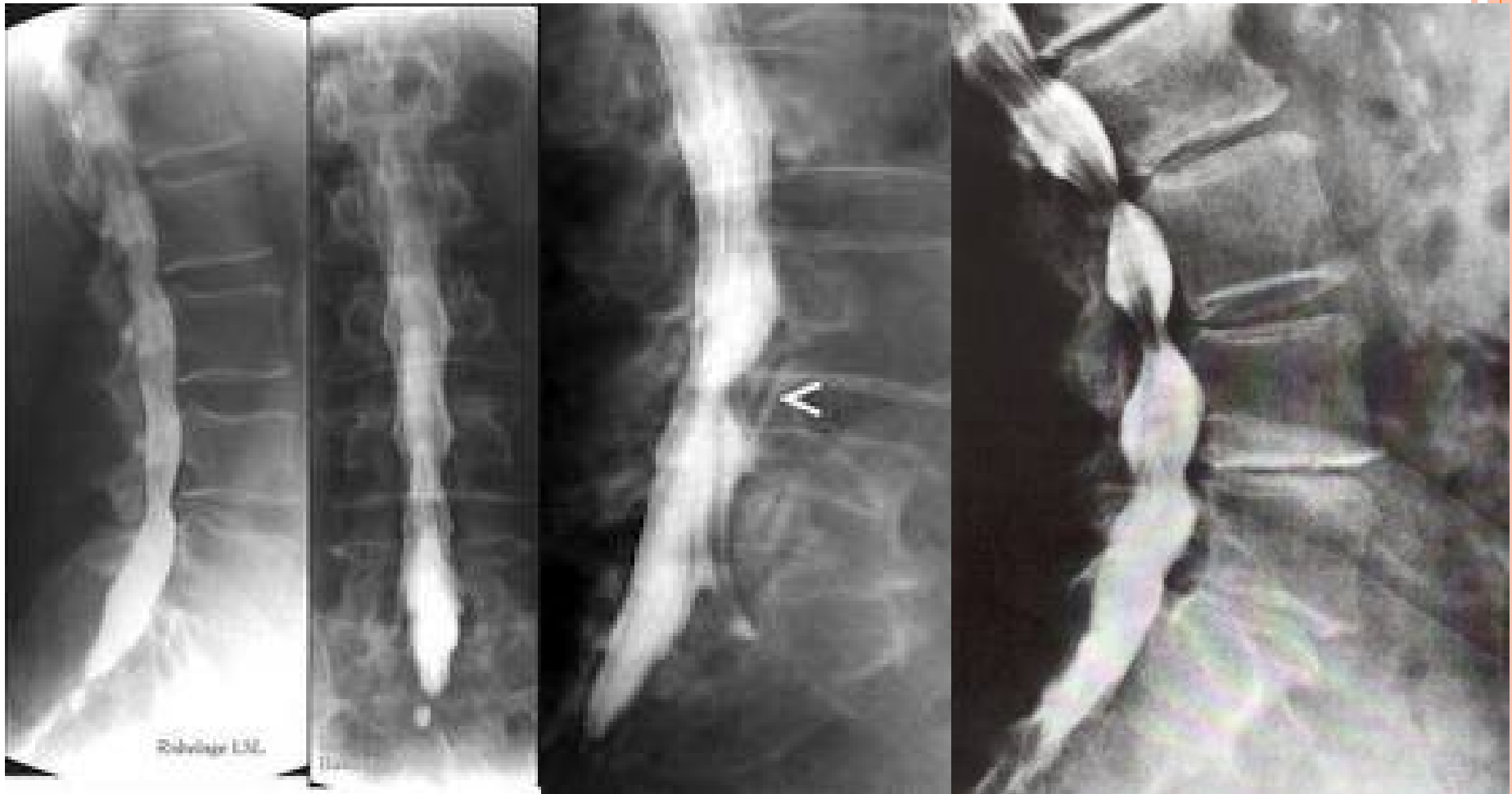
MR

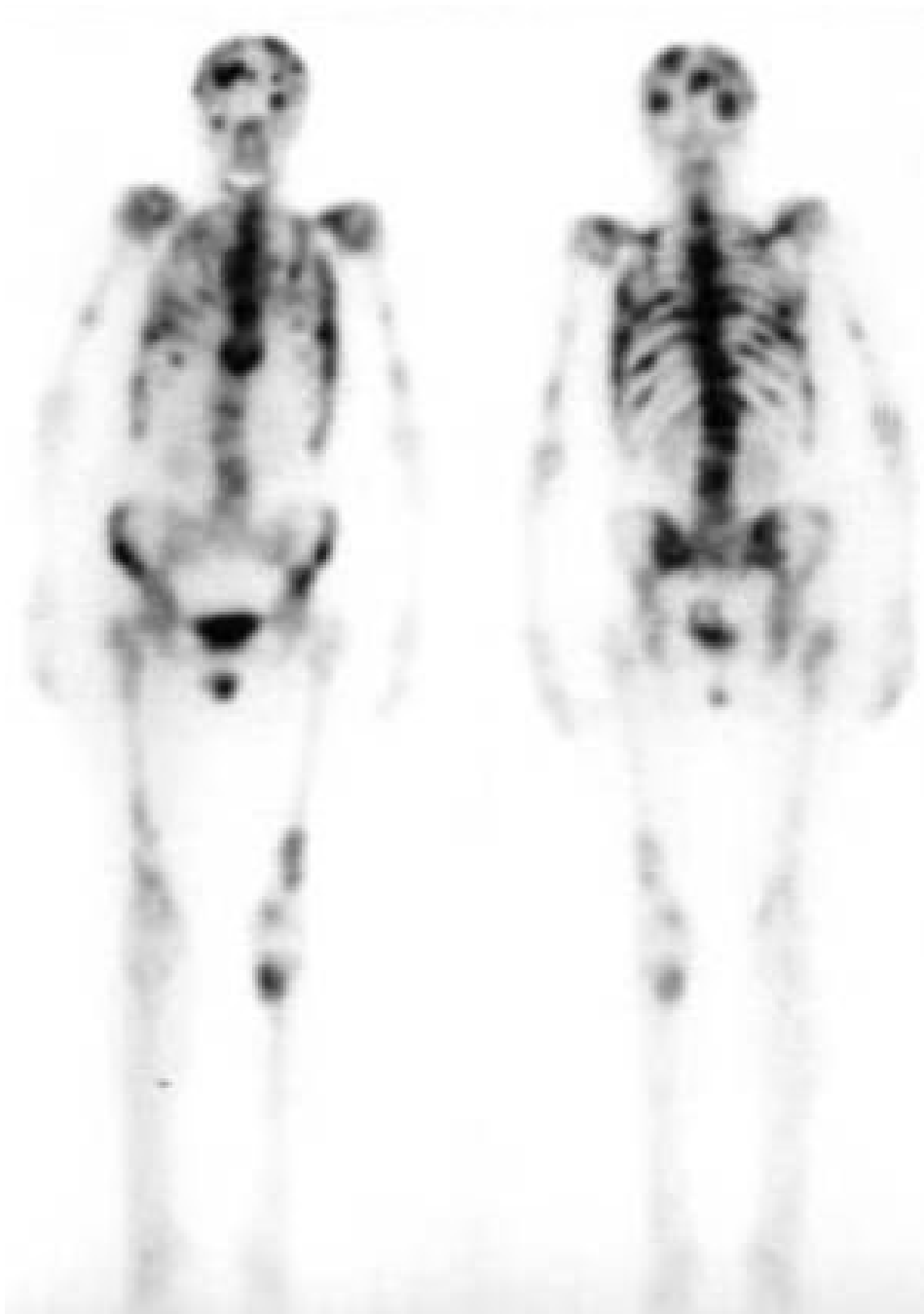
- Zobrazení míchy a struktur v páteřním kanále v celém rozsahu – výhřezy, protruze, ložiska RS, myelitida, spondylodiscitida, tumory a metastázy v obratlích a páteřním kanále
- Většinou nativní vyšetření, KL po operaci meziobratlových plotének, nádorů a ložiscích v míše





PMG

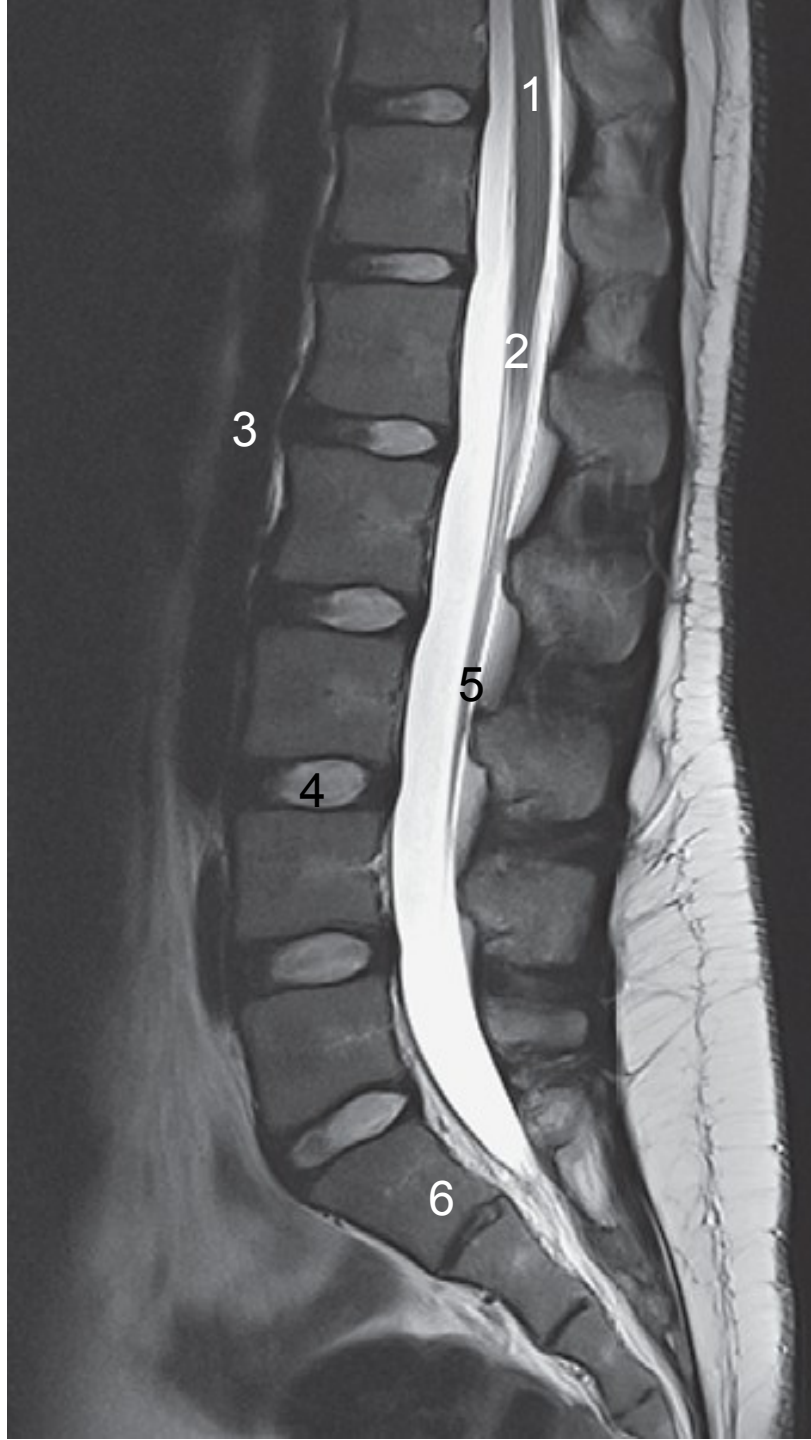




NM

- Časná detekce metastáz a zánětů páteře





- 1 – mícha
- 2 – míšní konus
- 3 – aorta
- 4 – disk
- 5 – cauda equina
- 6 - sacrum

