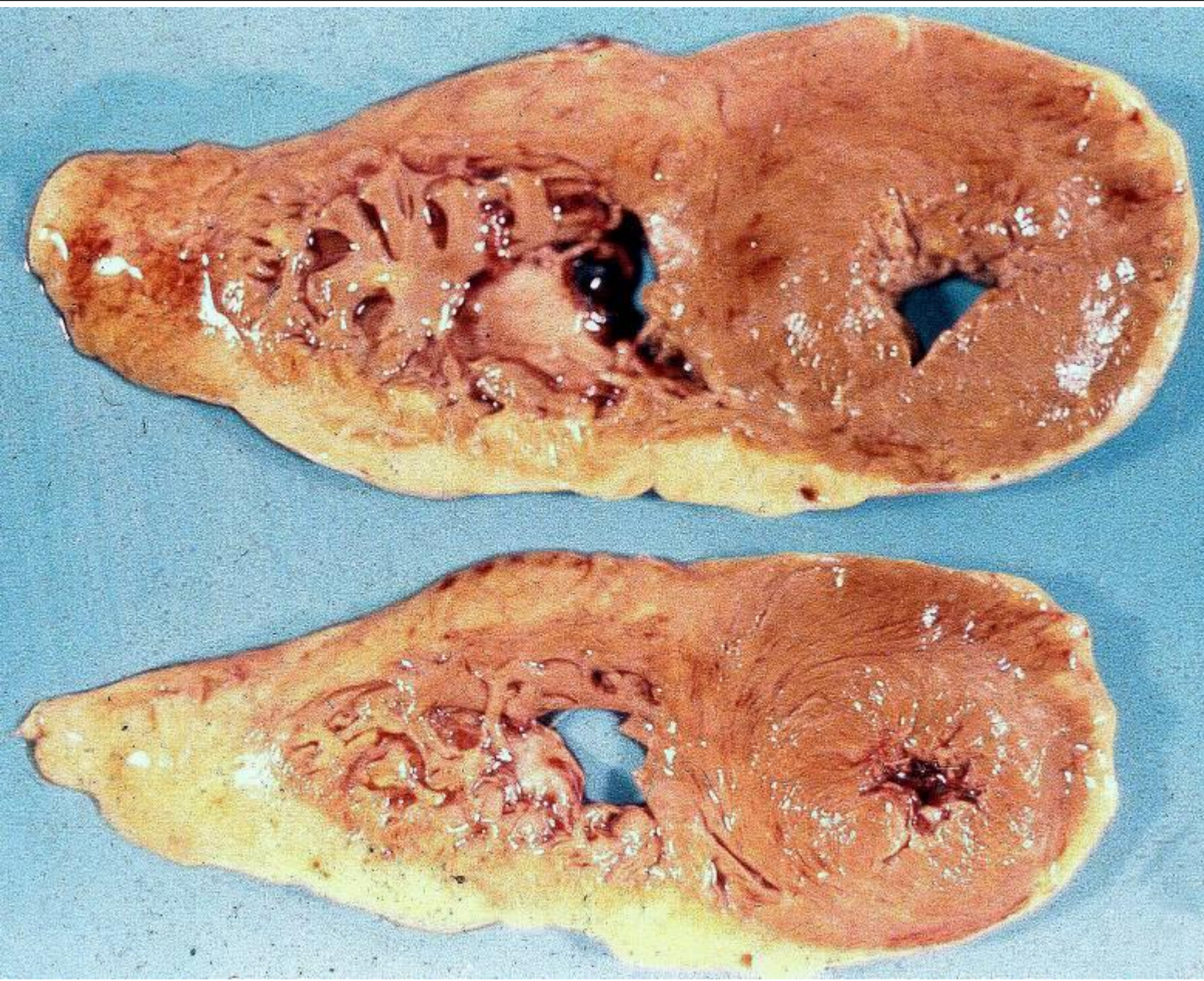


žena 75 let

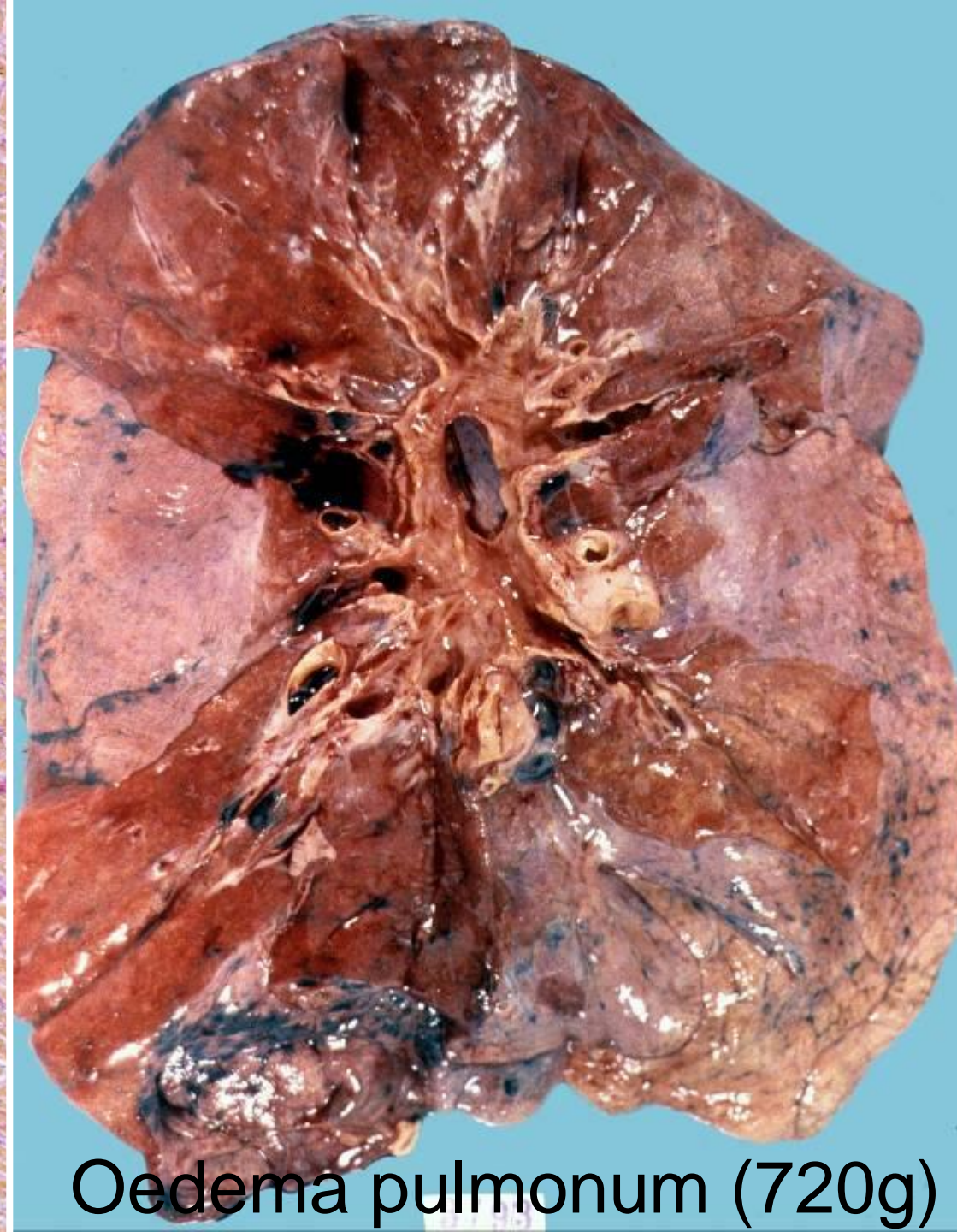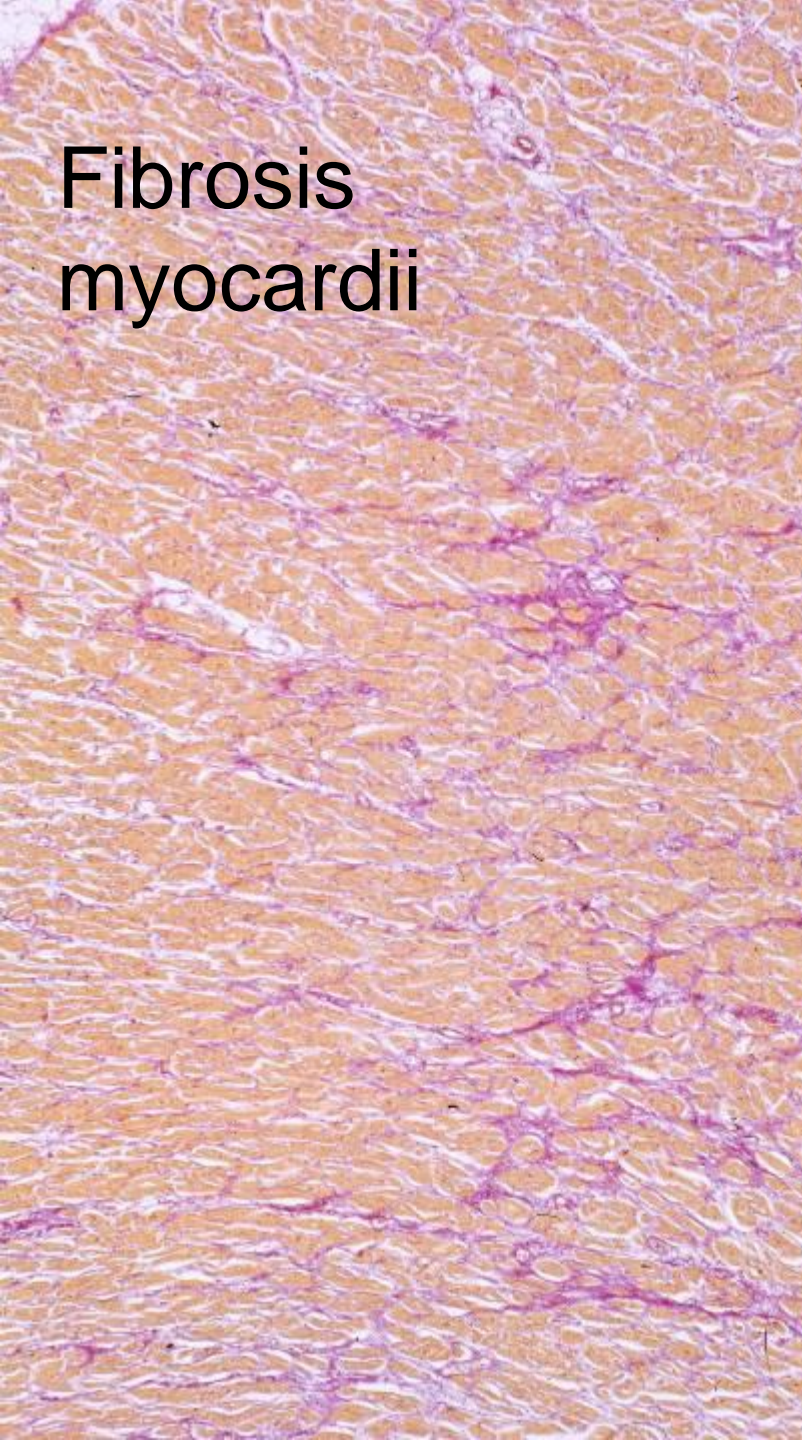
- ❖ 30 let syndrom akromegalie
- ❖ odmítla chirurgické řešení
- ❖ léčena symptomaticky
 - ❖ hyperfunkce thy. – Carbimazol
 - ❖ kardiomegalie - kardiotonika
 - ❖ 5 let před smrtí ca coli – chir. odstraněn
 - ❖ 6 let před smrtí kortikoidně substituována
 - ❖ smrt kardiálním selháním

Hypertrophia excentrica cordis

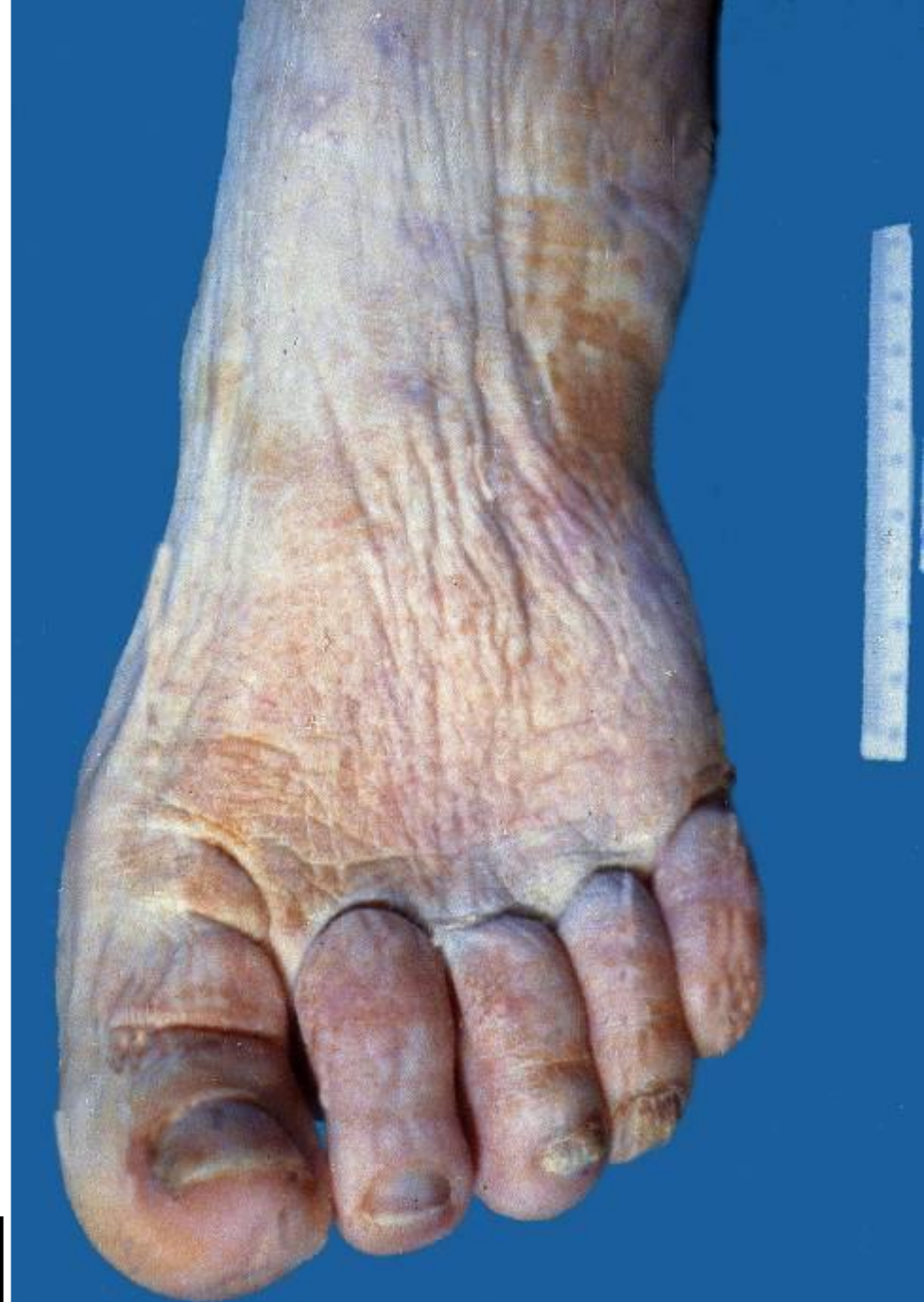
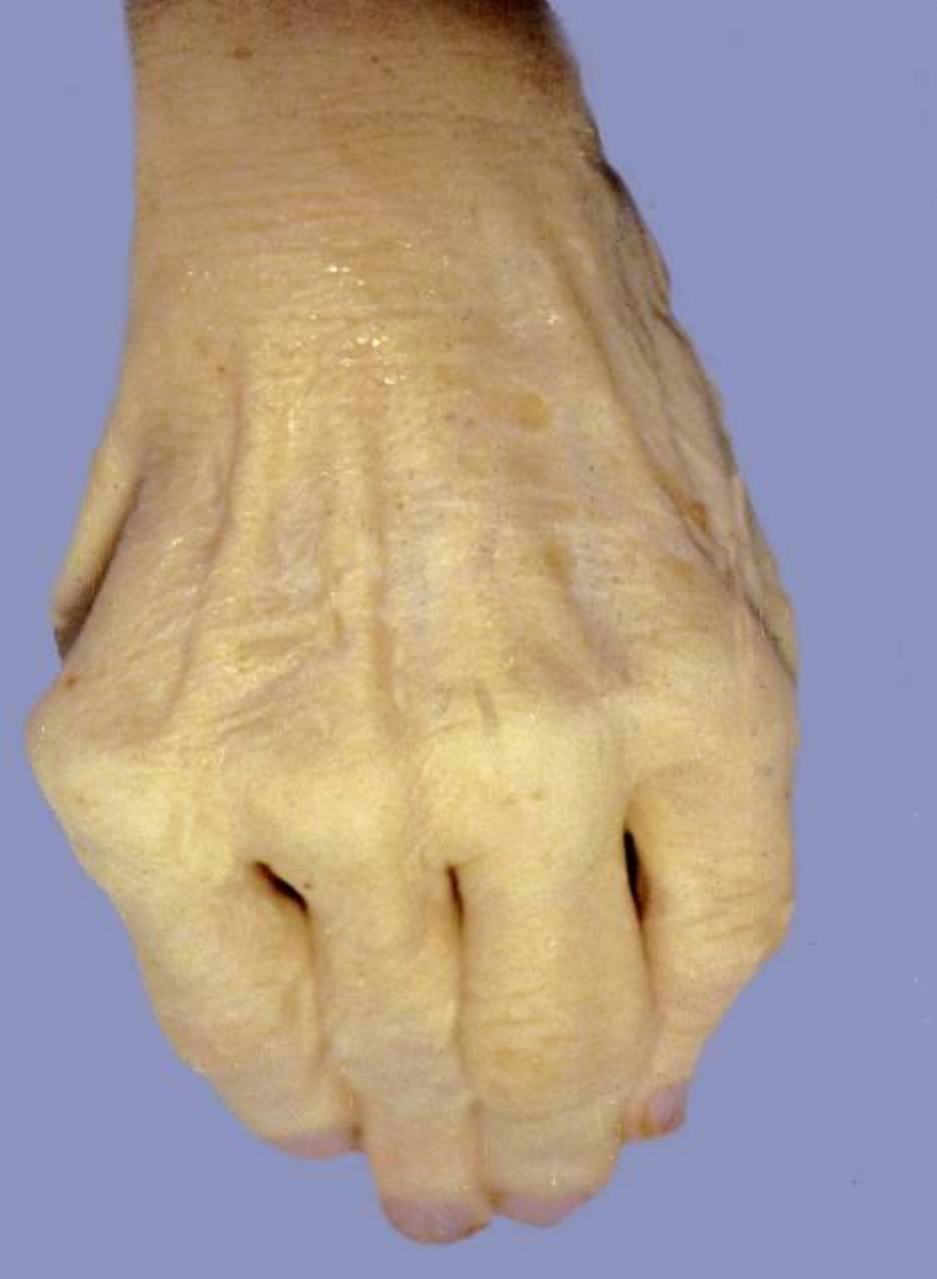
cor
610g

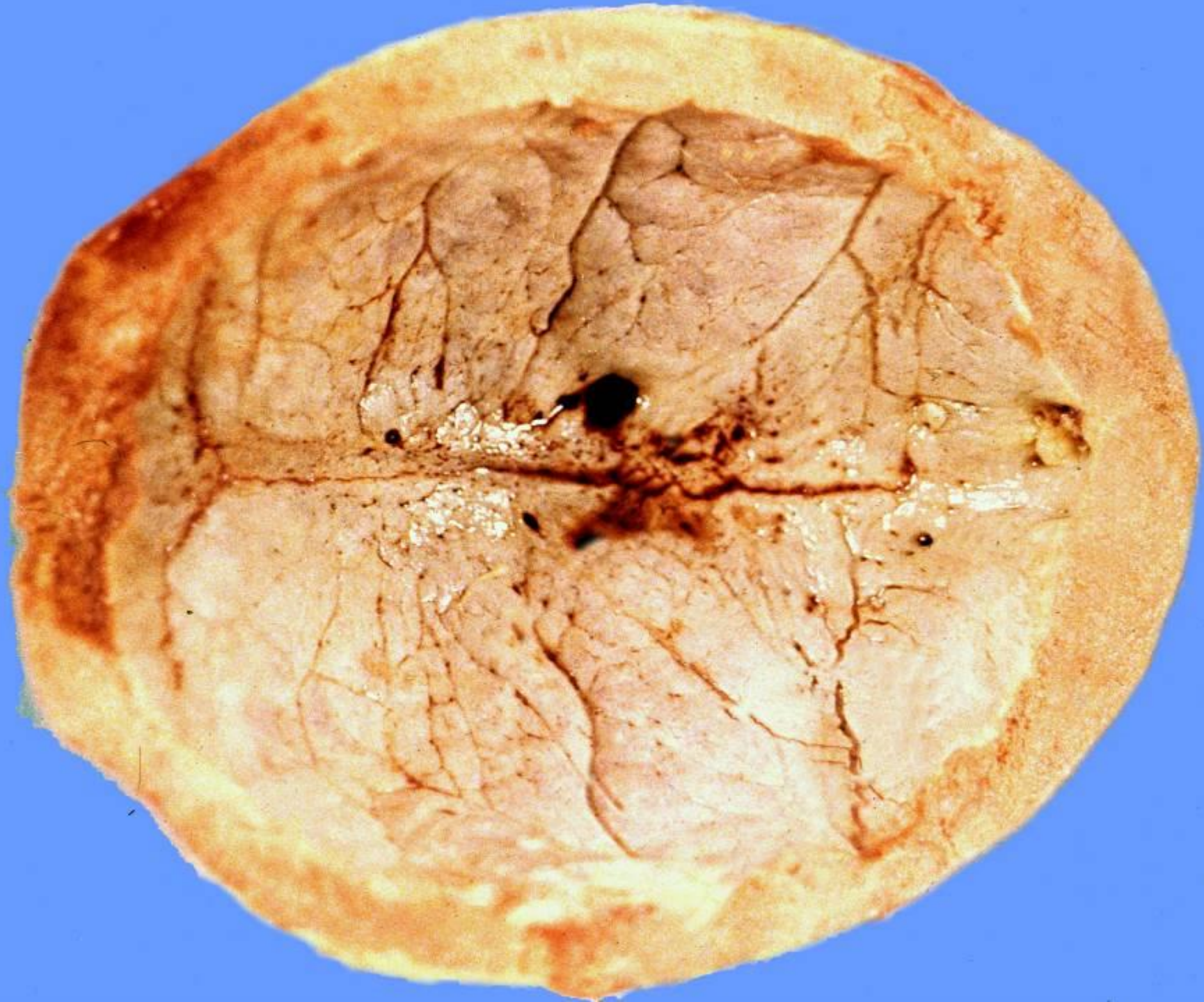
Fibrosis
myocardii

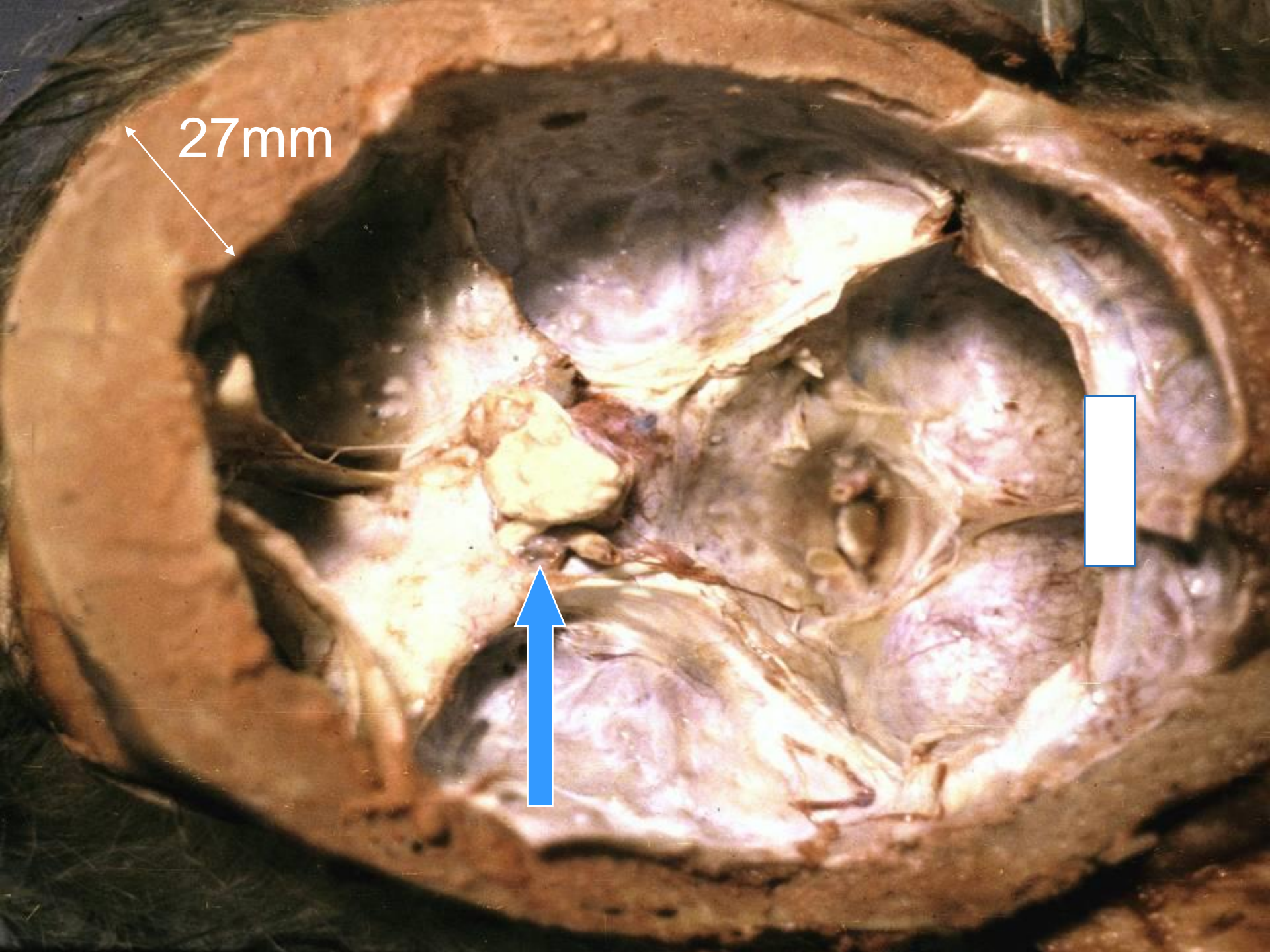


Oedema pulmonum (720g)



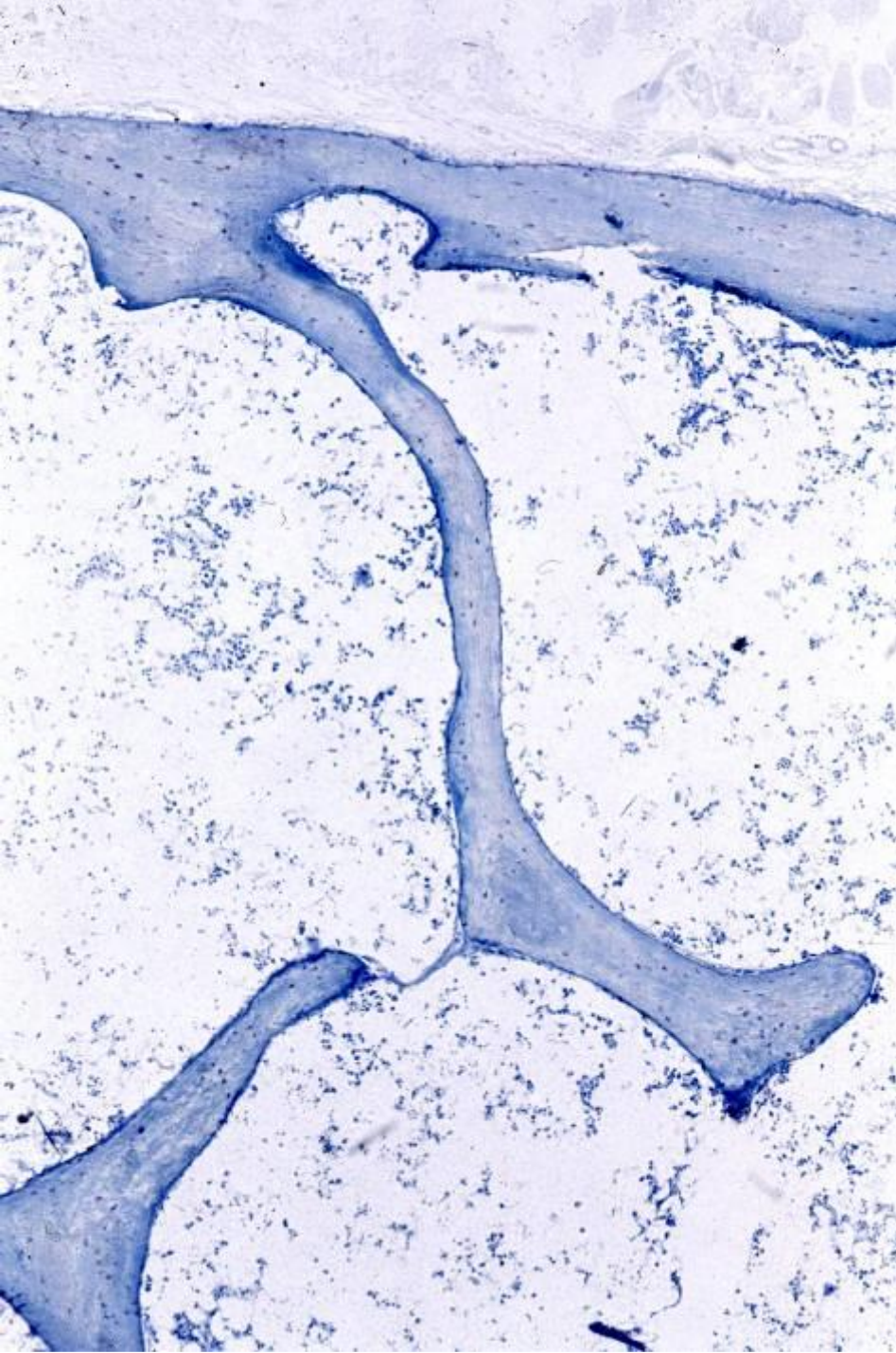
Acromegalia



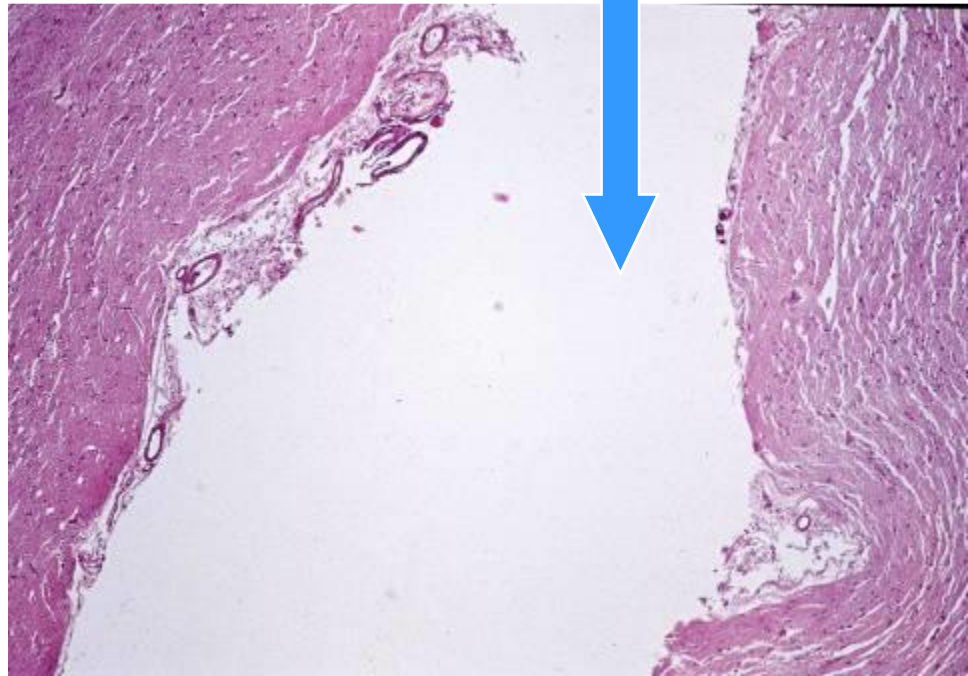


27mm

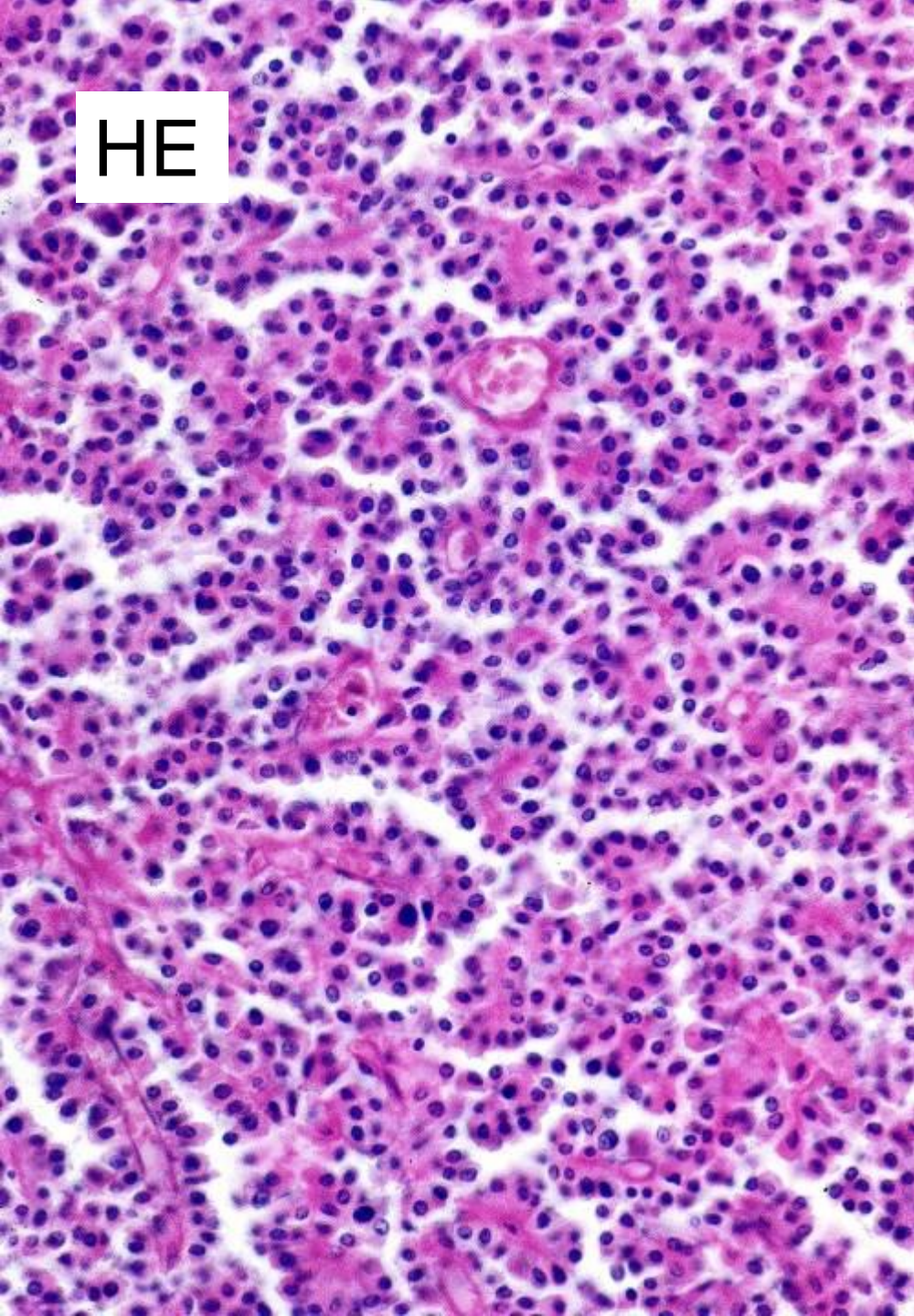




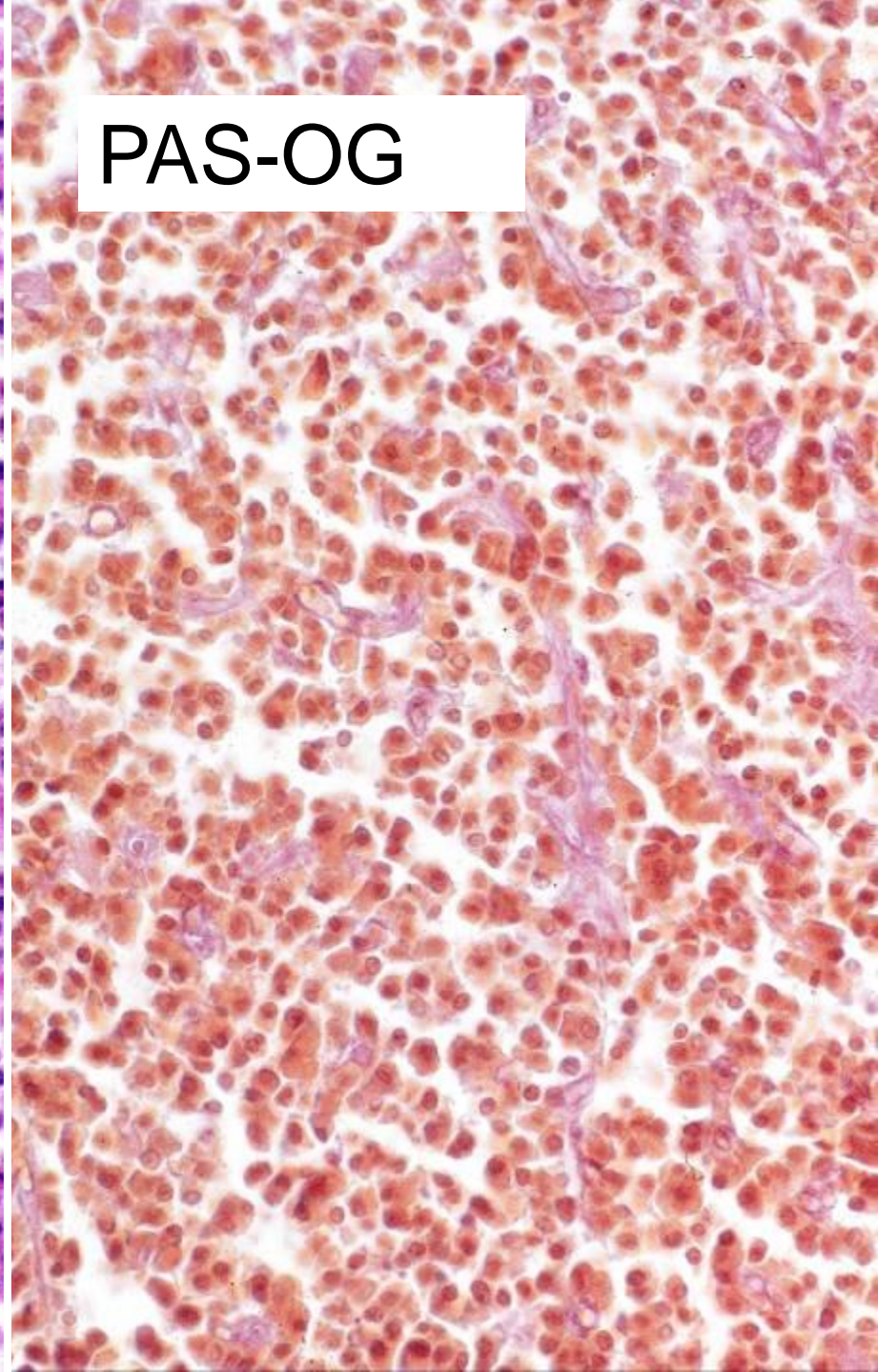
Pseudocystis
postencephalomalacia
hypothalami



HE



PAS-OG



Plurihormonální a plurifunkční adenom hypofýzy se syndromem akromegalie

STH +++

TSH +++

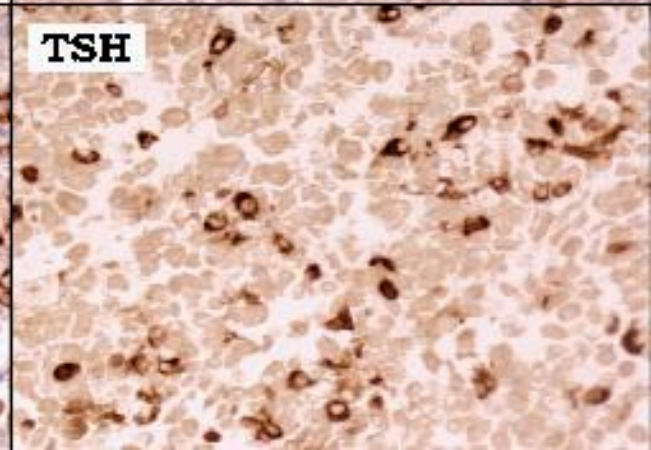
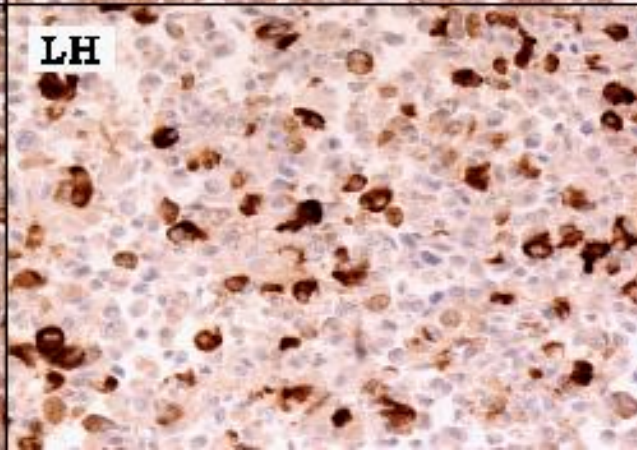
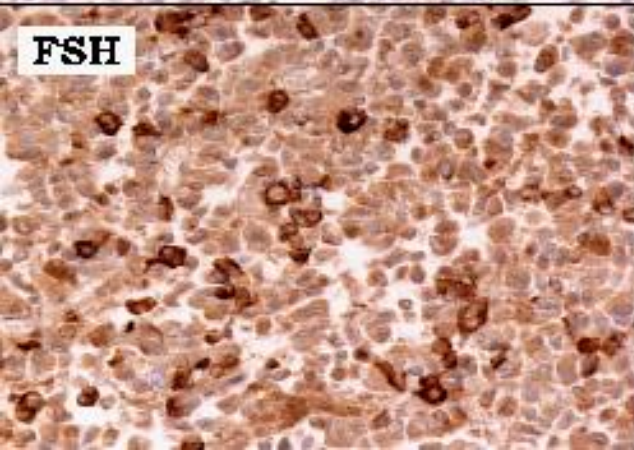
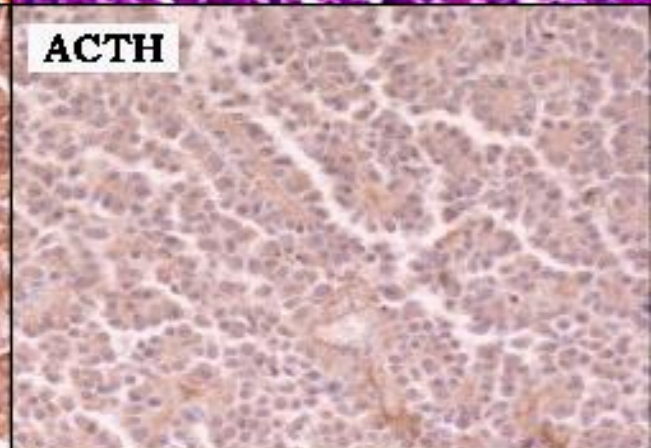
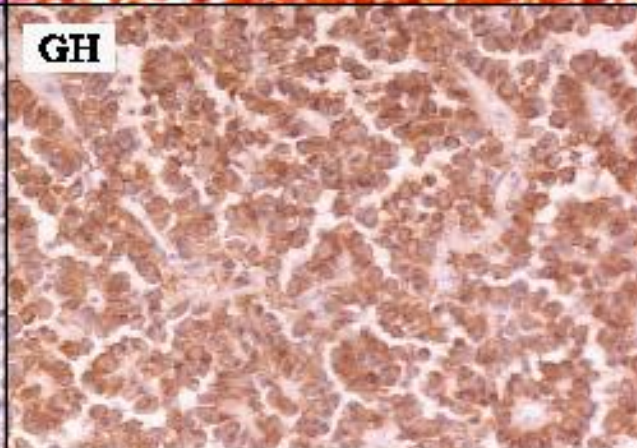
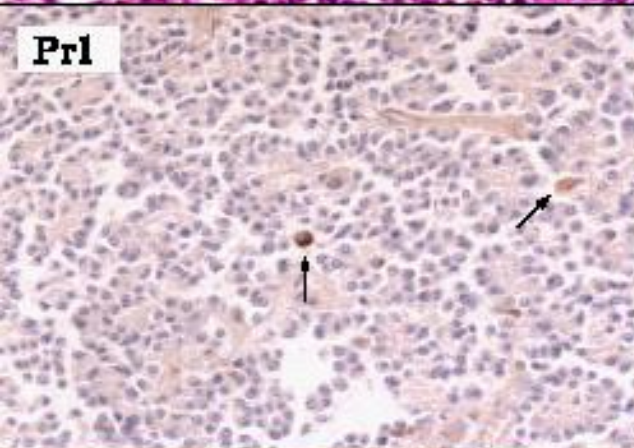
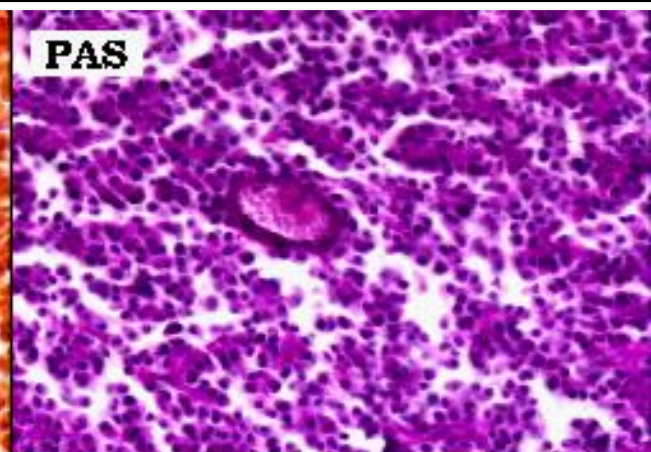
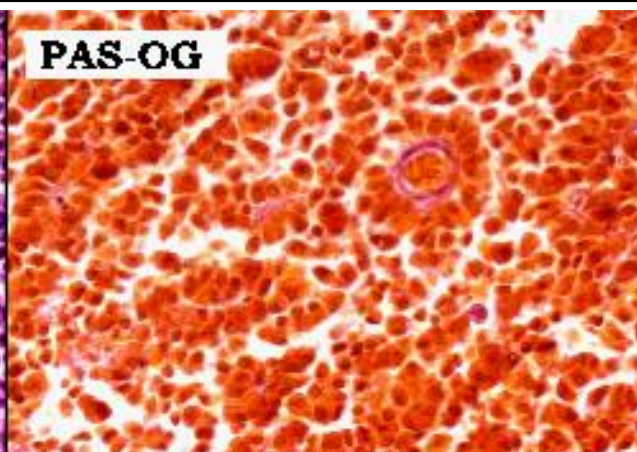
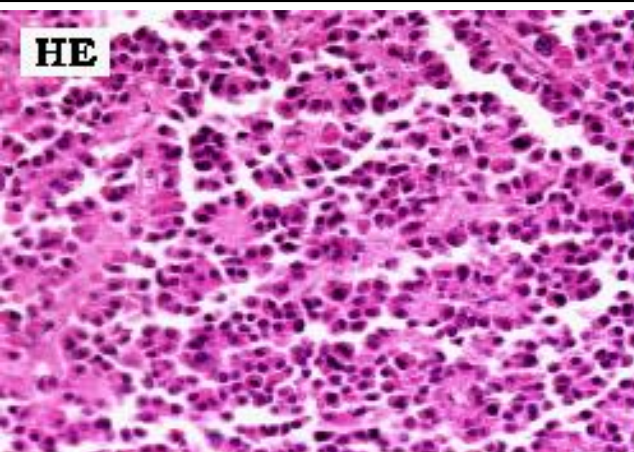
Prl ++

FSH (beta)+

ACTH ++

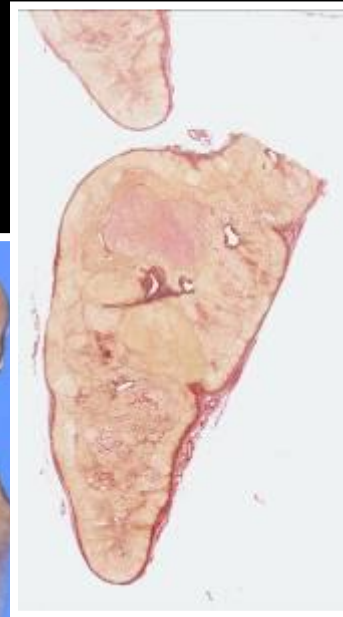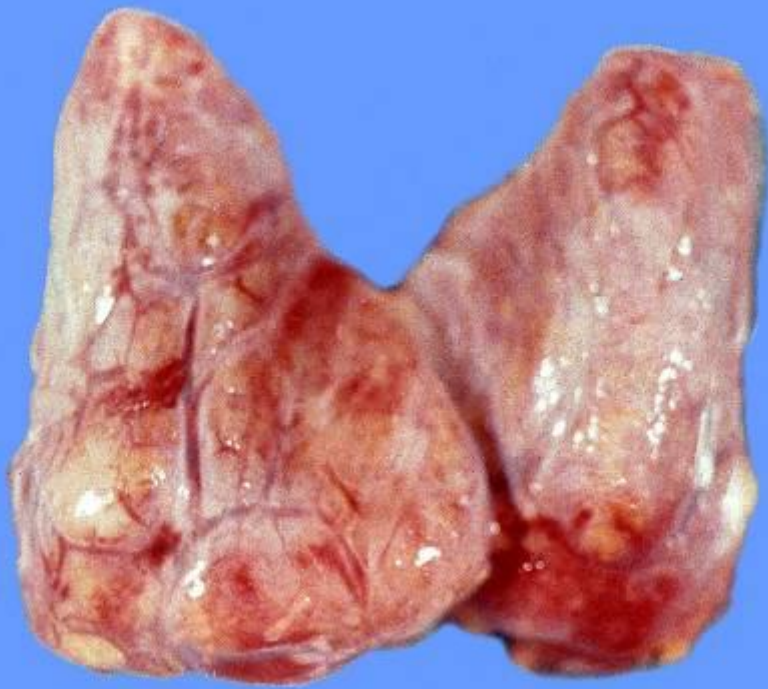LH (beta)+

Adenoma hypophysis



hyperplasia

gl. thyreoideae 125g



hyperplasia
gl. suprarenalium
25g

