


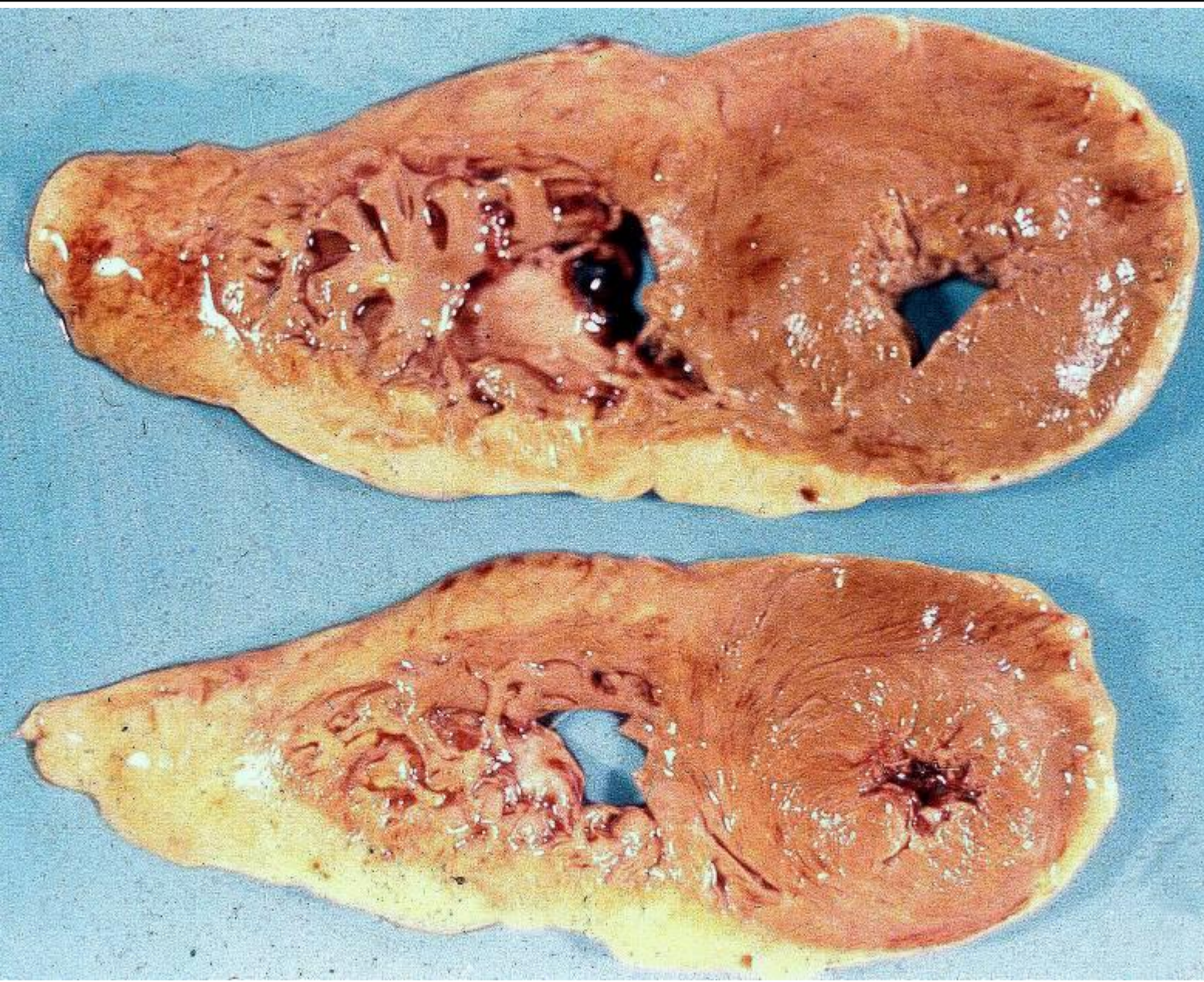
žena 75 let



# Anamnéza

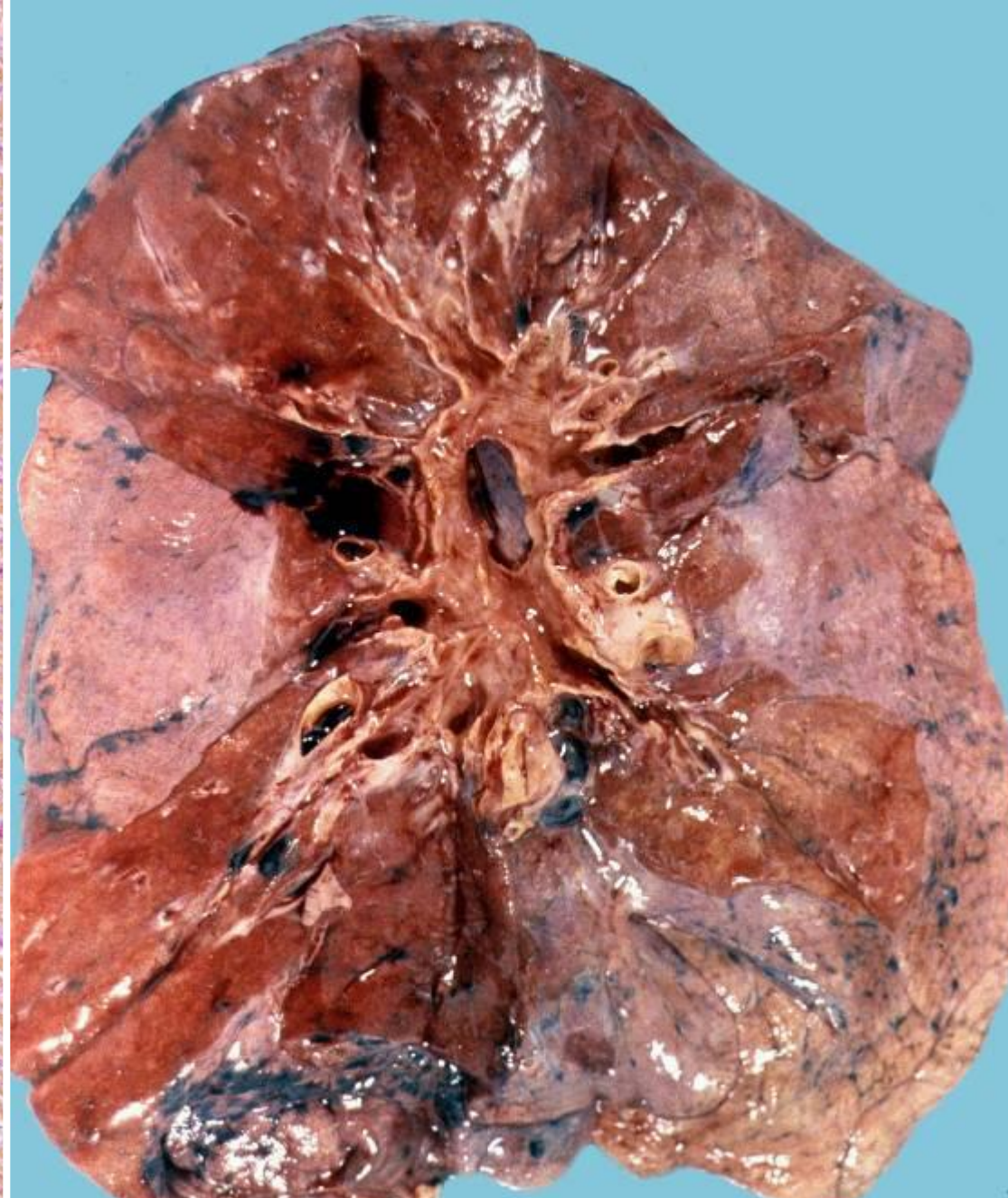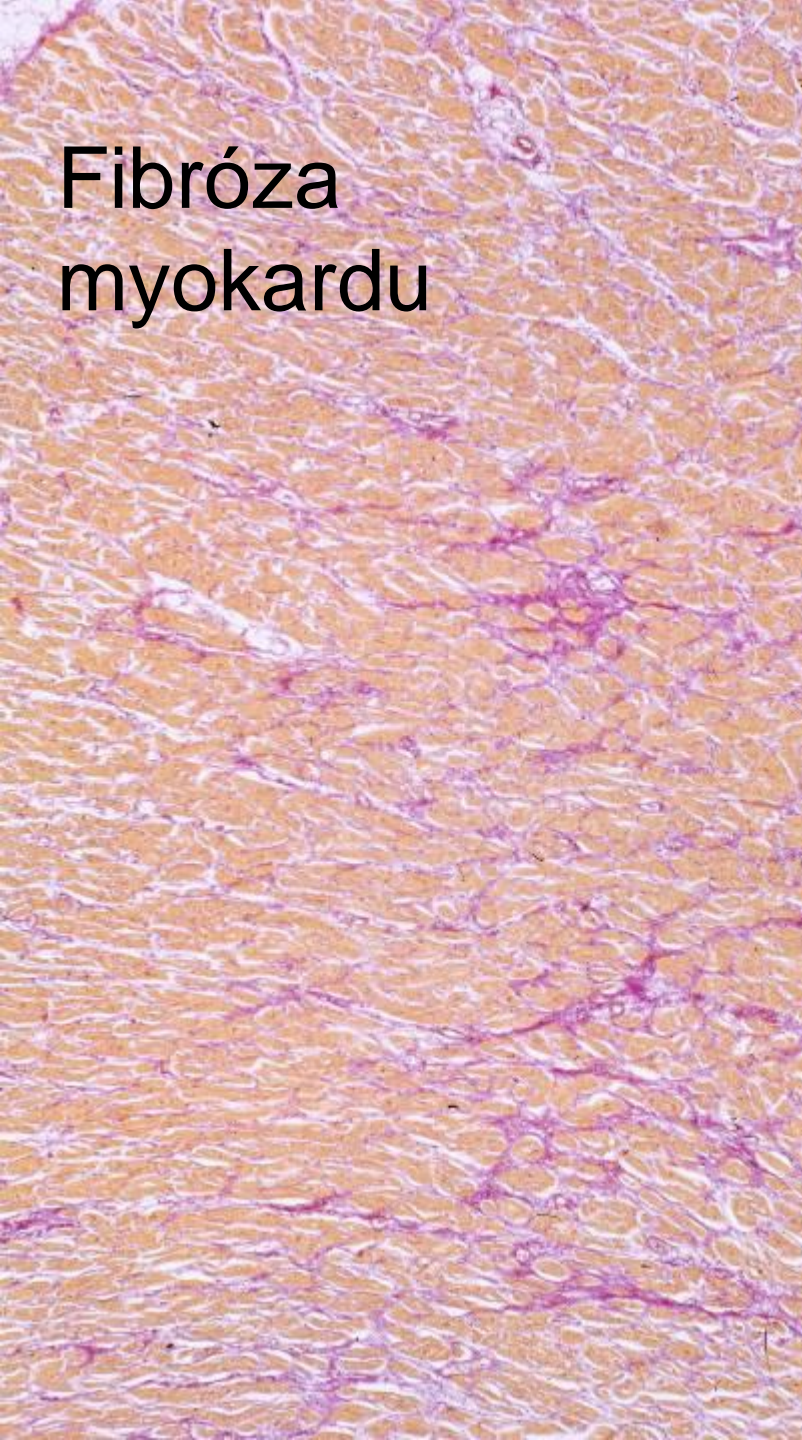
- ❖ 30 let syndrom akromegalie
- ❖ odmítla chirurgické řešení
- ❖ léčena symptomaticky
  - ❖ hyperfunkce thy. – Carbimazol
  - ❖ kardiomegalie - kardiotonika
  - ❖ 5 let před smrtí ca coli – chir. odstraněn
  - ❖ 6 let před smrtí kortikoidně substituována
  - ❖ smrt kardiálním selháním

# Hypertrofie srdce – excentrická

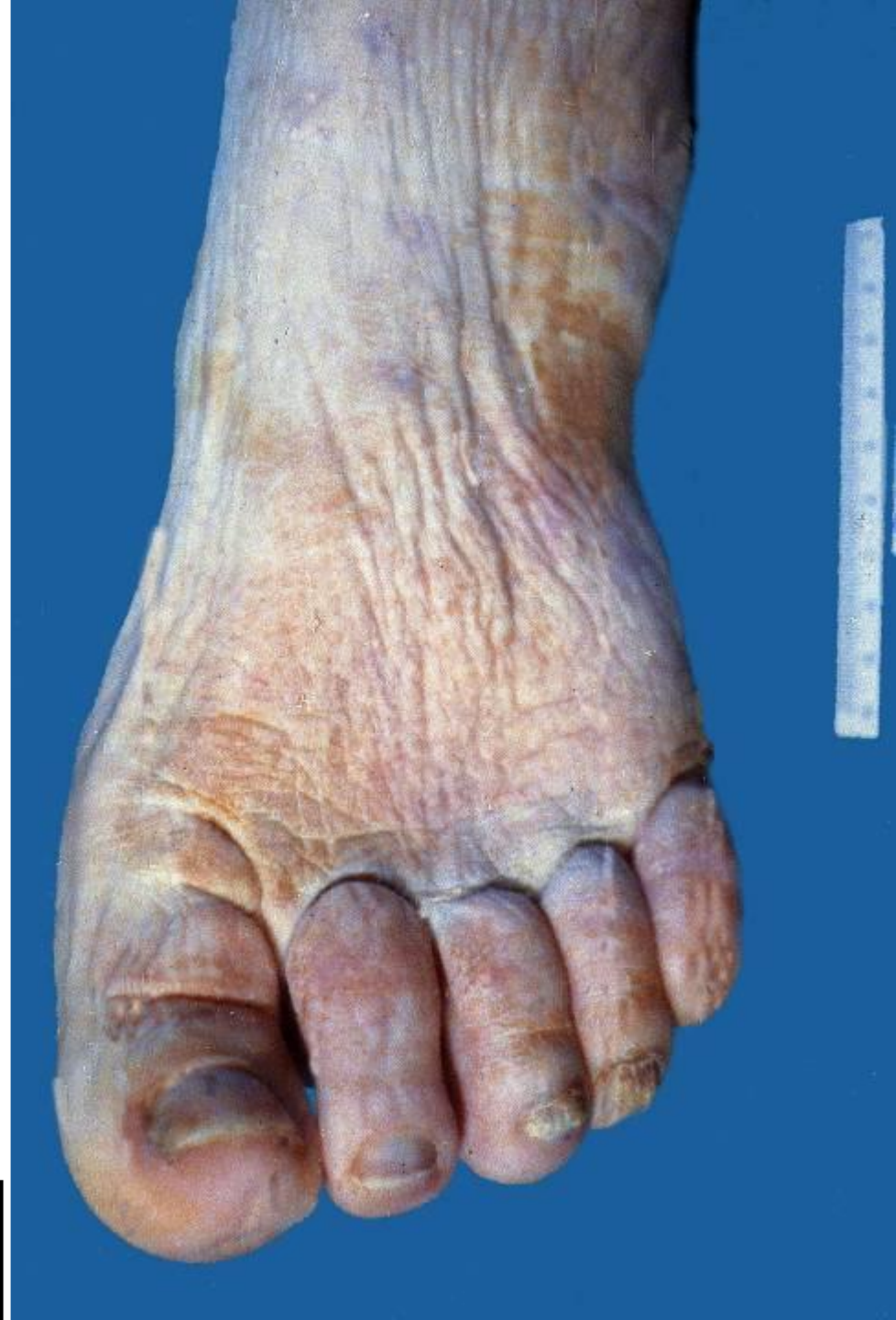
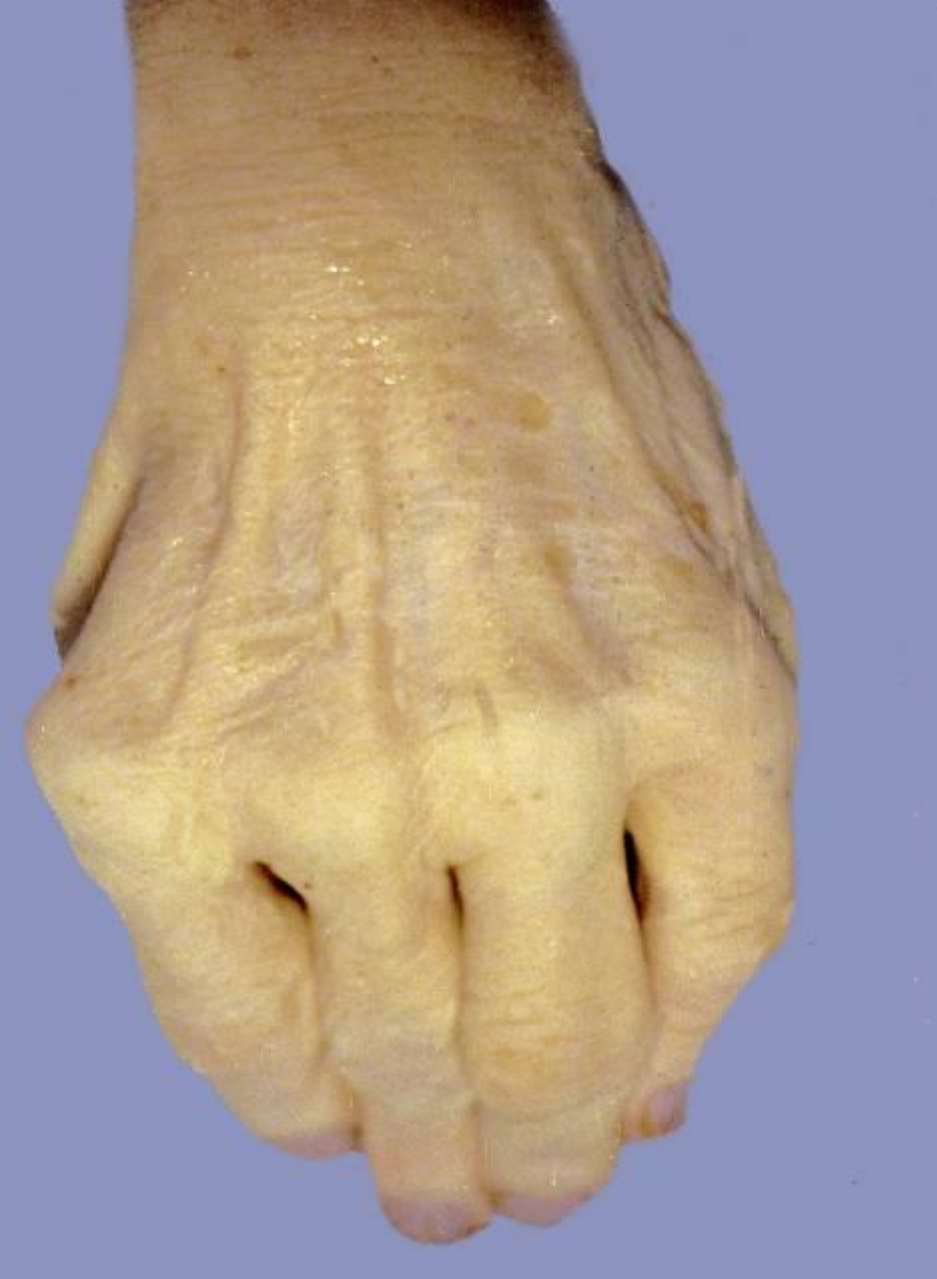
610g

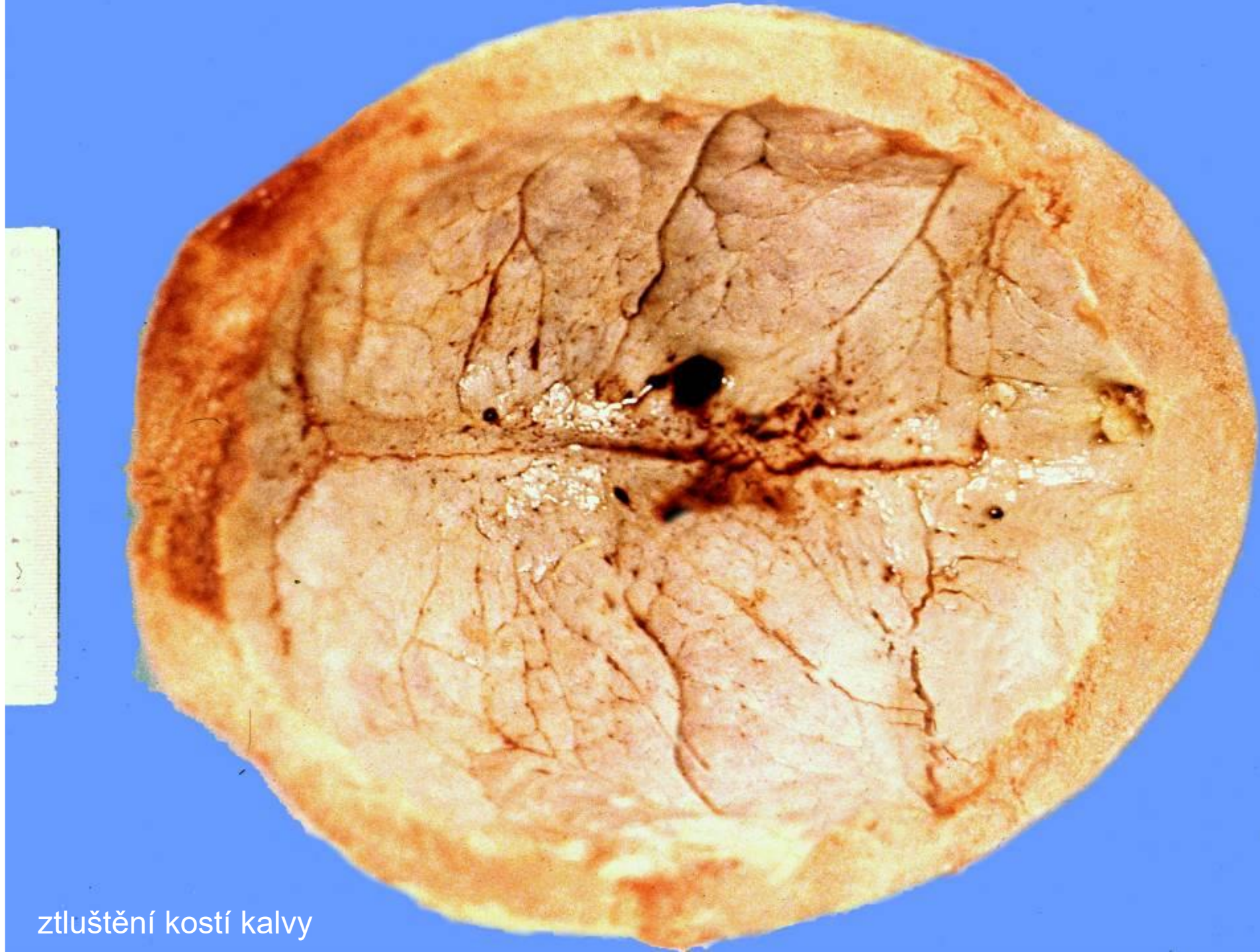
Fibróza  
myokardu



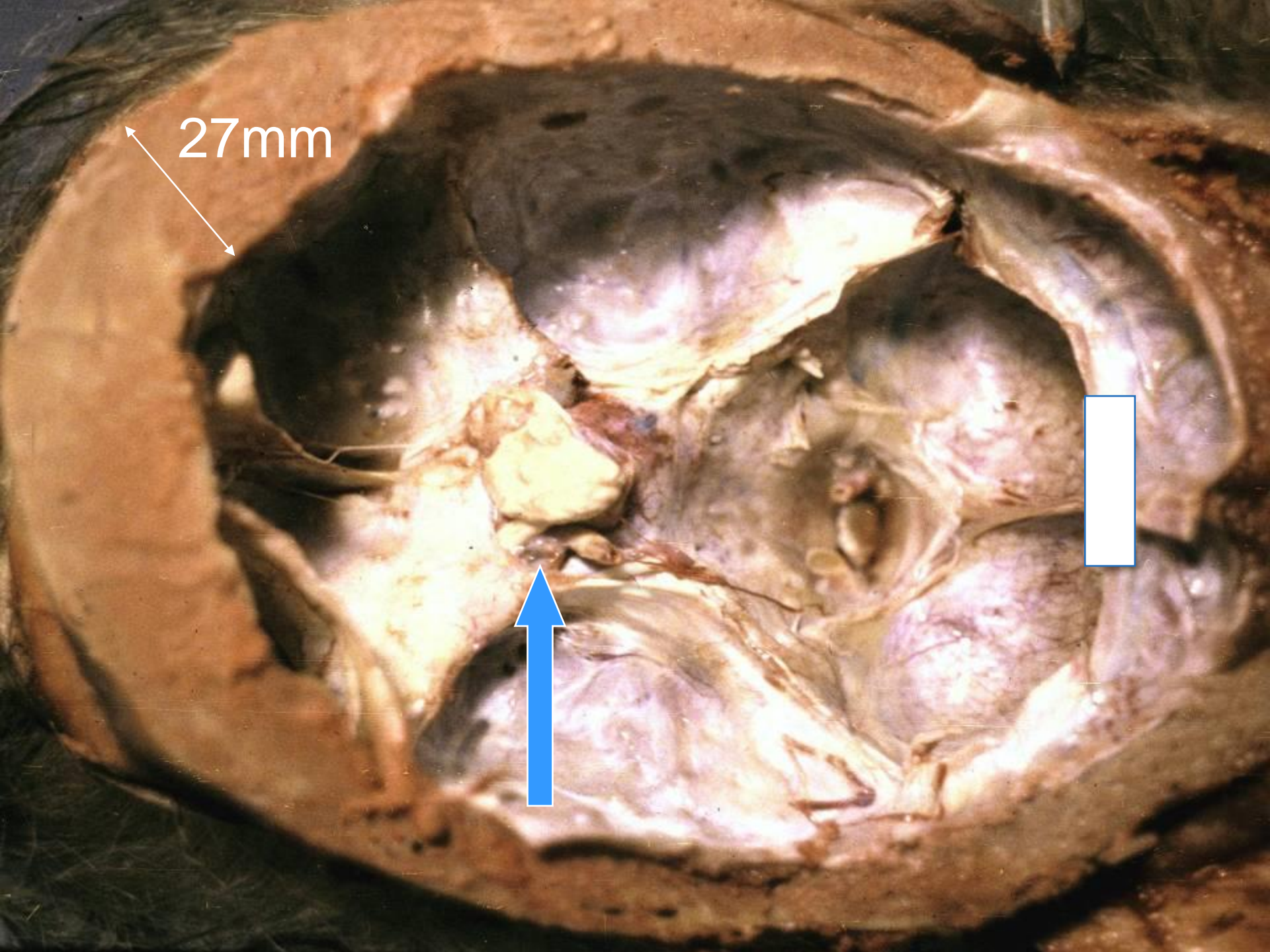
Otok plic (720g)




Akromegalie

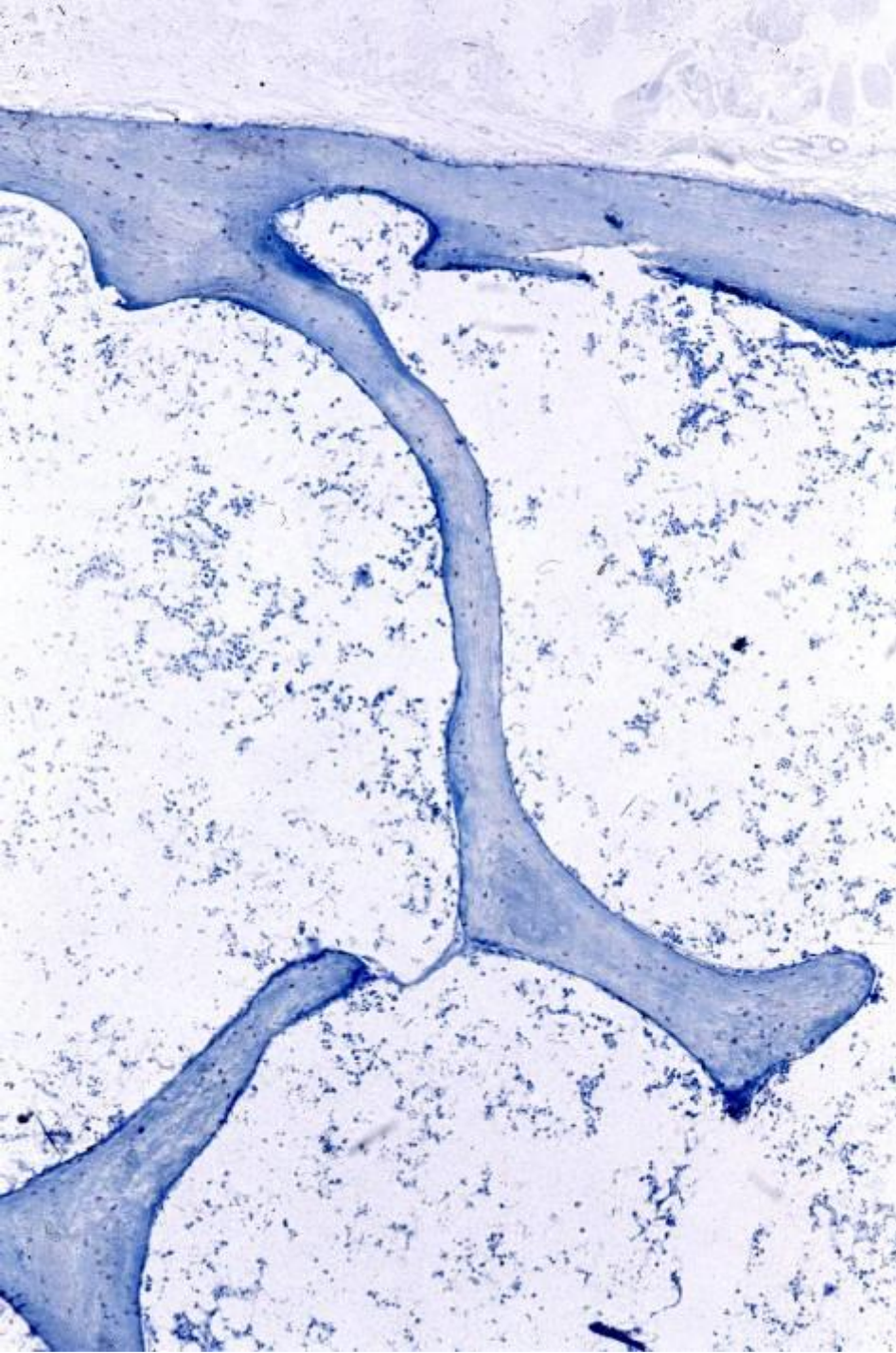


ztluštění kostí kalvy

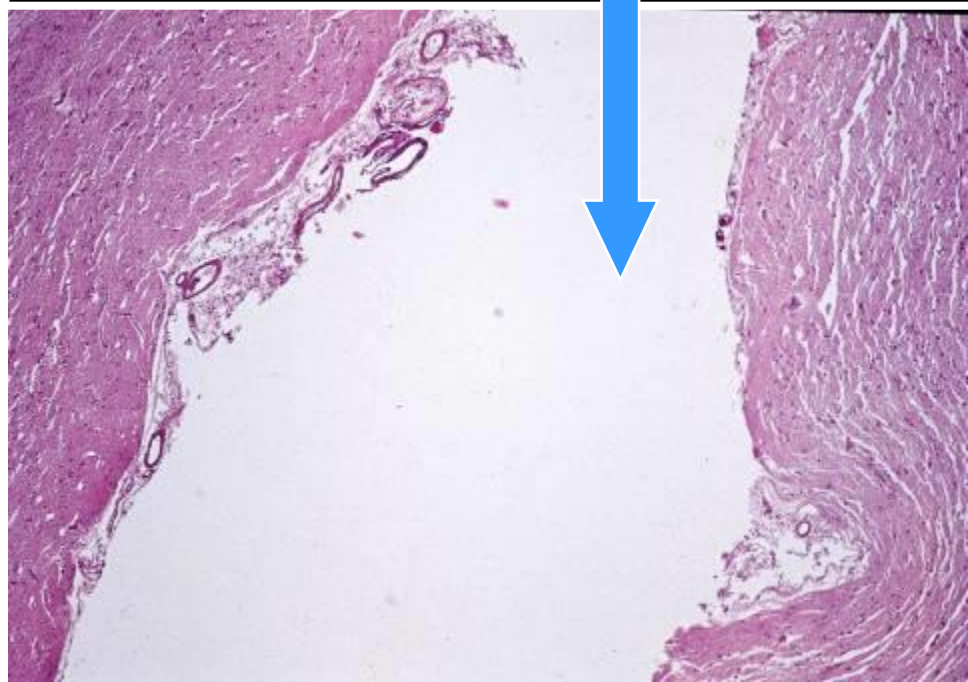


27mm



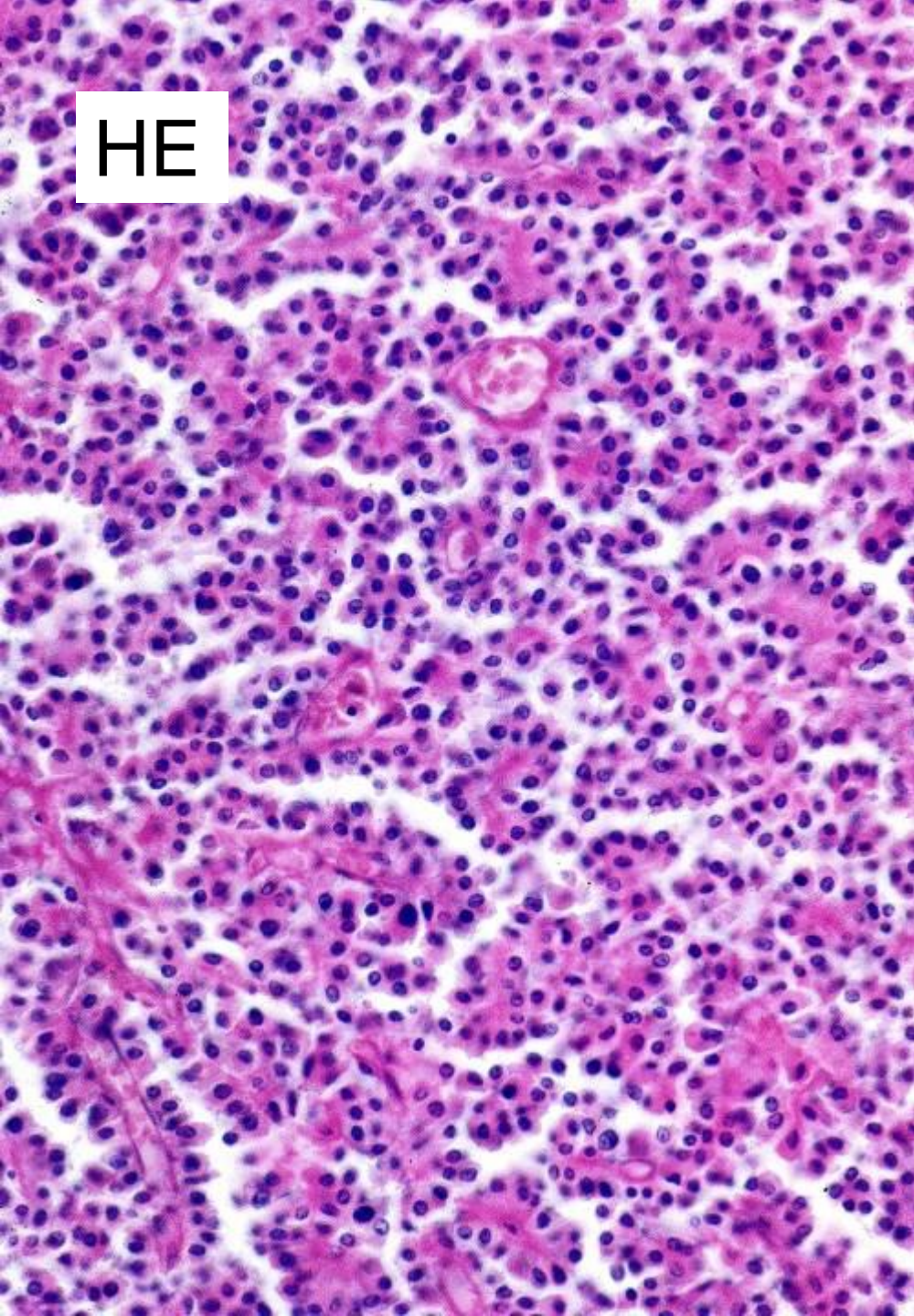


Pseudocyst  
postencefalomalatická  
hypothalamu

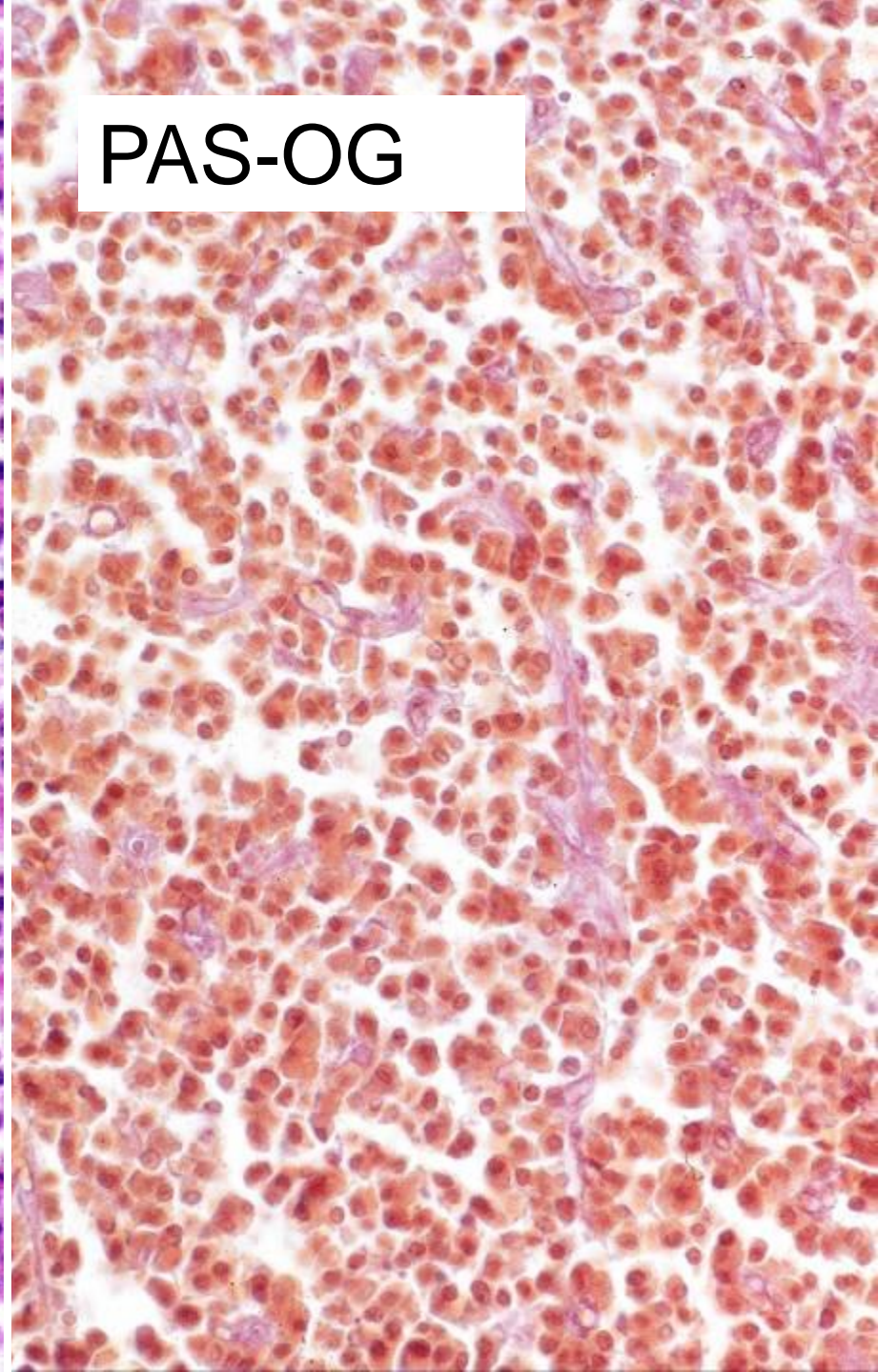




HE



PAS-OG



# Plurihormonální a plurifunkční adenom hypofýzy se syndromem akromegalie

STH +++

TSH +++

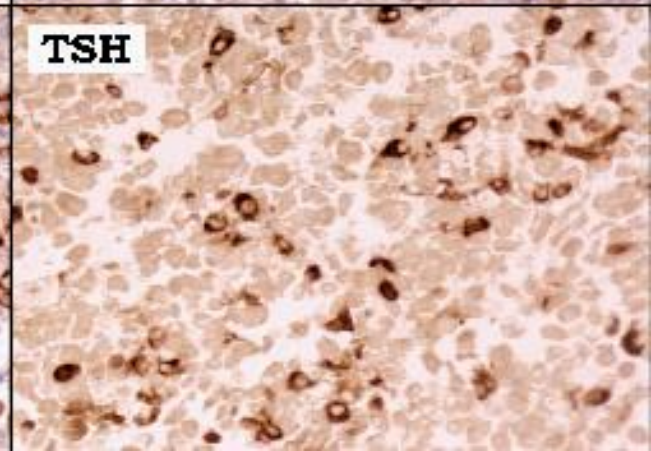
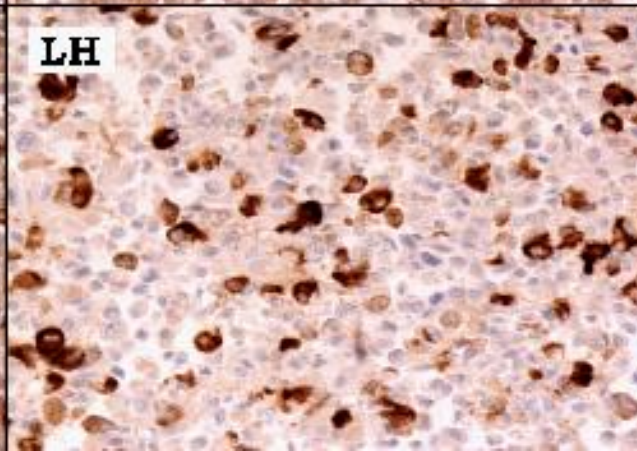
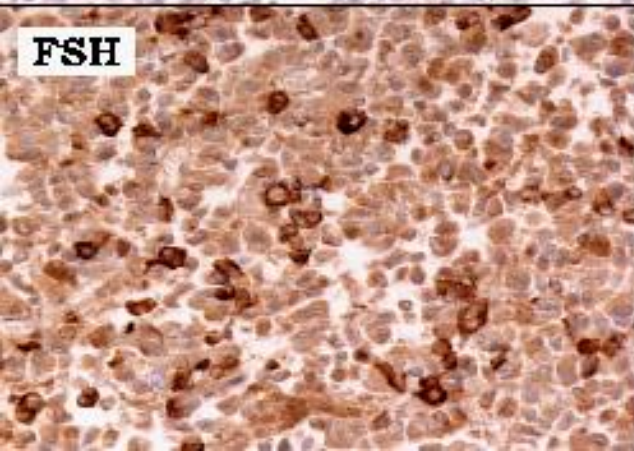
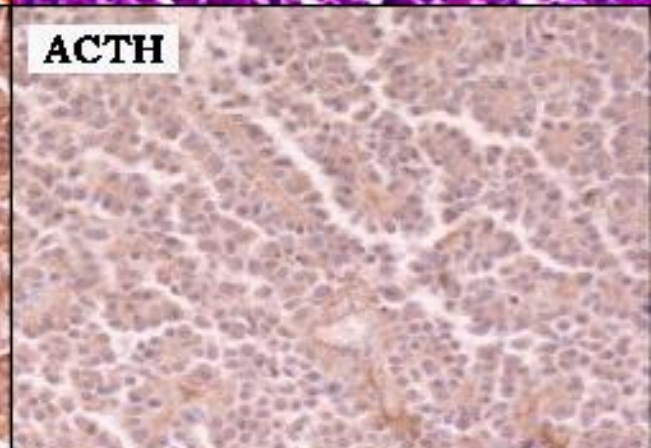
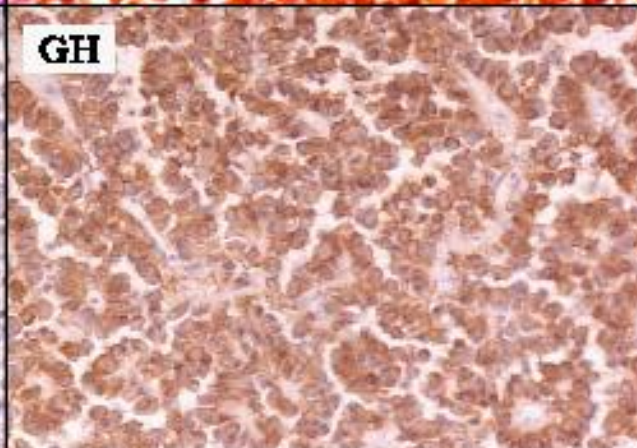
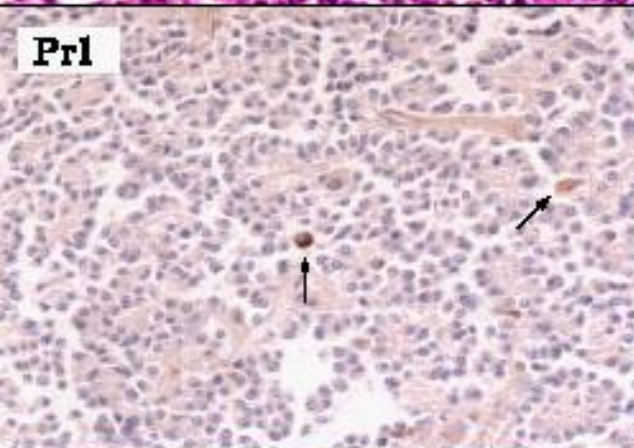
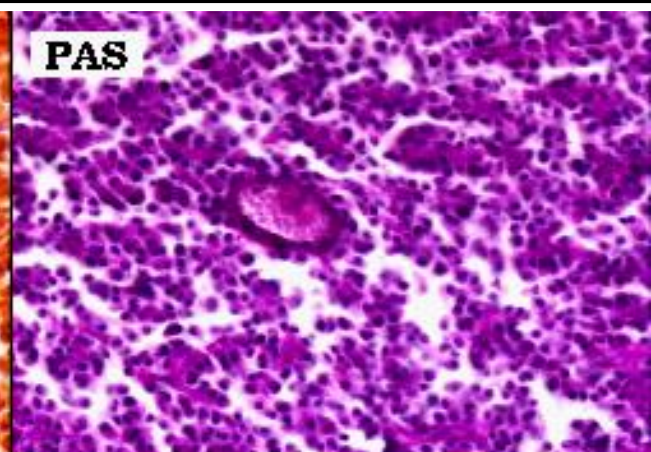
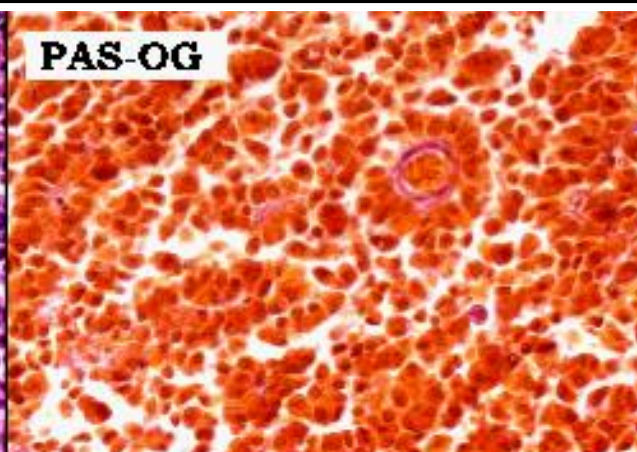
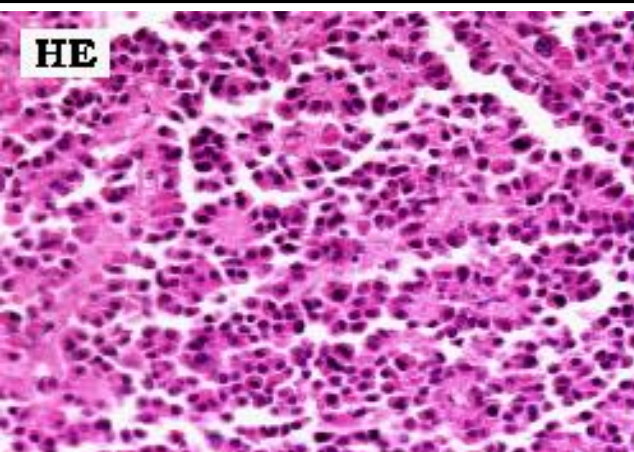
Prl ++

FSH (beta)+

ACTH ++

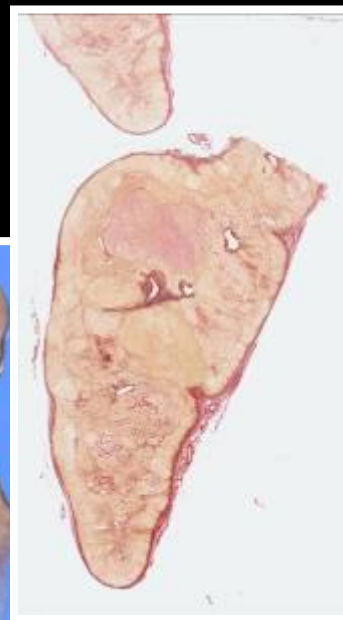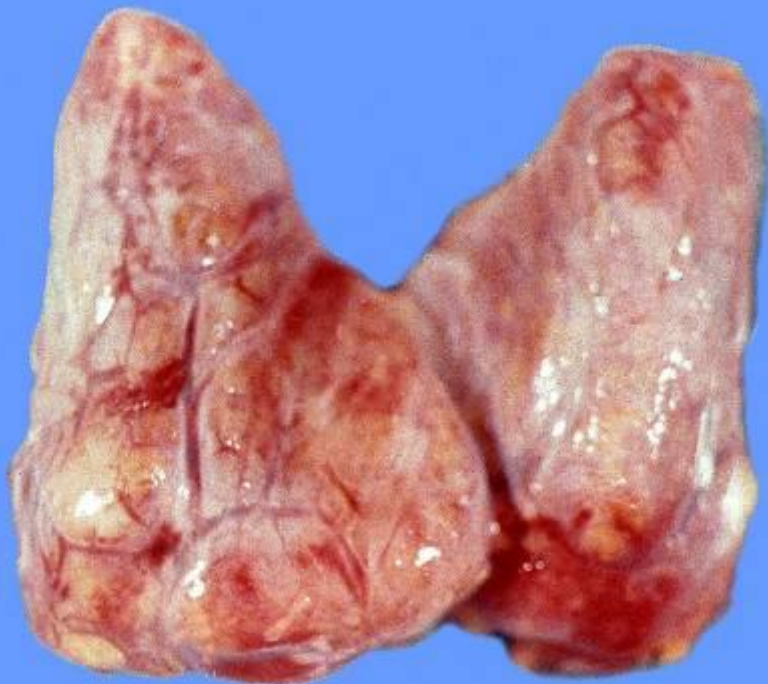LH (beta)+

# Adenoma hypophysis



hyperplázie

štítné žlázy 125g



hyperplázie  
nadledvin

25g

