



Sestup pánevních orgánů

Lenka Krobová

Co to je?

Pokles jednoho či více:

Přední poševní stěna

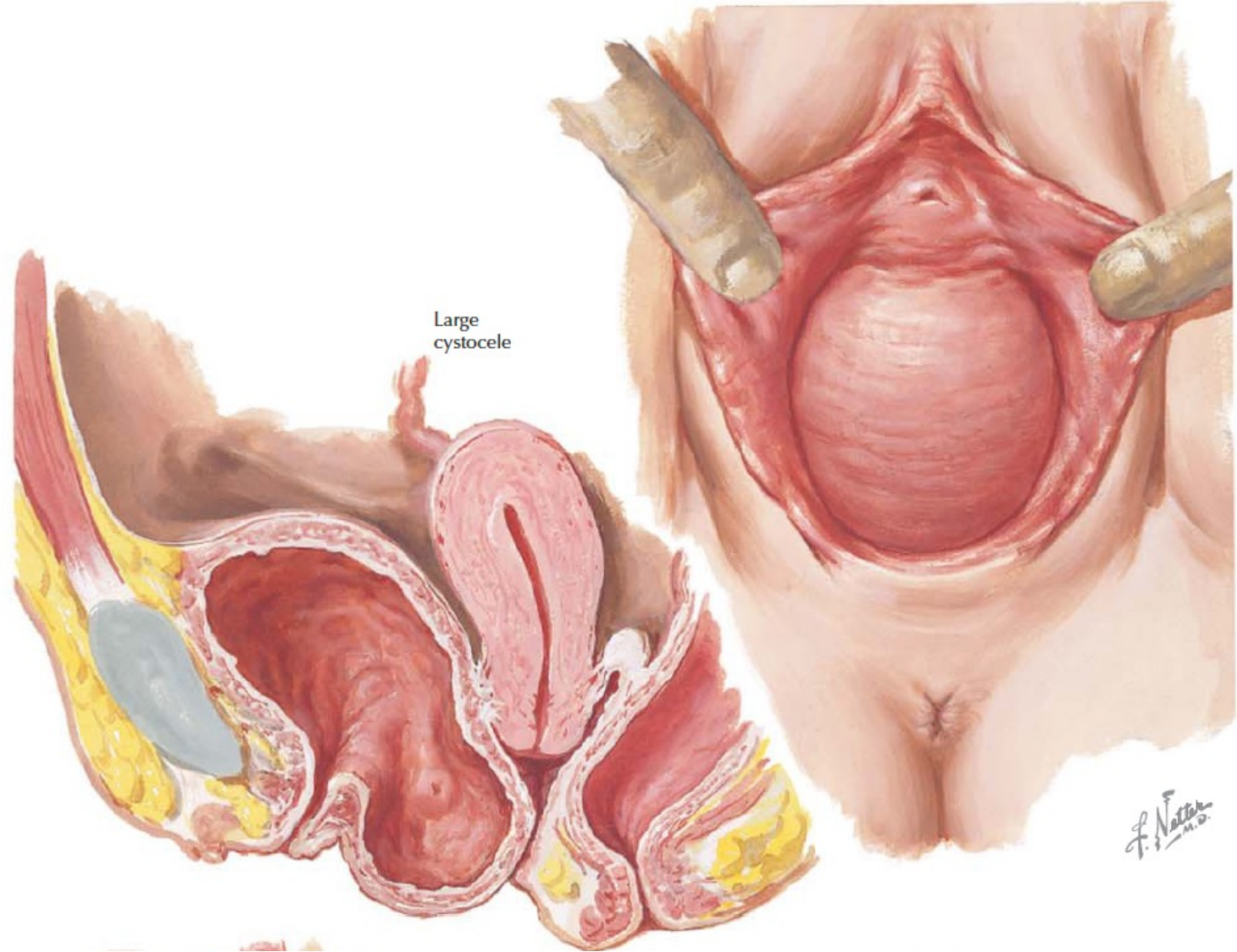
Zadní poševní stěna

Děloha nebo vrchol poševního pahýlu

Až 40% žen – 50+ let až 50%

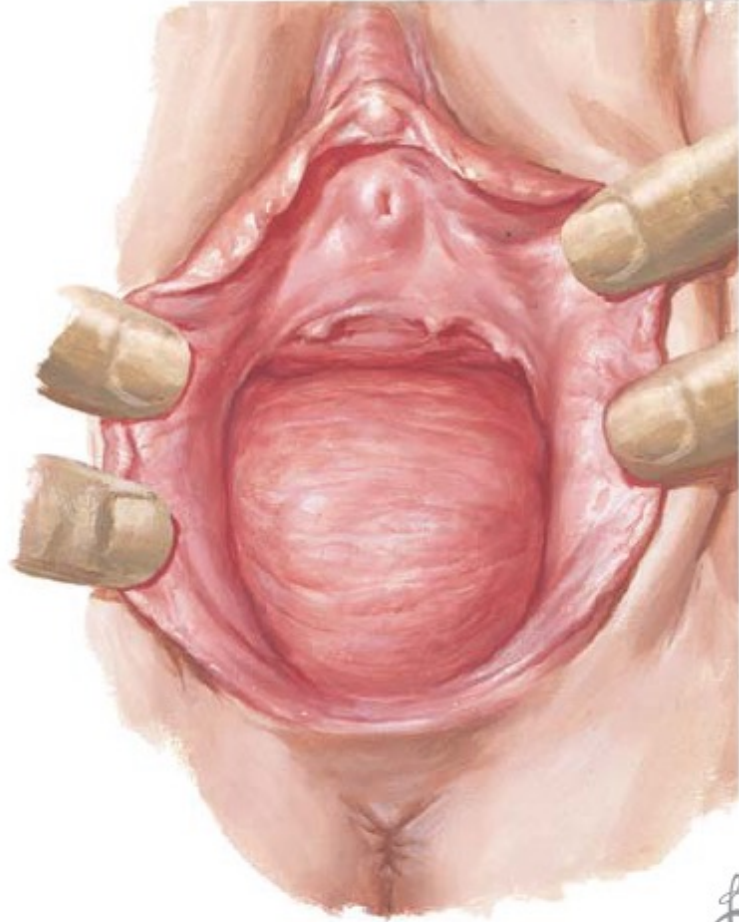Rizikové faktory:

- Parita
- Věk
- Obezita
- Poruchy vaziva
- Nervové poruchy
- Chronická obstipace
- Hormonální dysfunkce
- Námaha



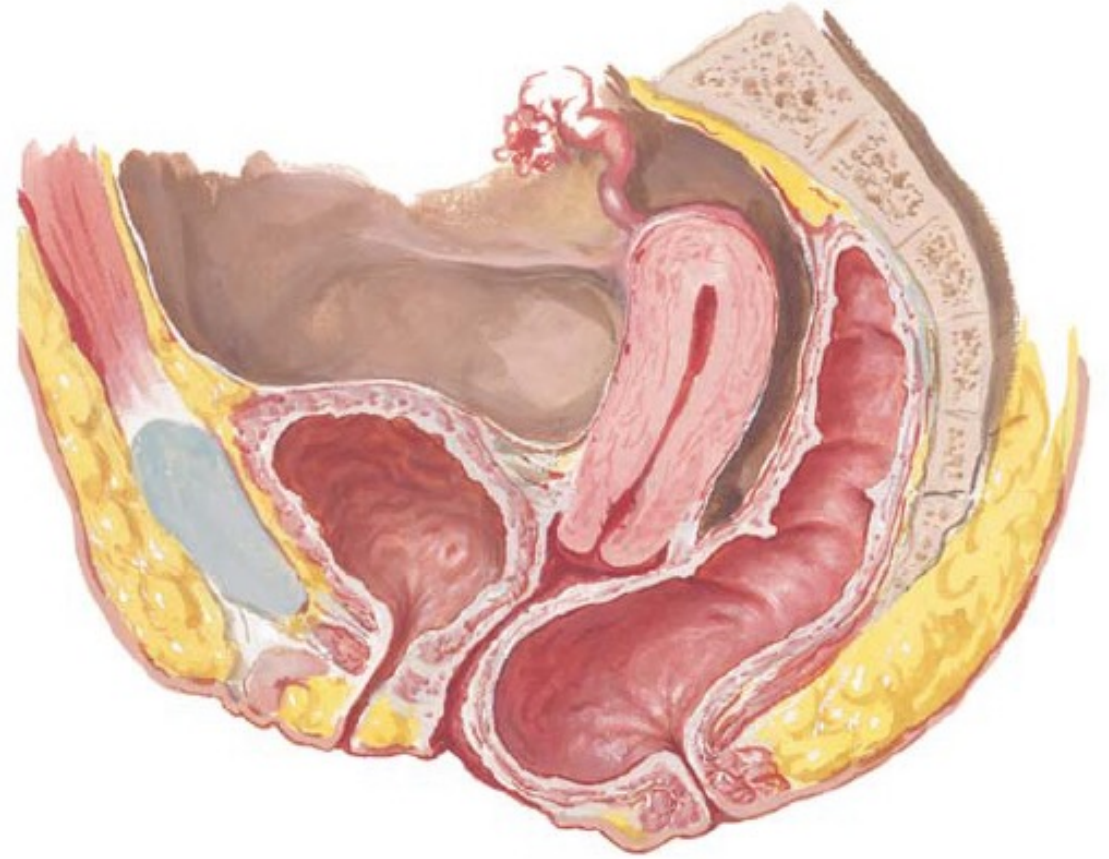
Large cystocele

F. Netter
M.D.

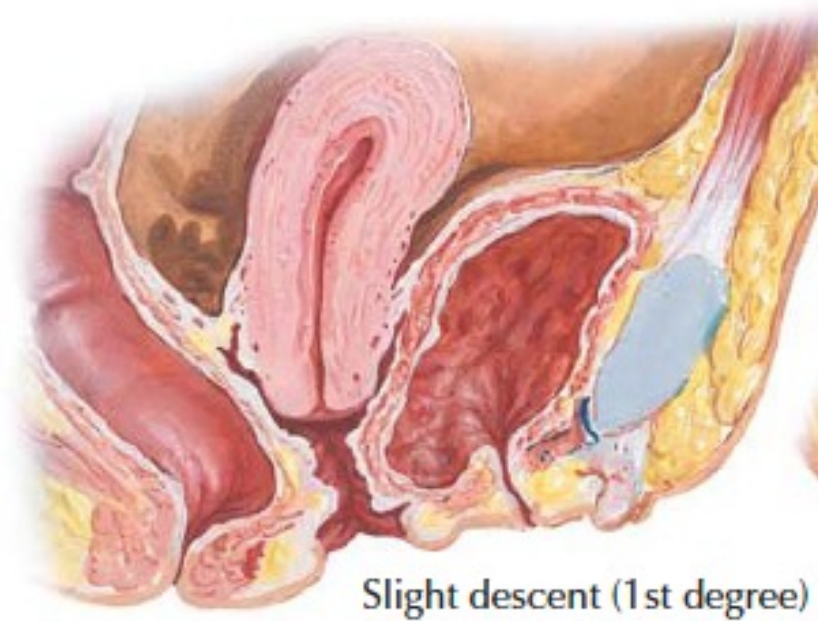


Large rectocele

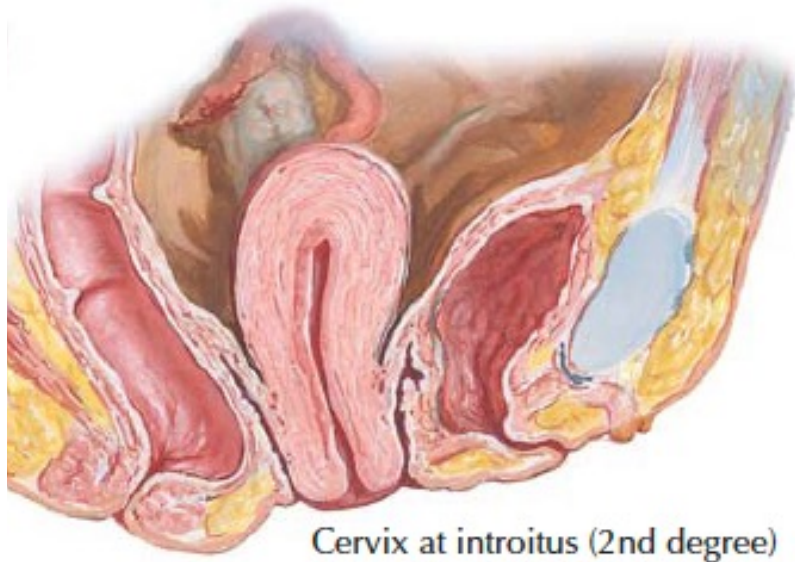
*F. Netter
M.D.*



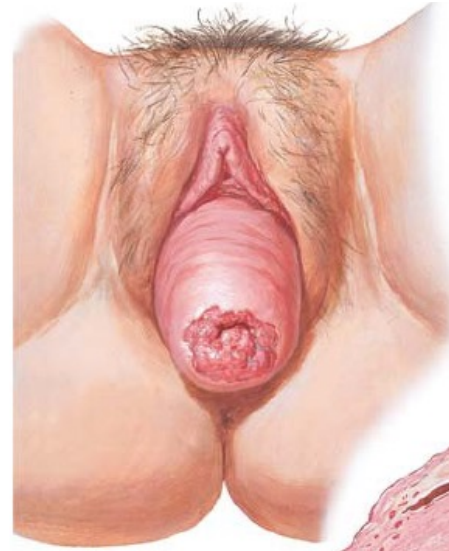Rectocele



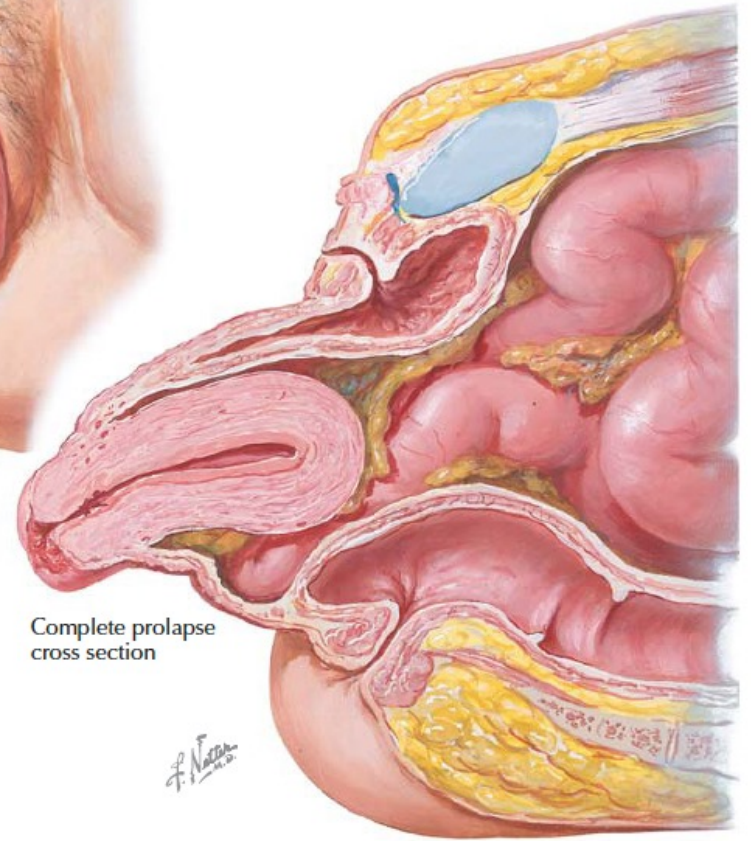
Slight descent (1st degree)



Cervix at introitus (2nd degree)



Clinical appearance
procidentia

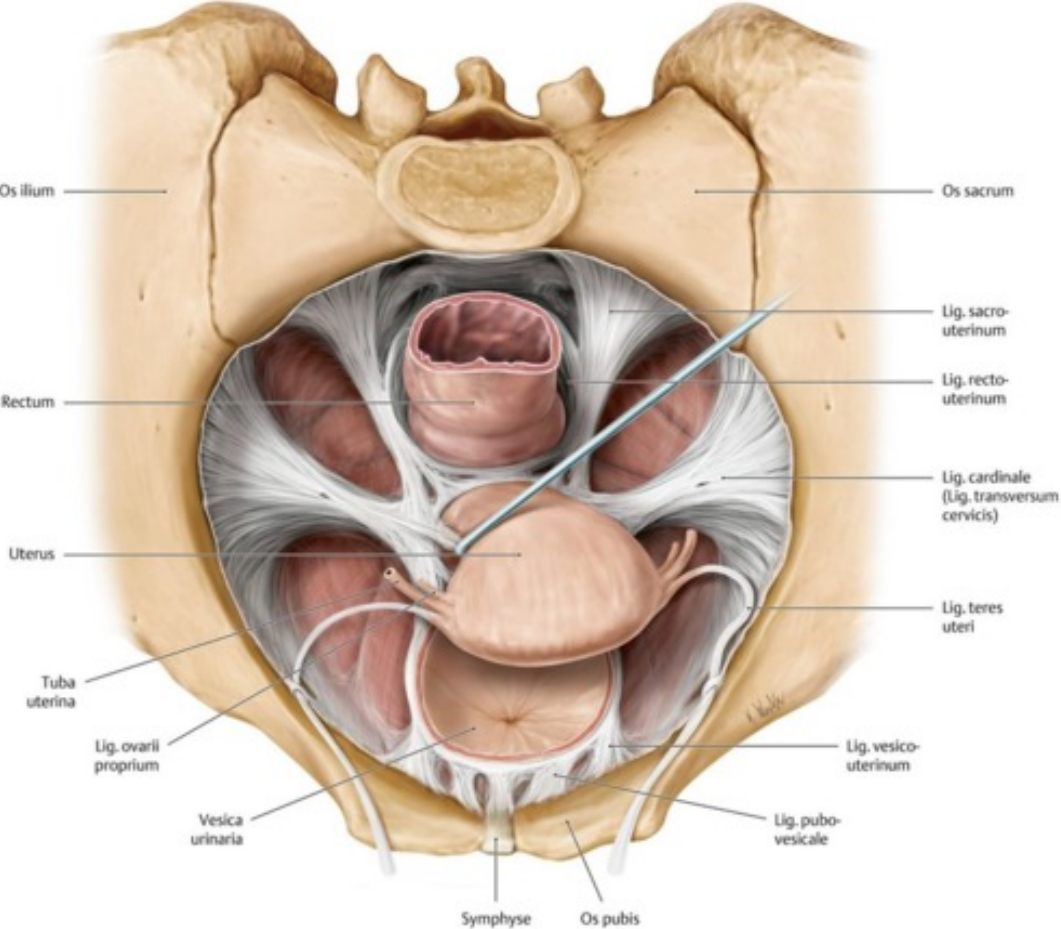


Complete prolapse
cross section

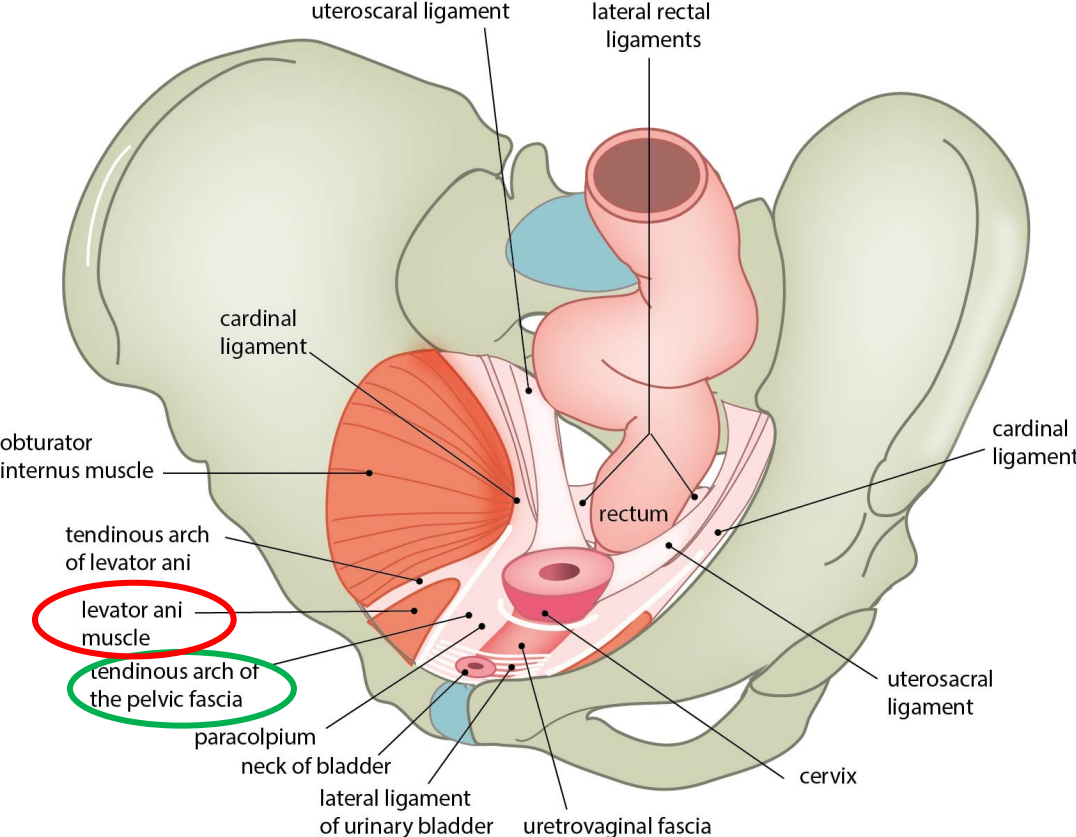
F. Netter

Závěsný aparát

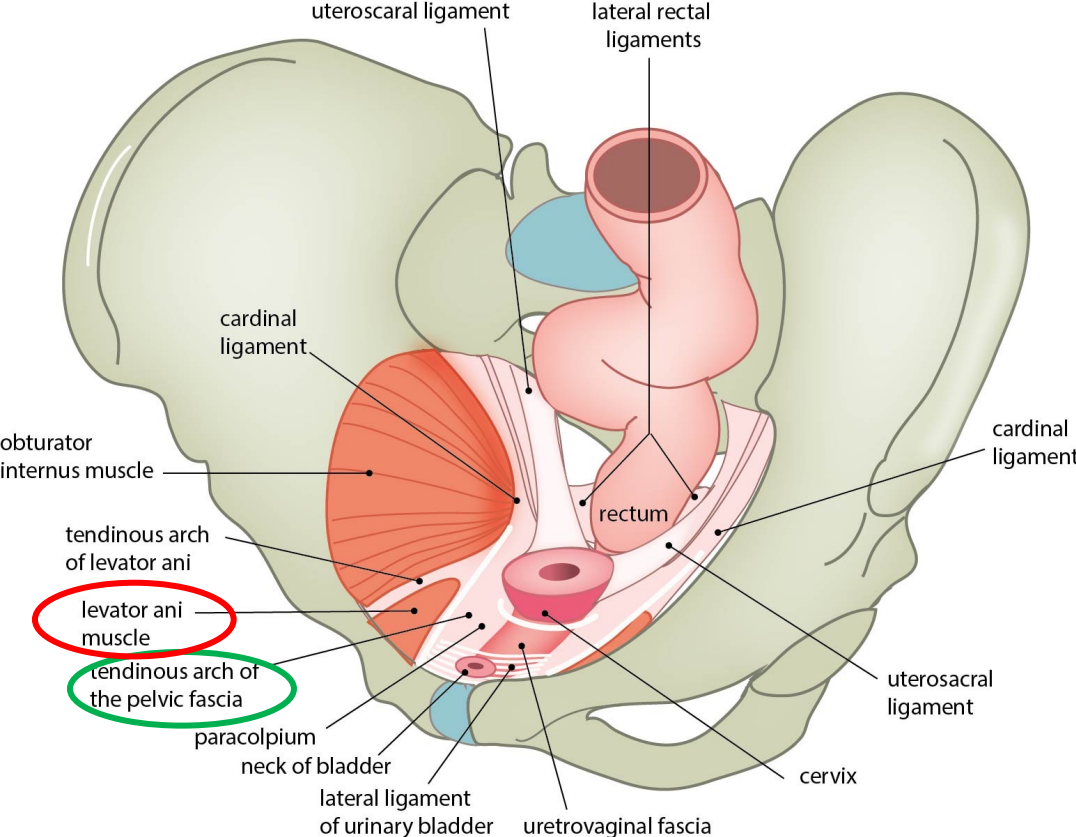
Level I



Level II

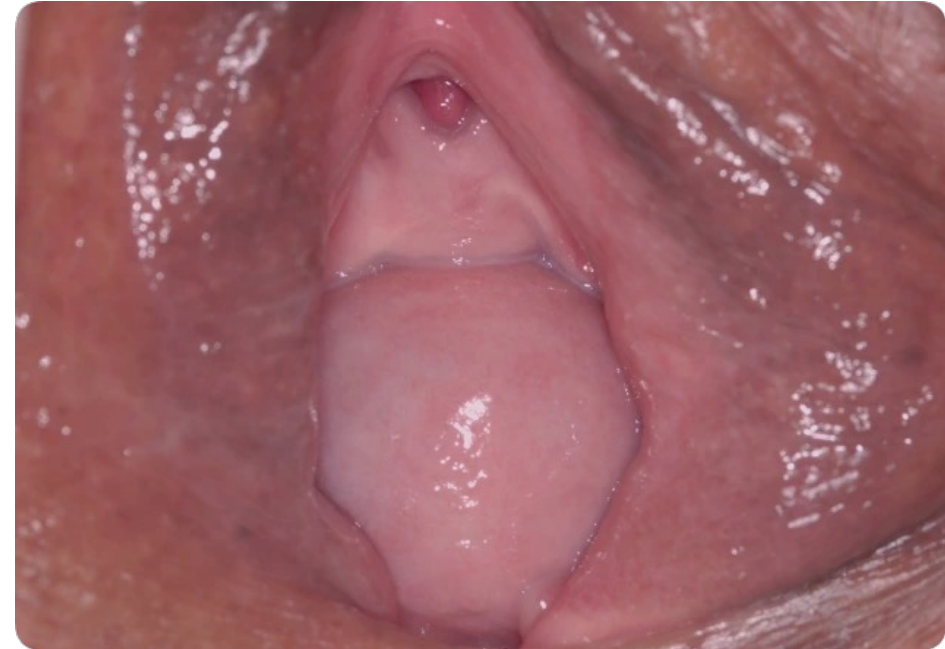

Level III



Symptomy

- Bulging
- Tlak v pánvi
- Krvácení, výtok, infekce
- Repozice
- Křížové bolesti



Terapie

Konzervativní

Životní styl

Režimová opatření

Hormony

Pesar

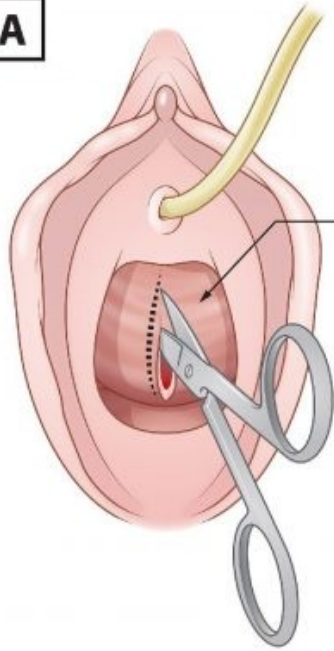
Rehabilitace

Chirurgická

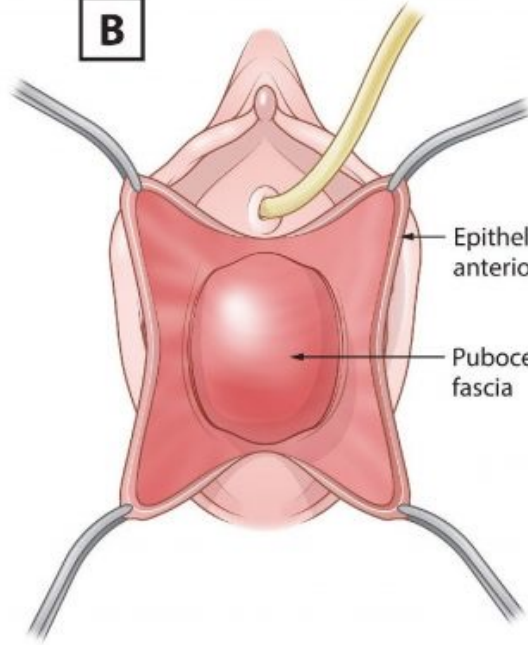
Rekonstrukční operace

Operace s použitím
implantátu

LSK sakrokolpopexe

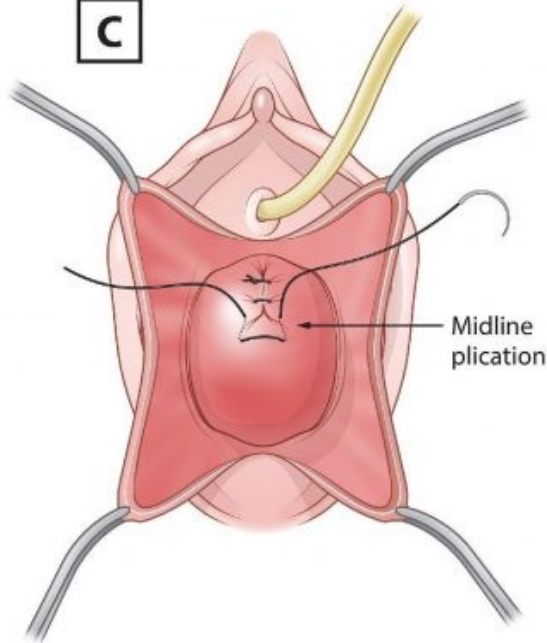
A

Anterior vaginal wall

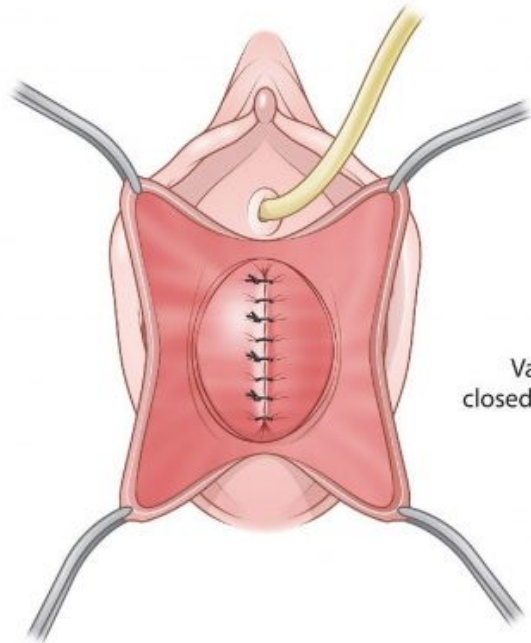
B

Epithelium of anterior vaginal wall

Pubocervical fascia

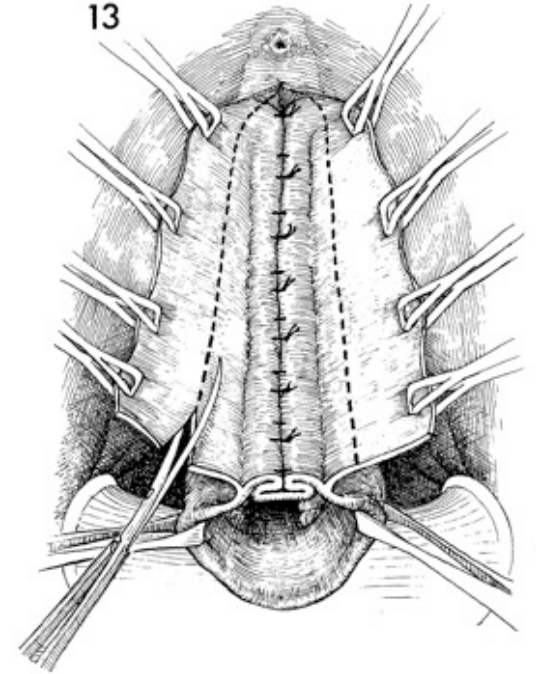
C

Midline plication

D

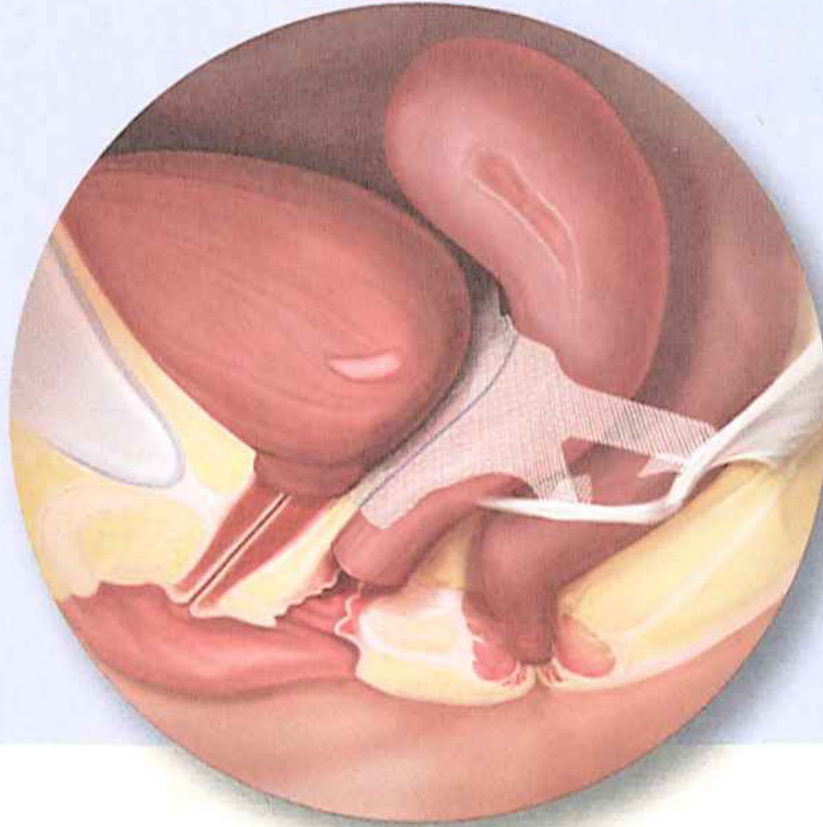
Vaginal epithelium closed with continuous mattress suture

13



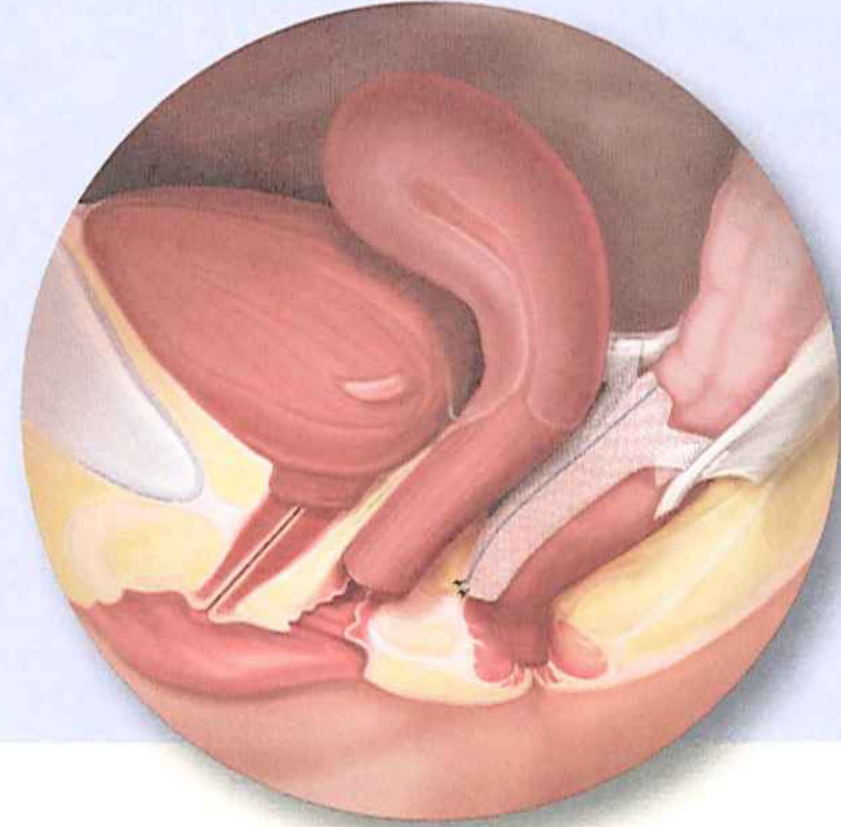
Pinnacle Pelvic Floor Repair Kits

Anterior /Apical



for reinforcement of the
vaginal wall near the bladder

Posterior



for reinforcement of the vaginal wall
near the rectum/intestines

