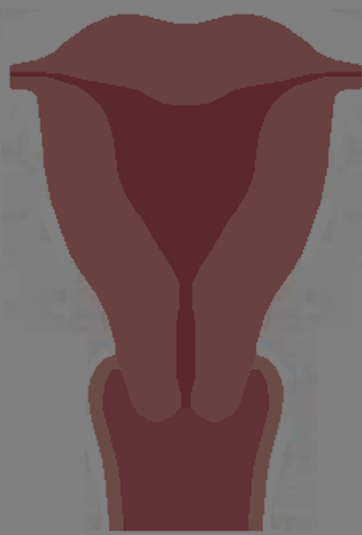



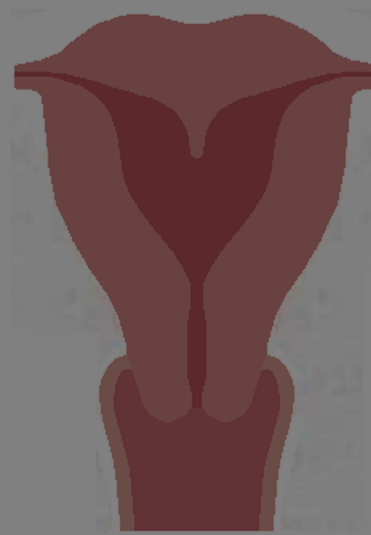uterus and vagina normally developed



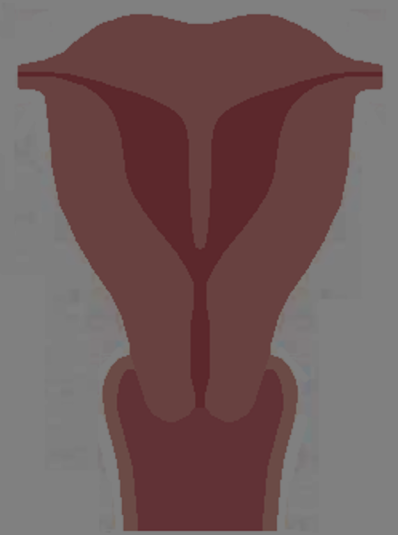vagina subseptum



arcuate uterus



uterus subseptum

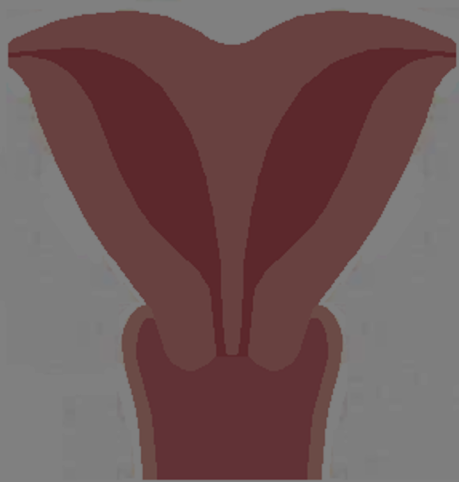

septated uterus

Vývojové poruchy rodidel



uterus bicornis



uterus bicornis



uterus didelphys



asymmetrical

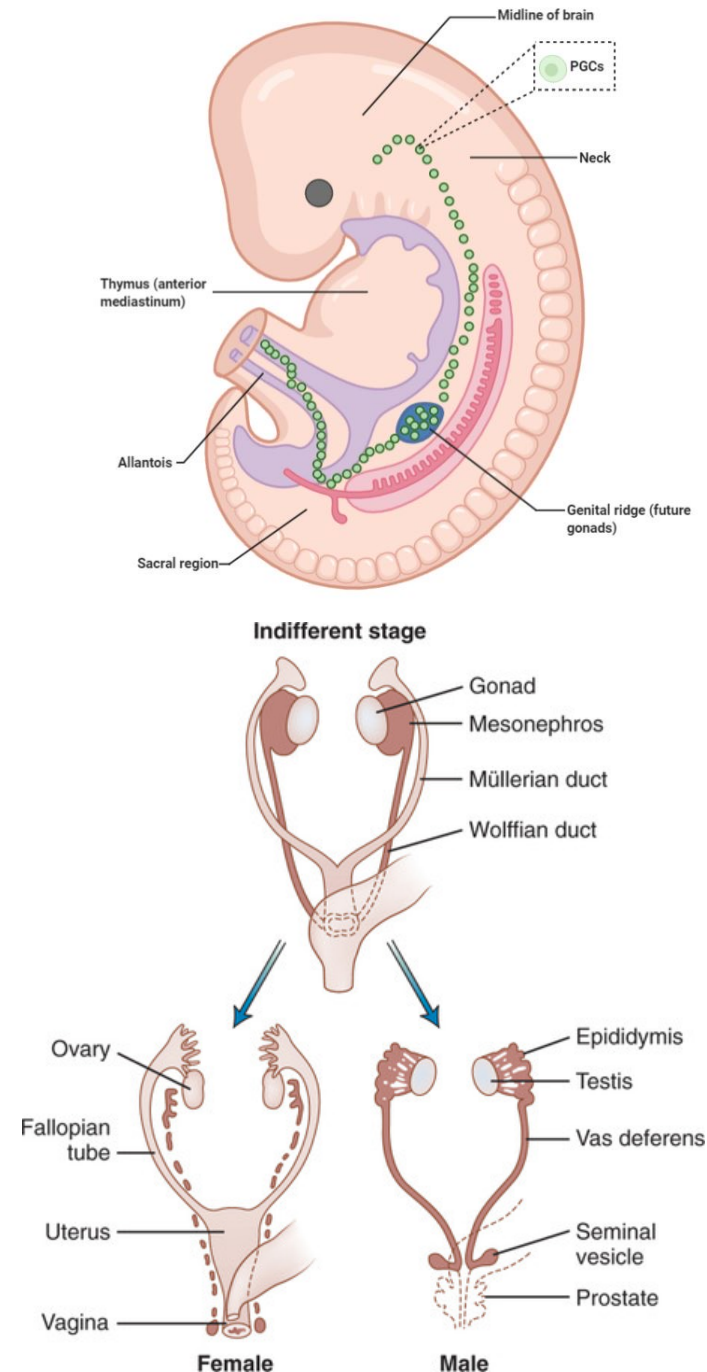


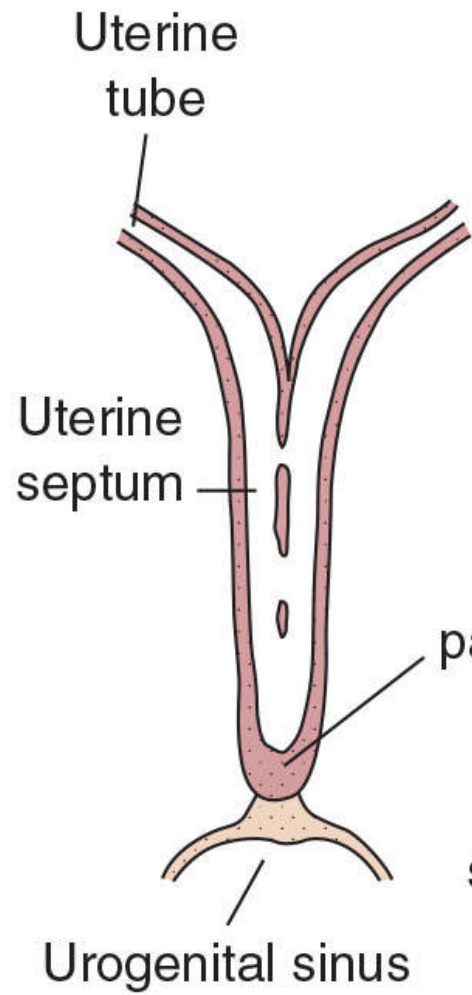
unicornuate

Lenka Krobová

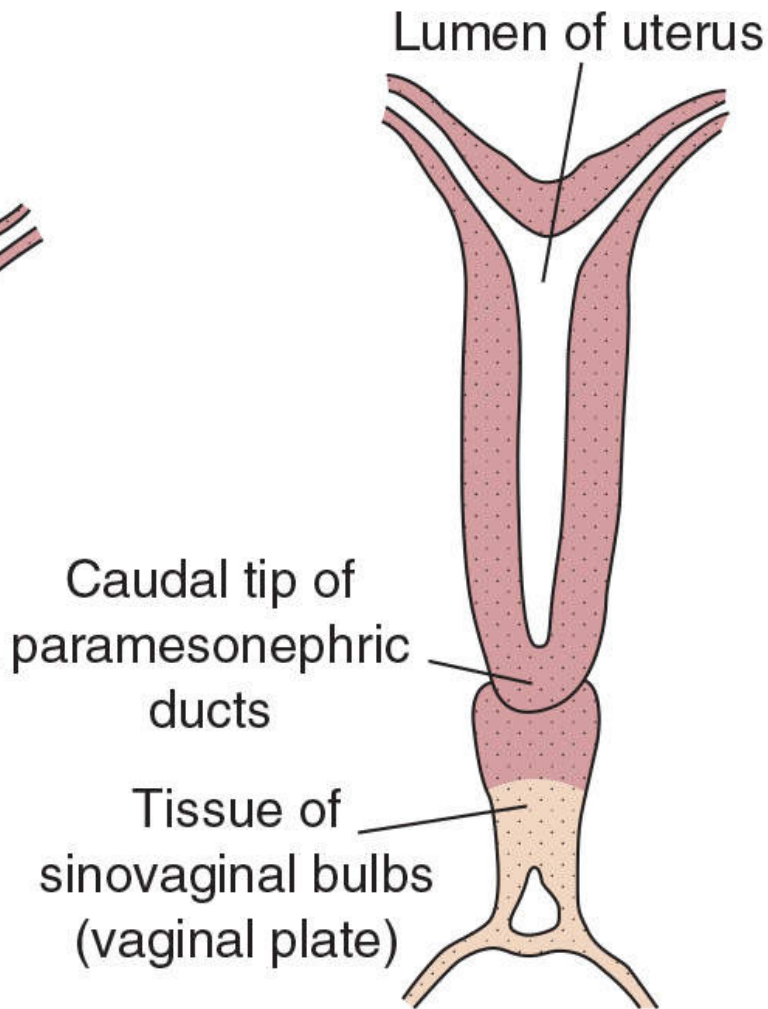
Vývoj pohlavního systému

- SRY (*sex-determining region on Y*)
- Wollfův a Müllerův vývod
- Uterovaginální kanál
- Spojení se sinus urogenitalis

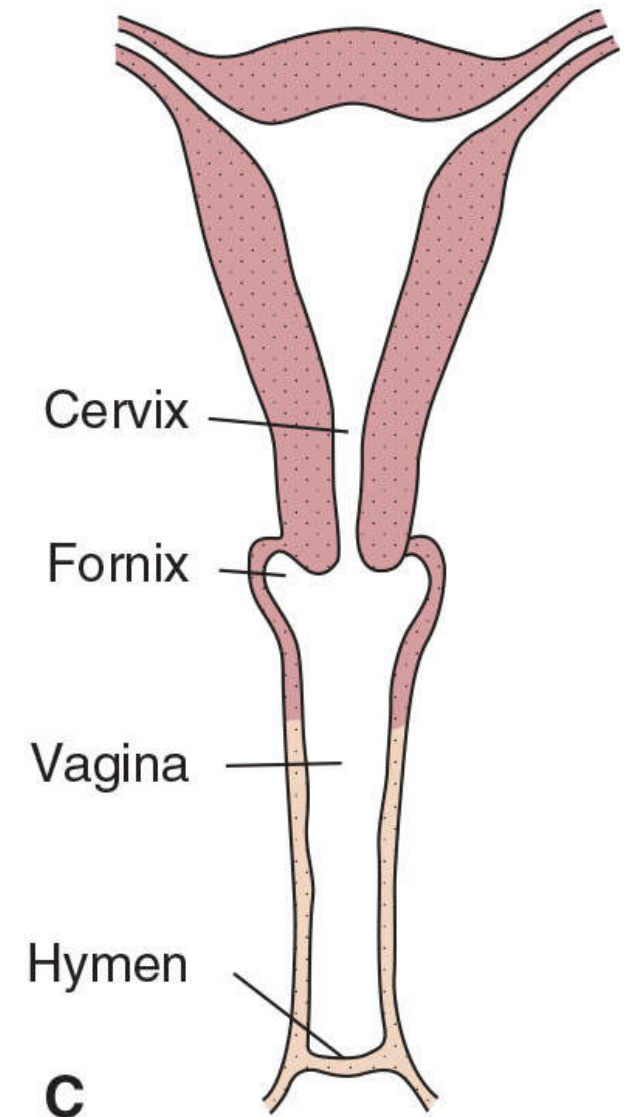




A



B



C

Ageneze a dysgeneze

Intersexuální malformace

Poruchy vývodů

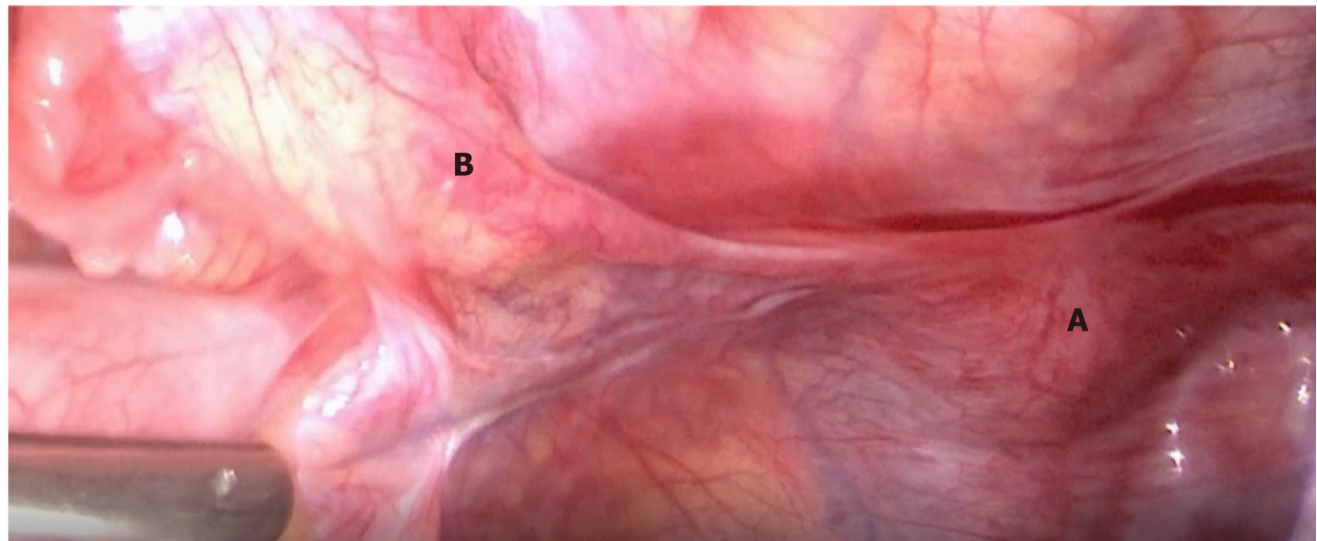
Sdružené vady

Ageneze a dysgeneze gonád

Ageneze – gonády nejsou vytvořeny

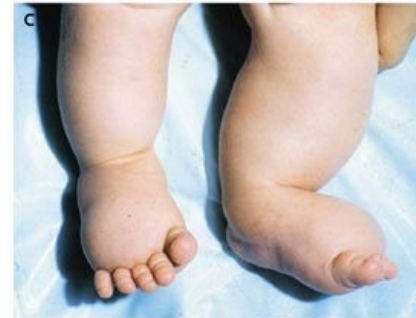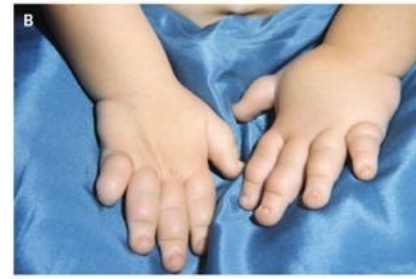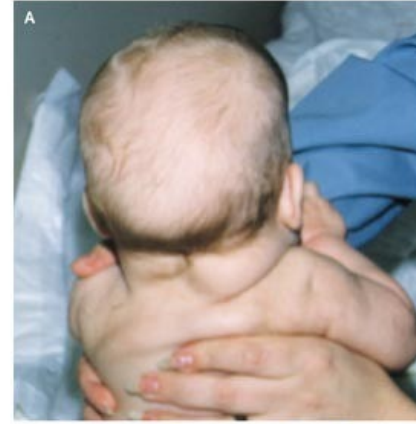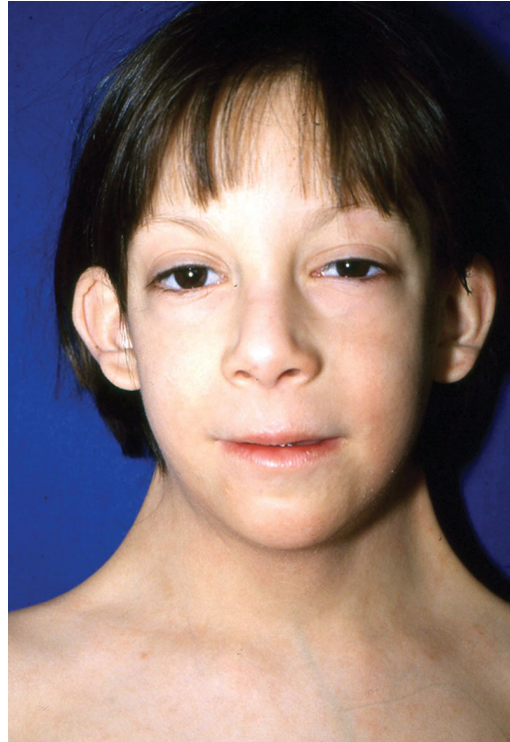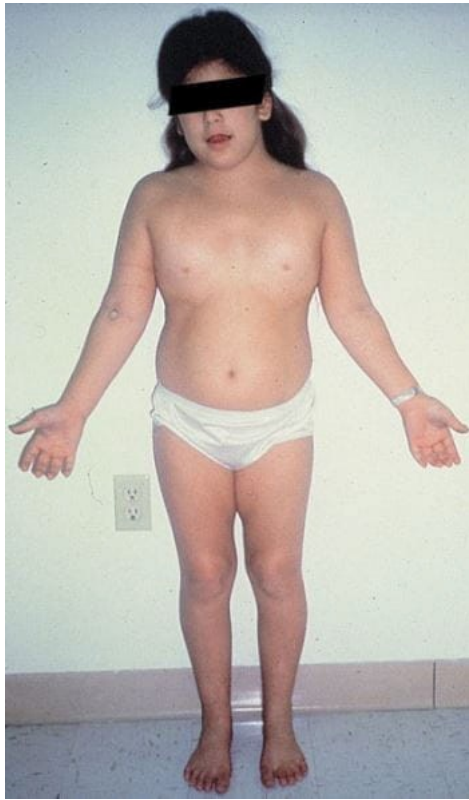Dysgeneze – vazivové proužky

- nejsou folikuly → není hormonální produkce



46 XX

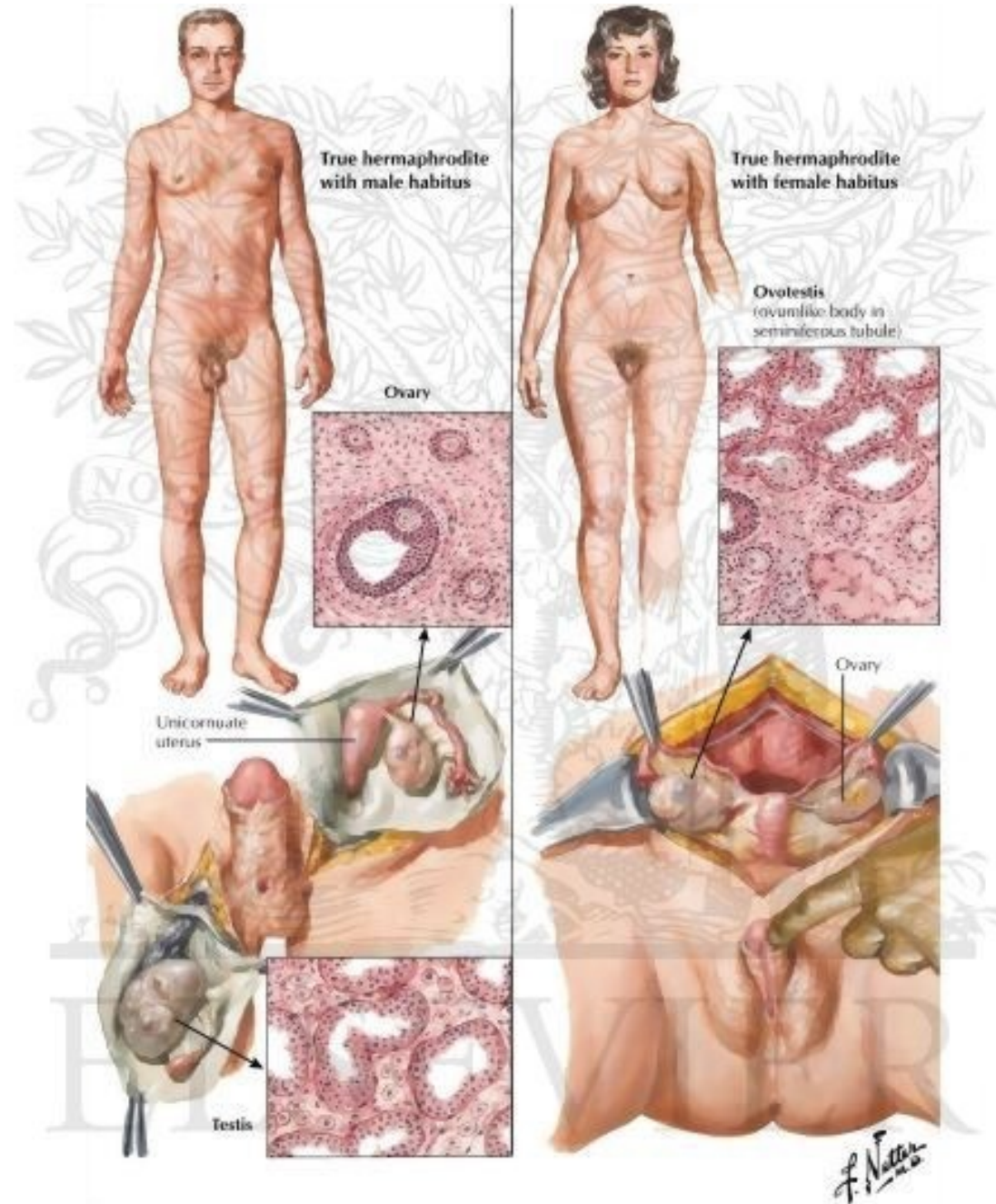
45 X – Turnerův syndrom



Intersexuální malformace

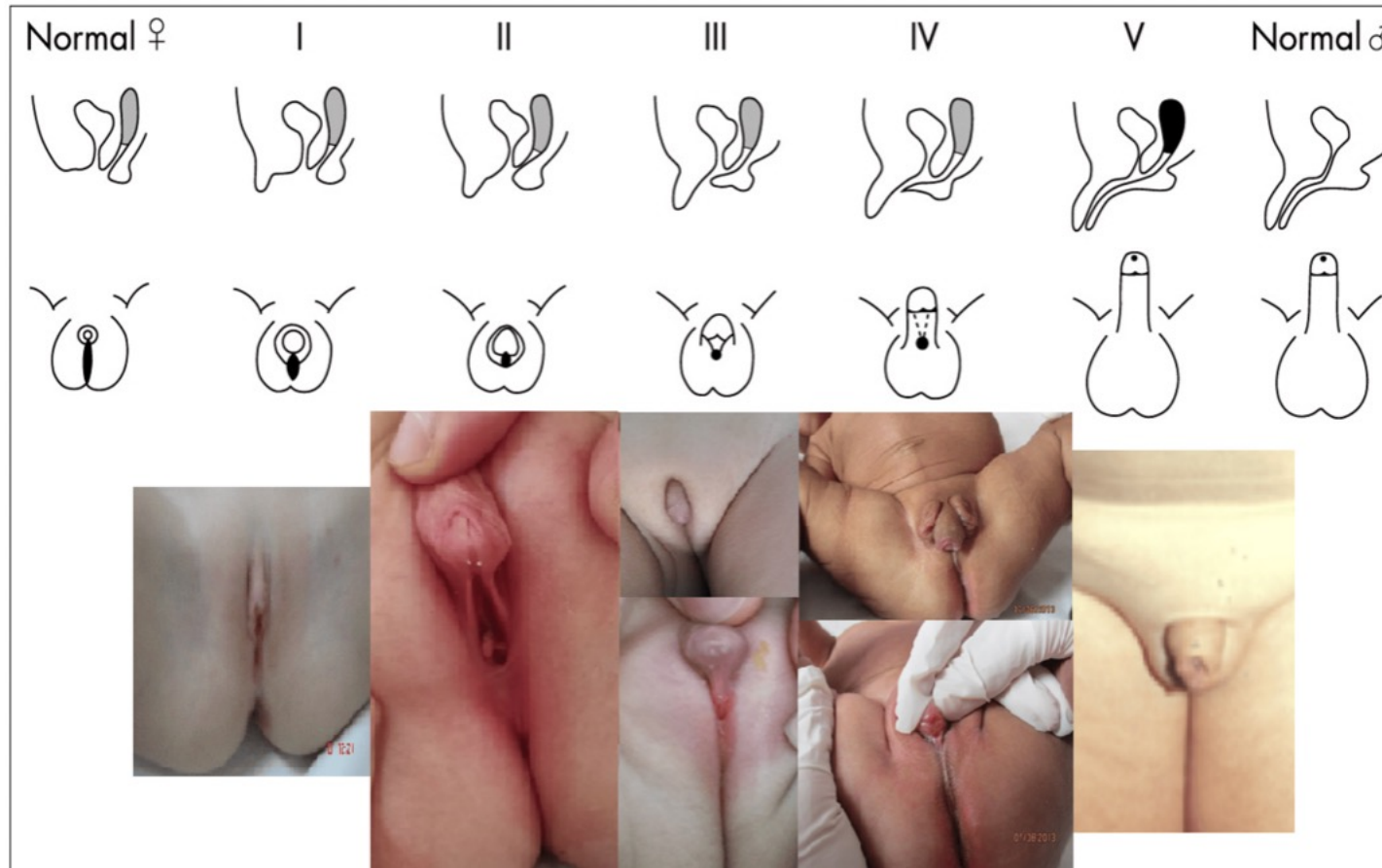
Hermaphroditismus verus

- Ovaria i testes, ev. ovotestis
- Velmi vzácný



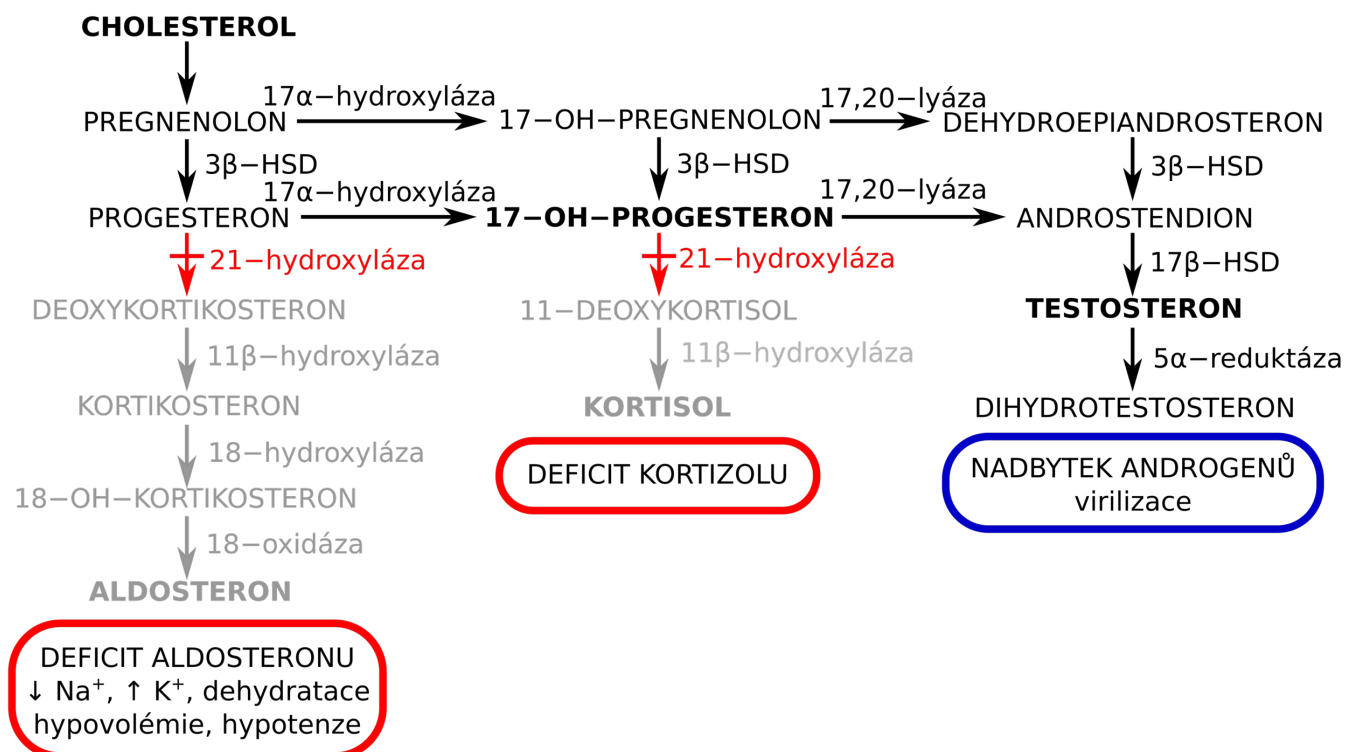
Pseudohermaphroditismus femininus u CAH

- 46 XX
- Distální úsek pochvy zužený, vnitřní pohl. orgány normální
- Nejčastěji – peniformní klitoris, skrotiformní labia



Kongenitální adrenální hyperplázie

- AR
- Defekt enzymů → porucha syntézy hormonů (nejč. 21-hydroxyláza)



Klasická forma

Se solnou poruchou

- Dívky – virilizace, solná krize, smrt

Prostá virilizující

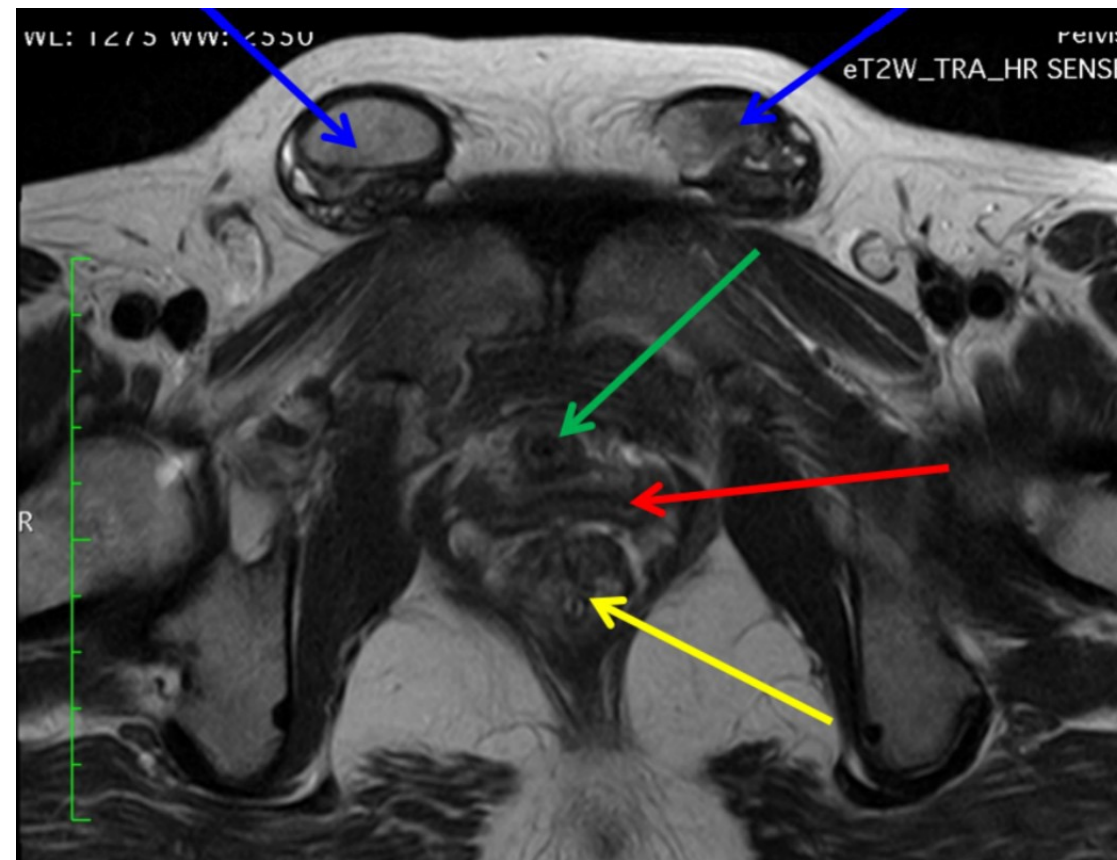
- 1% aktivity
- Dívky – virilizace, pseudopubertas praecox heterosexualis, nízká finální výška

Late-onset forma

- 20-50% aktivity
- Virilizace dívek, poruchy cyklu

Pseudohermaphroditismus masculinus – syndrom testikulární feminizace

- 46, XY
- Ženská zevní rodidla
- Produkce MIF → nejsou vnitřní rodidla



Poruchy Müllerových vývodů

Poruchy průchodnosti - GYNATRÉZIE

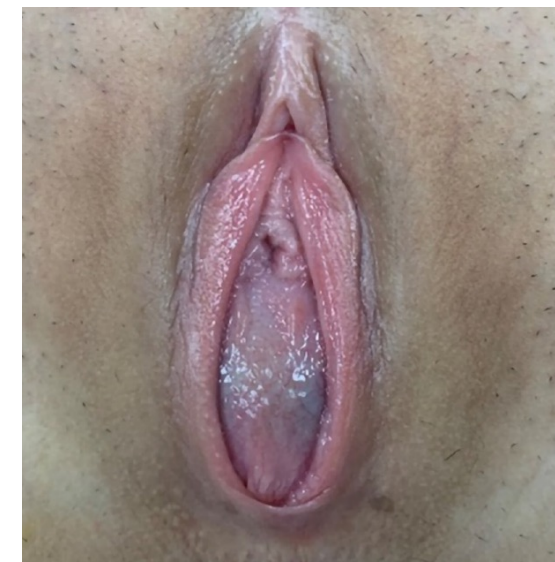
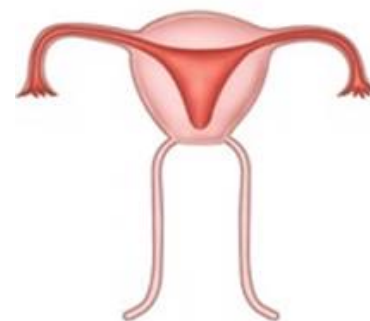
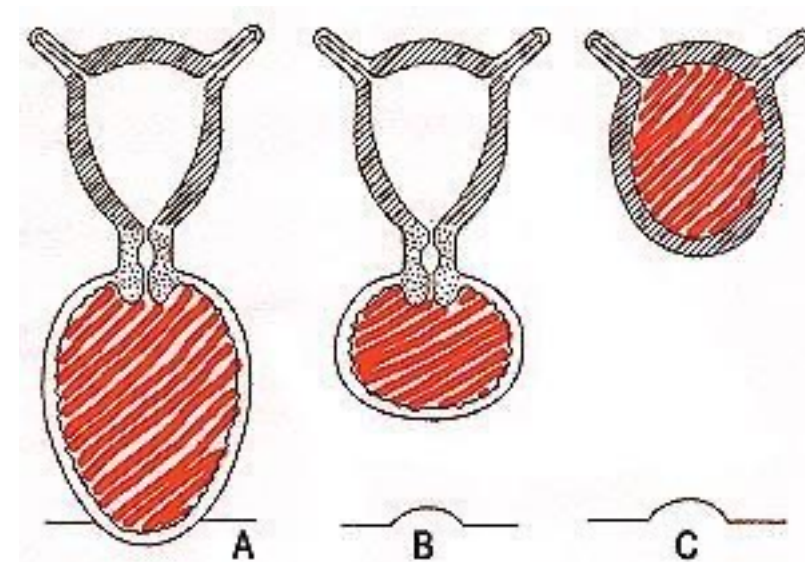
Atresia hymenalis

- Mucocolpos
- Hematocolpos až hemoperitoneum

Aplasia partis distalis vaginae

Atresia cervicis uteri

Aplasia vaginae

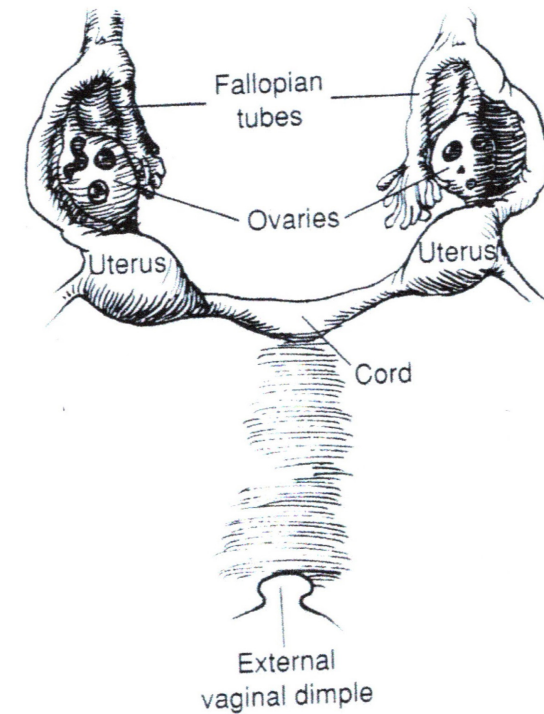
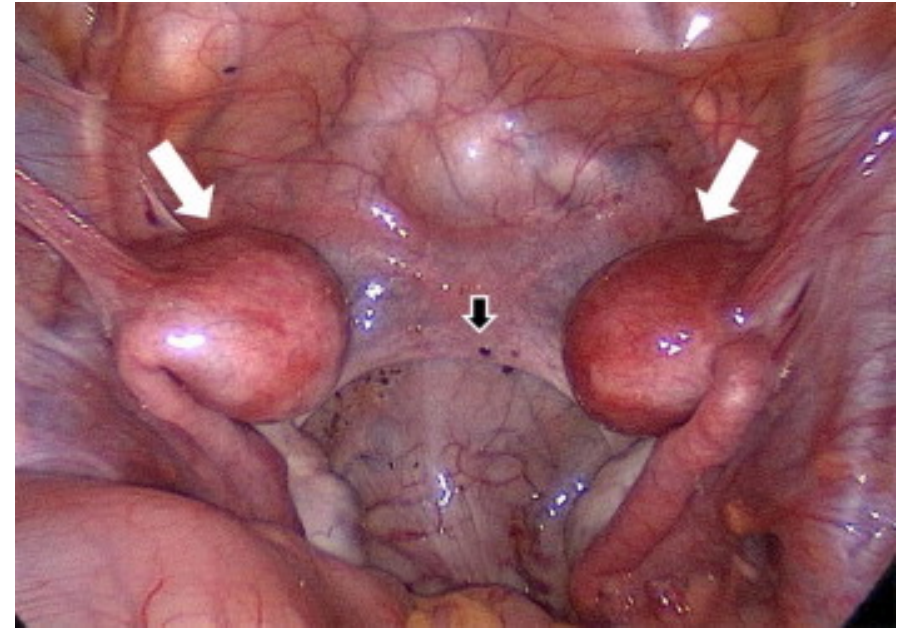


Atrézie = neprůchodnost
Aplázie = nevyvinutí

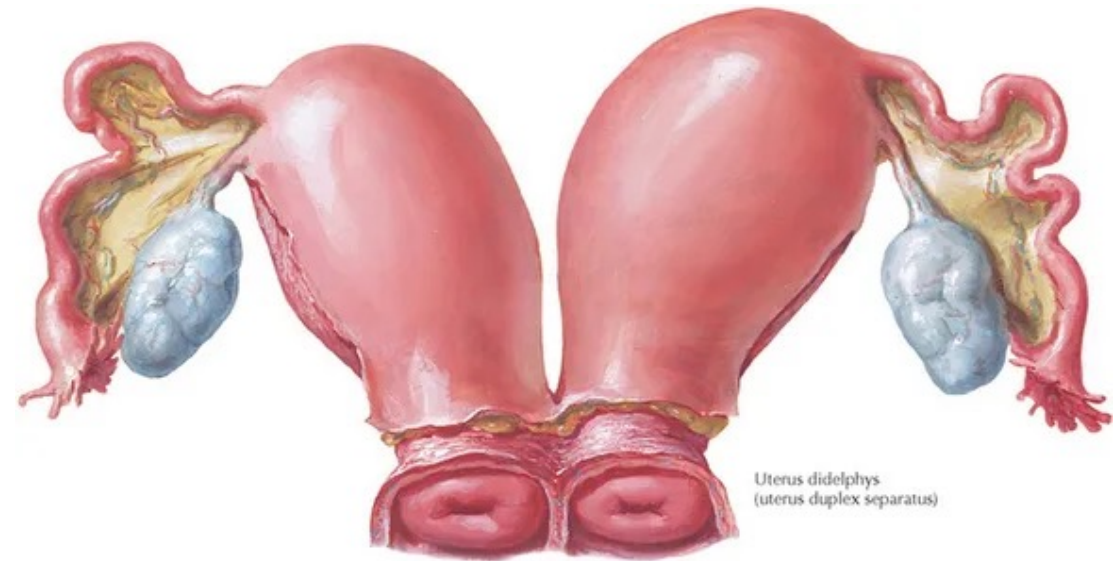
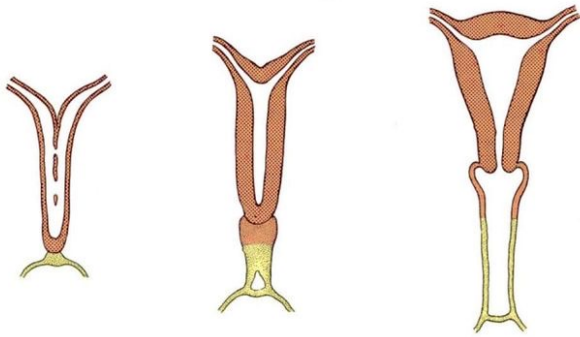
Syndrom Rokitanského-Küsterův

- Úplná aplázie dělohy a pochvy

operace



Poruchy splývání

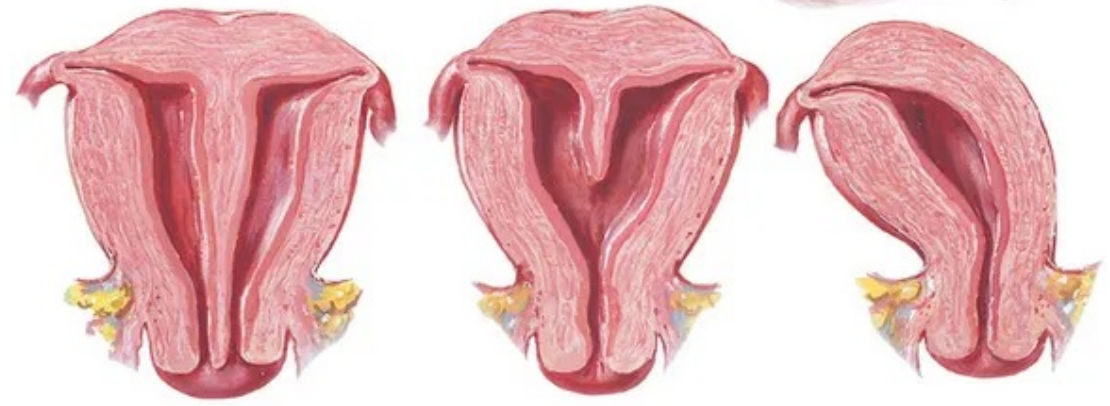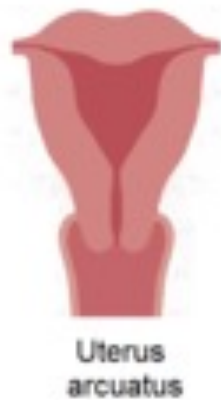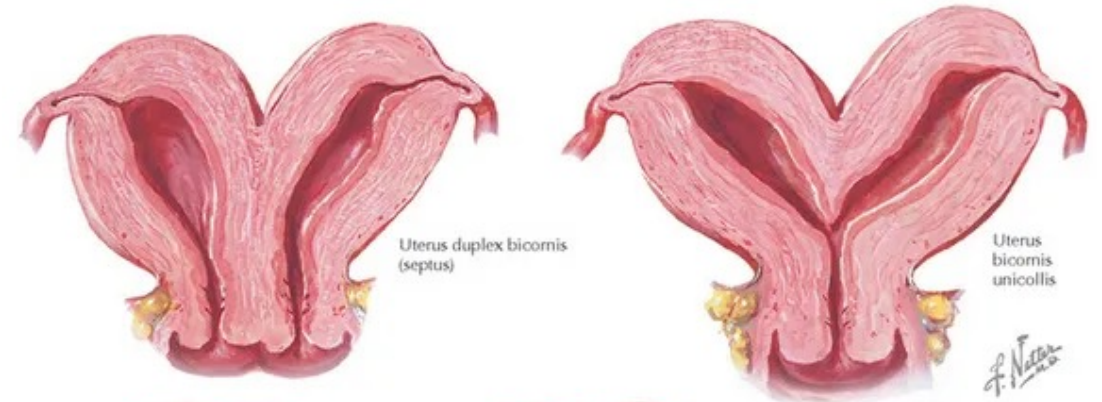


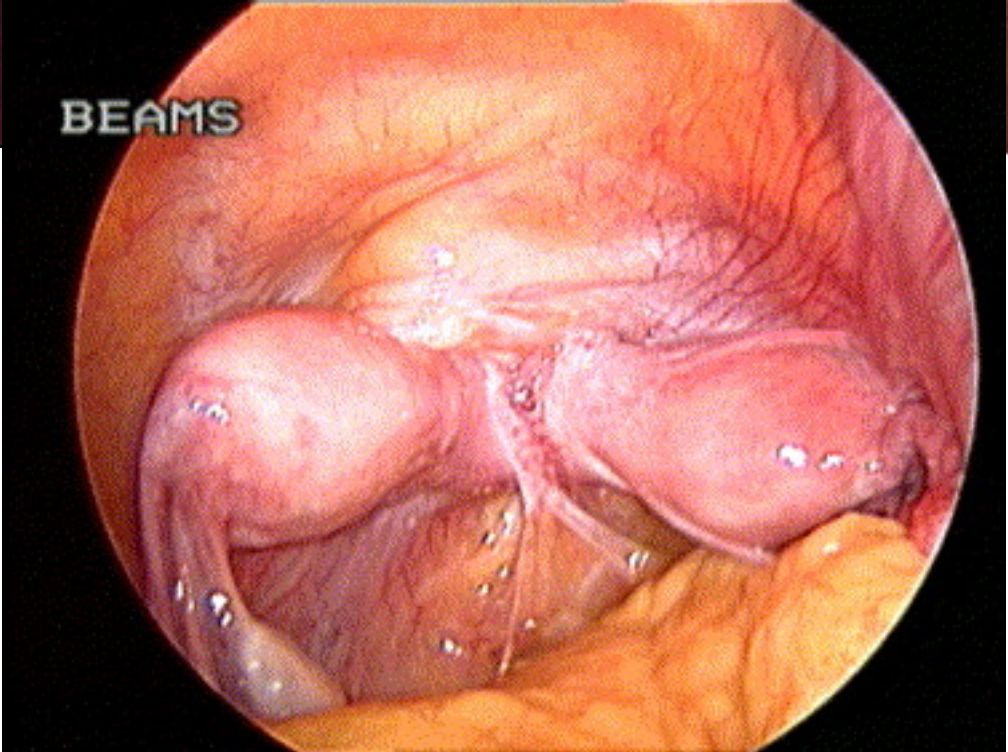
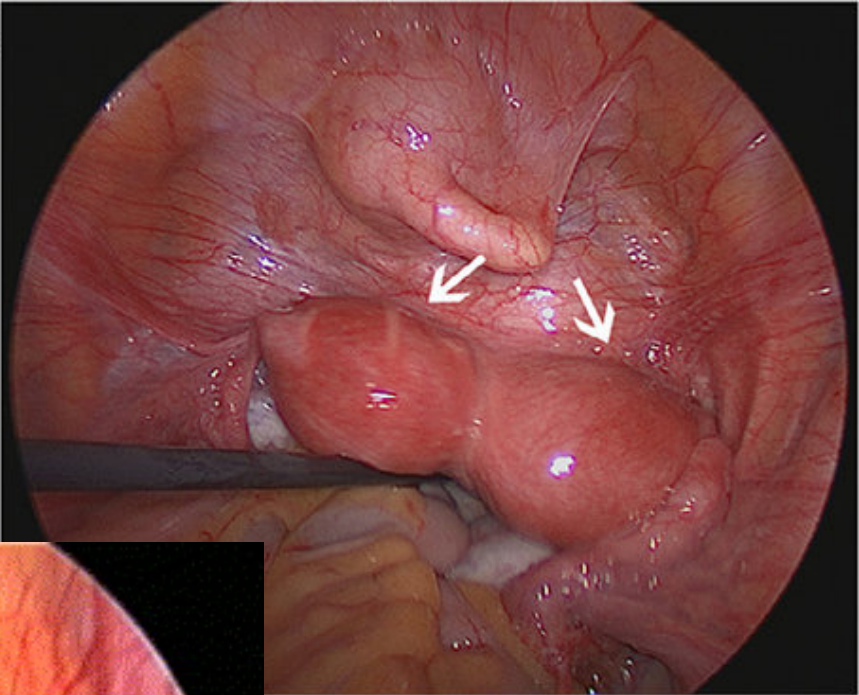
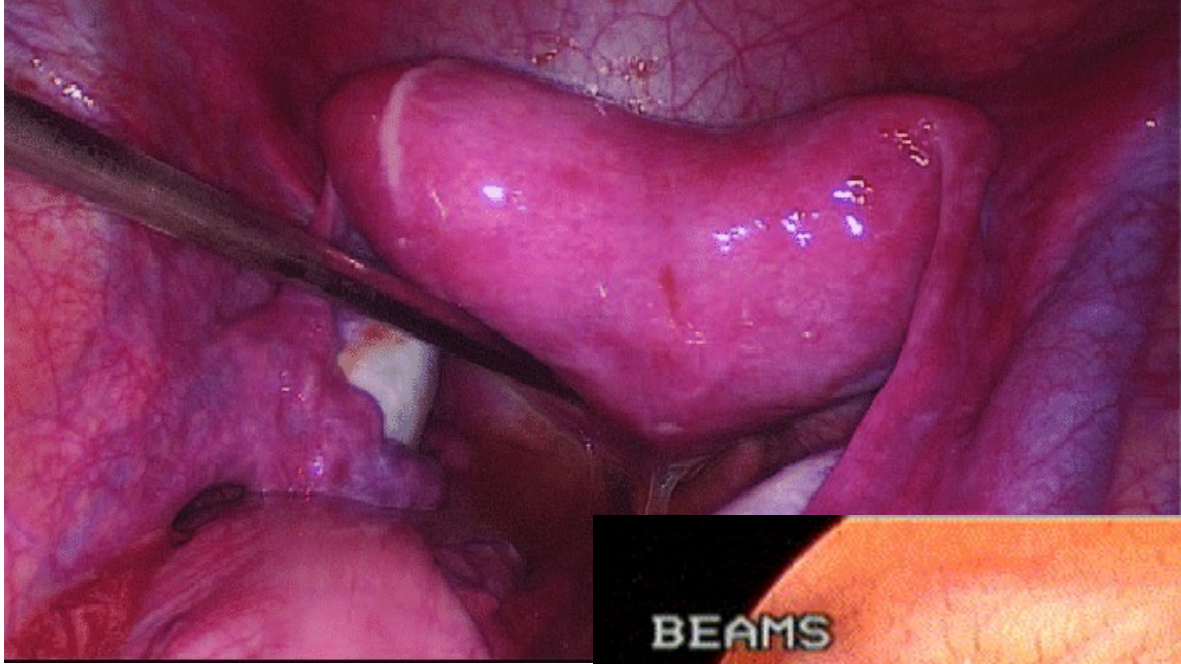
Jednoplášťové

- Zvenku jednotná, abnormalita uvnitř

Dvouplášťové

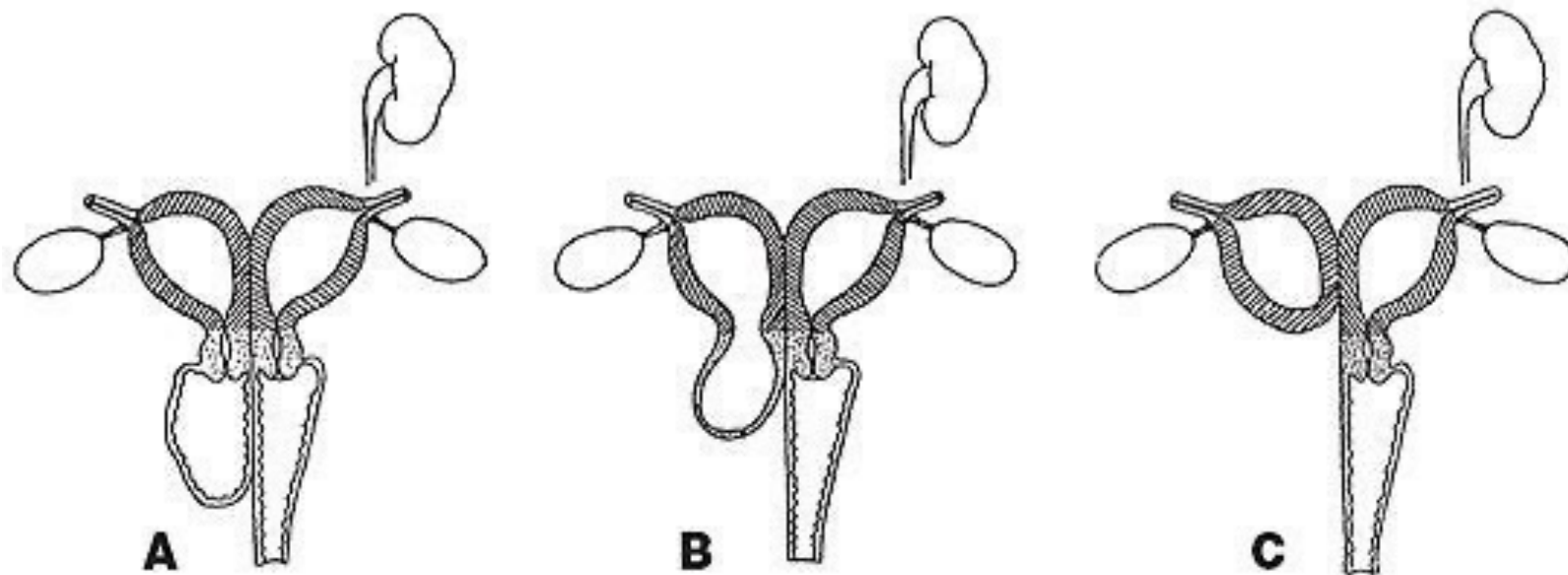
- Abnormalita patrna i zevně



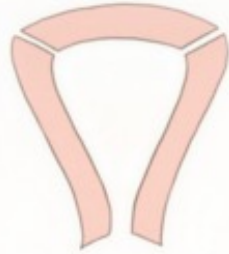

Kombinované poruchy – syndrom inkompletního zdvojení

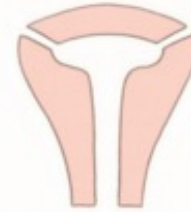- Nesplynutí Müllerových vývodů a nespojení s kloakální výchlípkou
- Vždy aplázie ledviny a ureteru ipsilaterálně



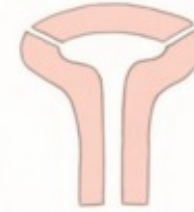Class U0/Normal Uterus



Class U1/Dysmorphic Uterus

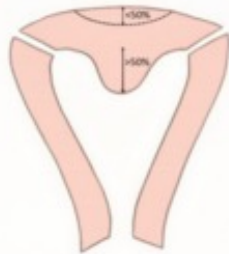


a. T-shaped

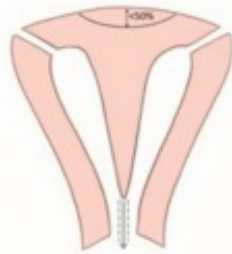

b. Infantilis

Class U2/Septate Uterus

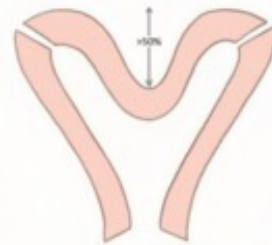


a. Partial

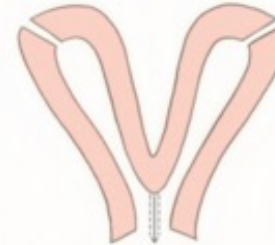

b. Complete

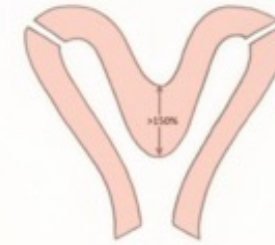
Class U3/Bicorporeal Uterus



a. Partial

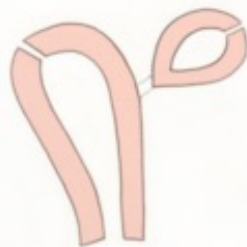

b. Complete

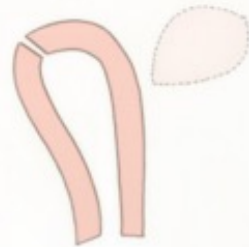


c. Bicorporeal Septate

Class U4/Hemi Uterus

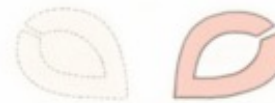

a. With rudimentary cavity



b. Without rudimentary cavity

Class U5/Aplastic Uterus



a. With rudimentary cavity

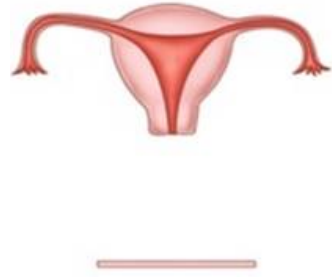


b. Without rudimentary cavity

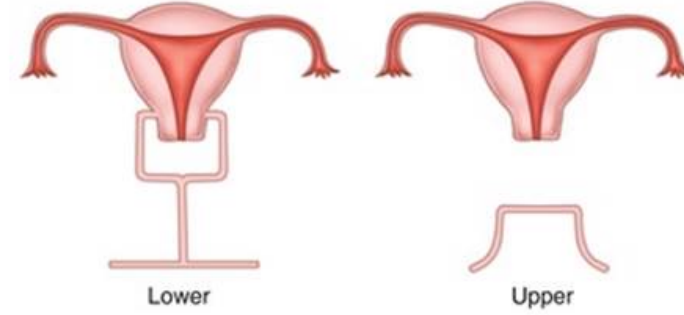
Class U6/Unclassified Cases

a

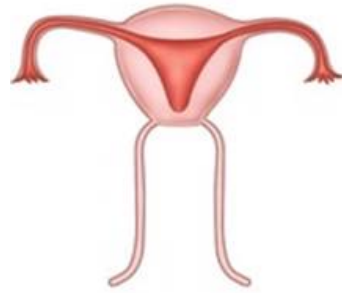1. Vaginal aplasia : Complete



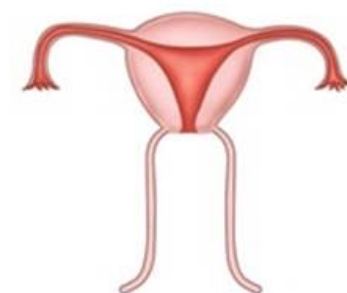
2. Vaginal aplasia : Partial



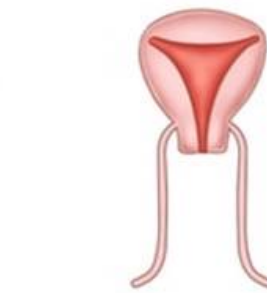3. Cervical aplasia



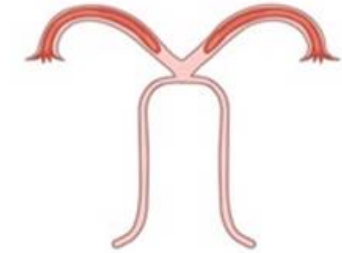
4. Cervical hypoplasia



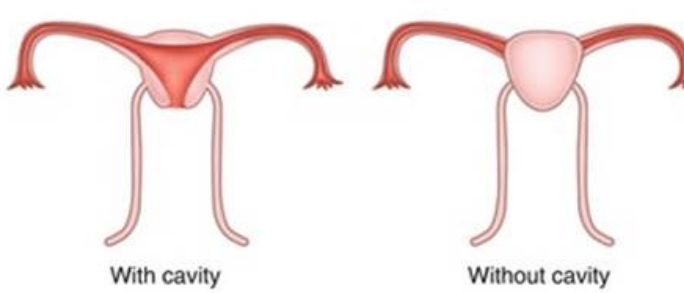
5. Tubal aplasia



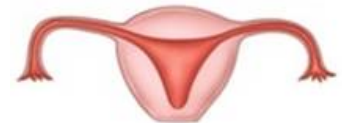6. Uterine aplasia



7. Uterine hypoplasia



8. Combined: commonest findings
Cervico-vaginal agenesis



Cervico-utero-vaginal agenesis
(Rokitansky syndrome)



Sdružené vývojové vady

U pseudohermaphroditismu:

Hypospadie

Epispadie

