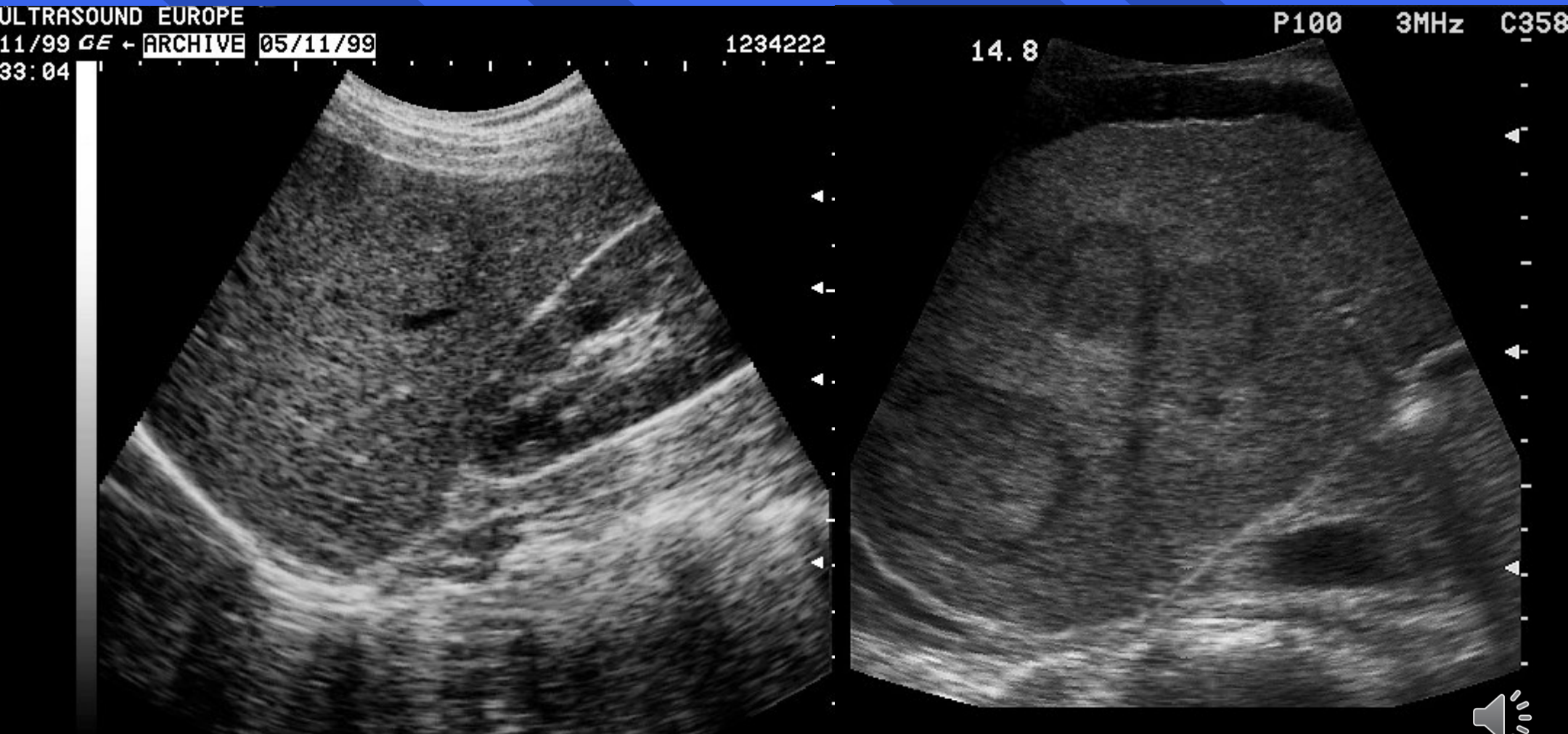
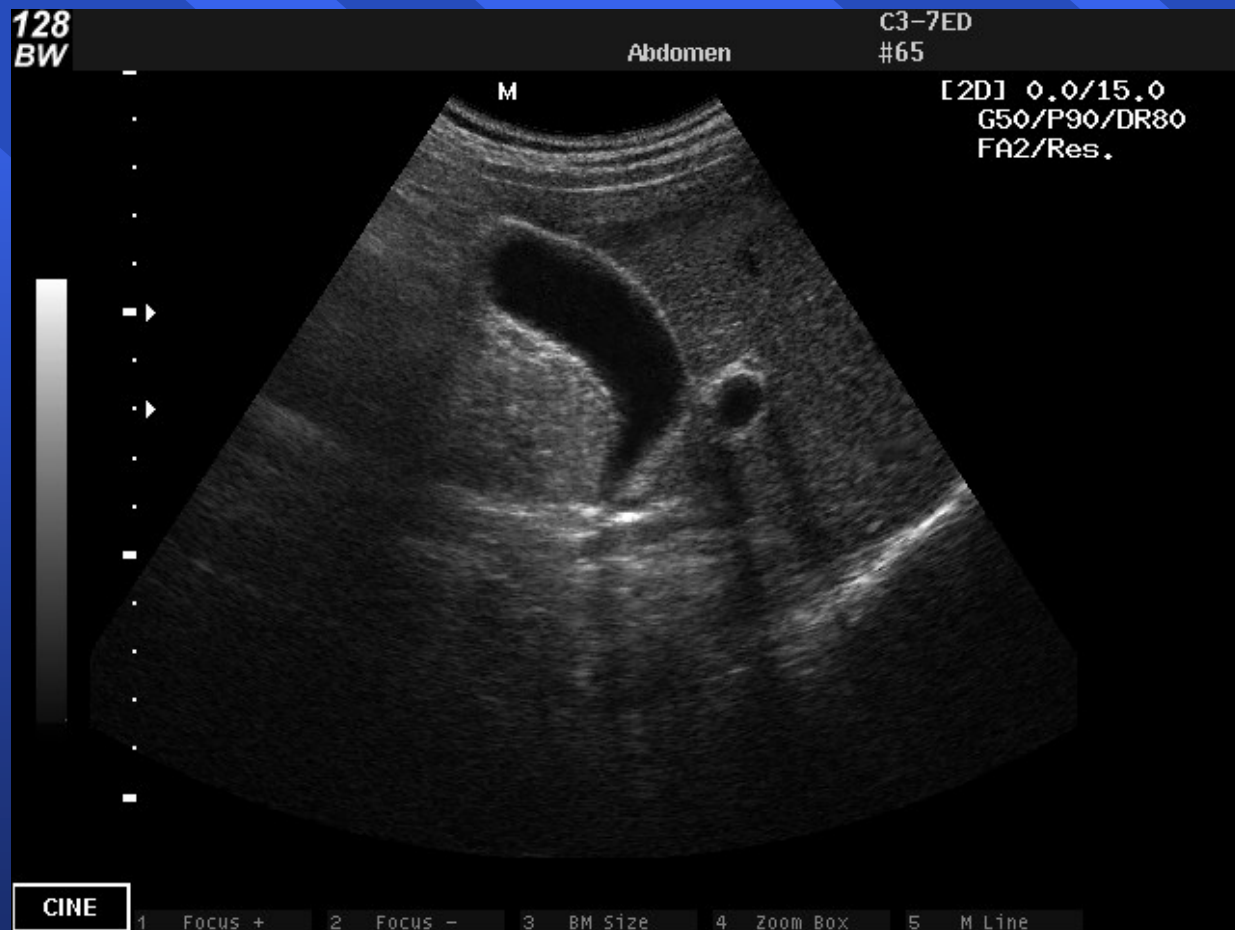

Obraz jater a ledviny (vlevo) a meta do jater (vpravo)

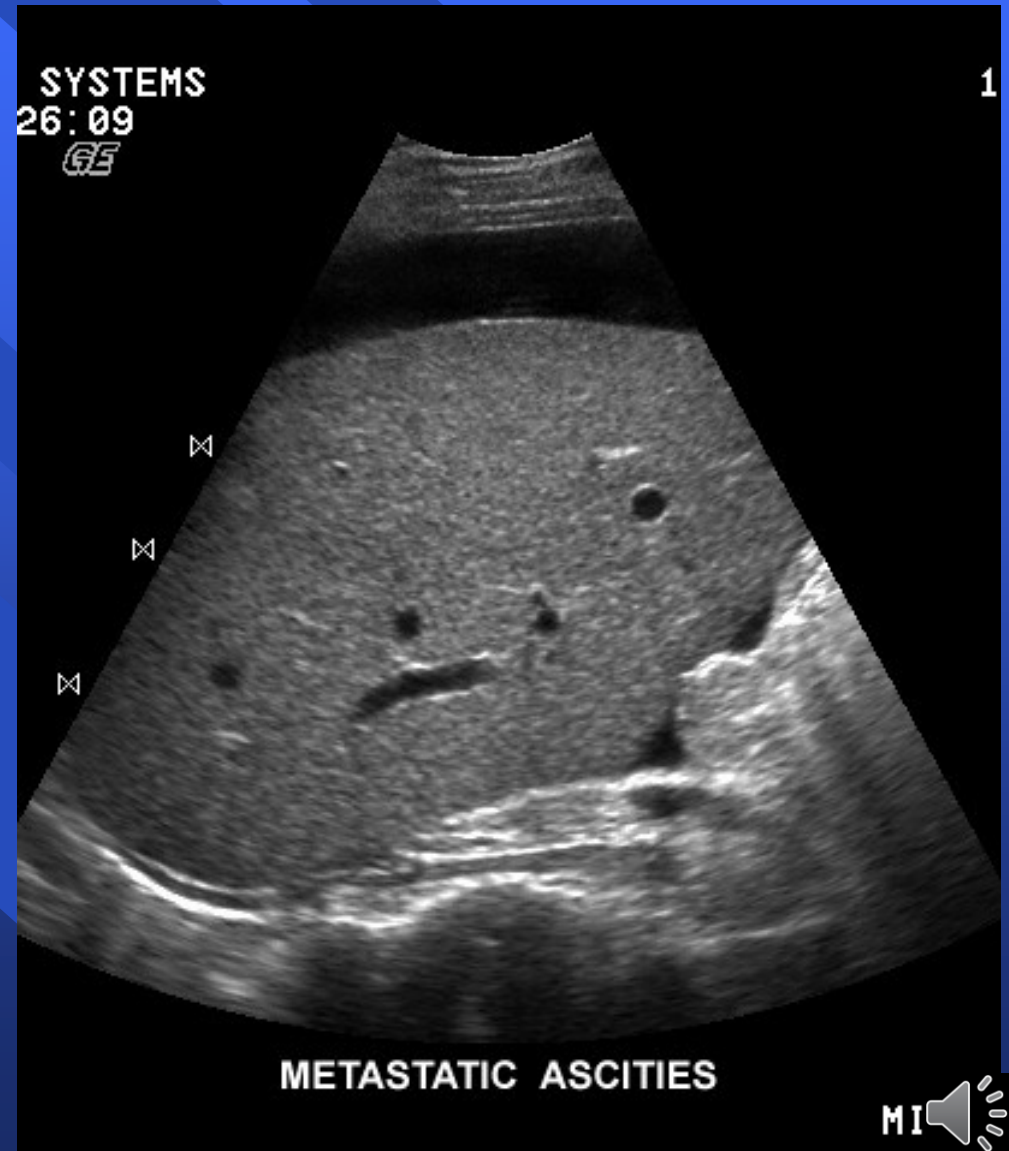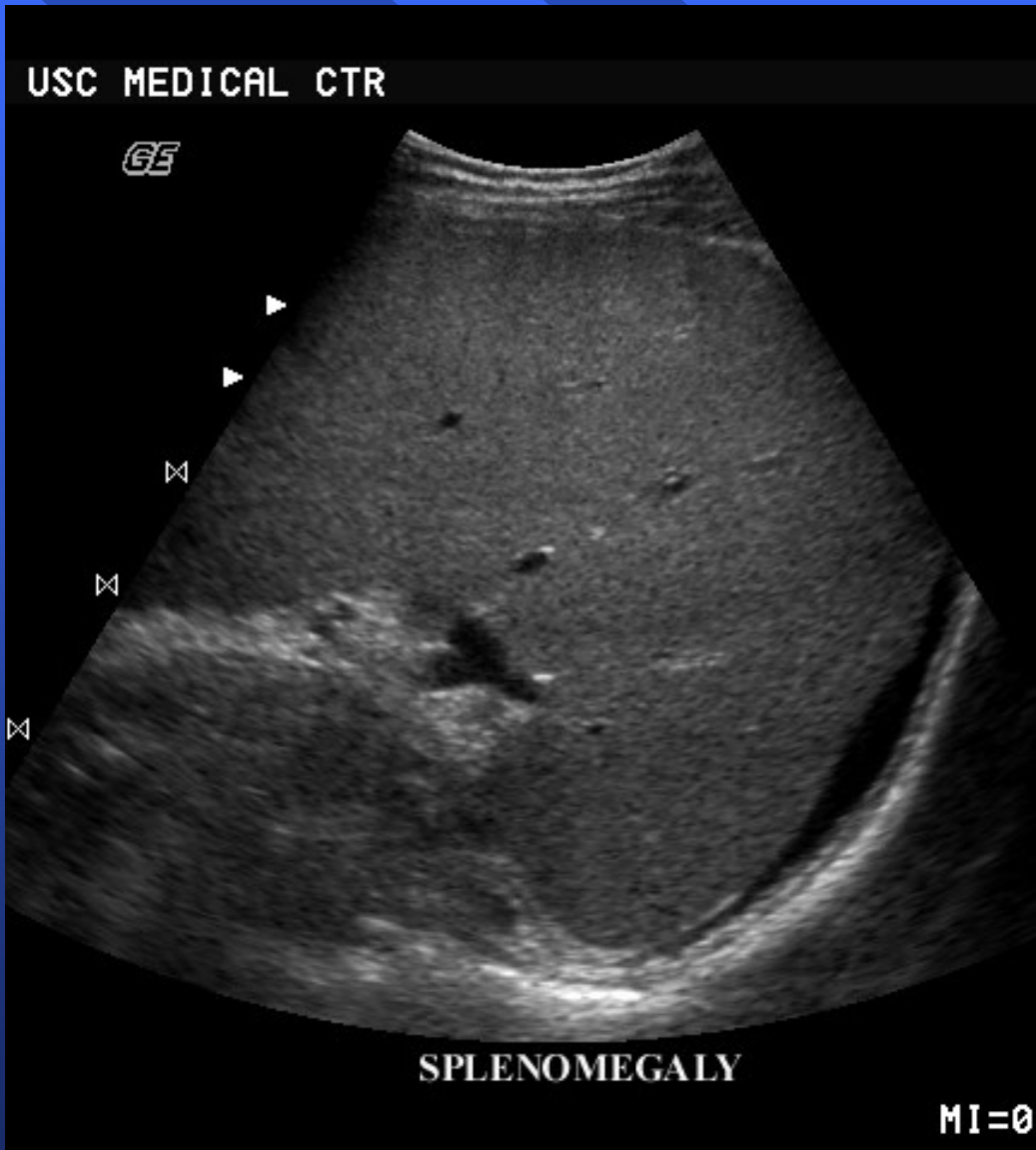


Obraz normálního žlučníku

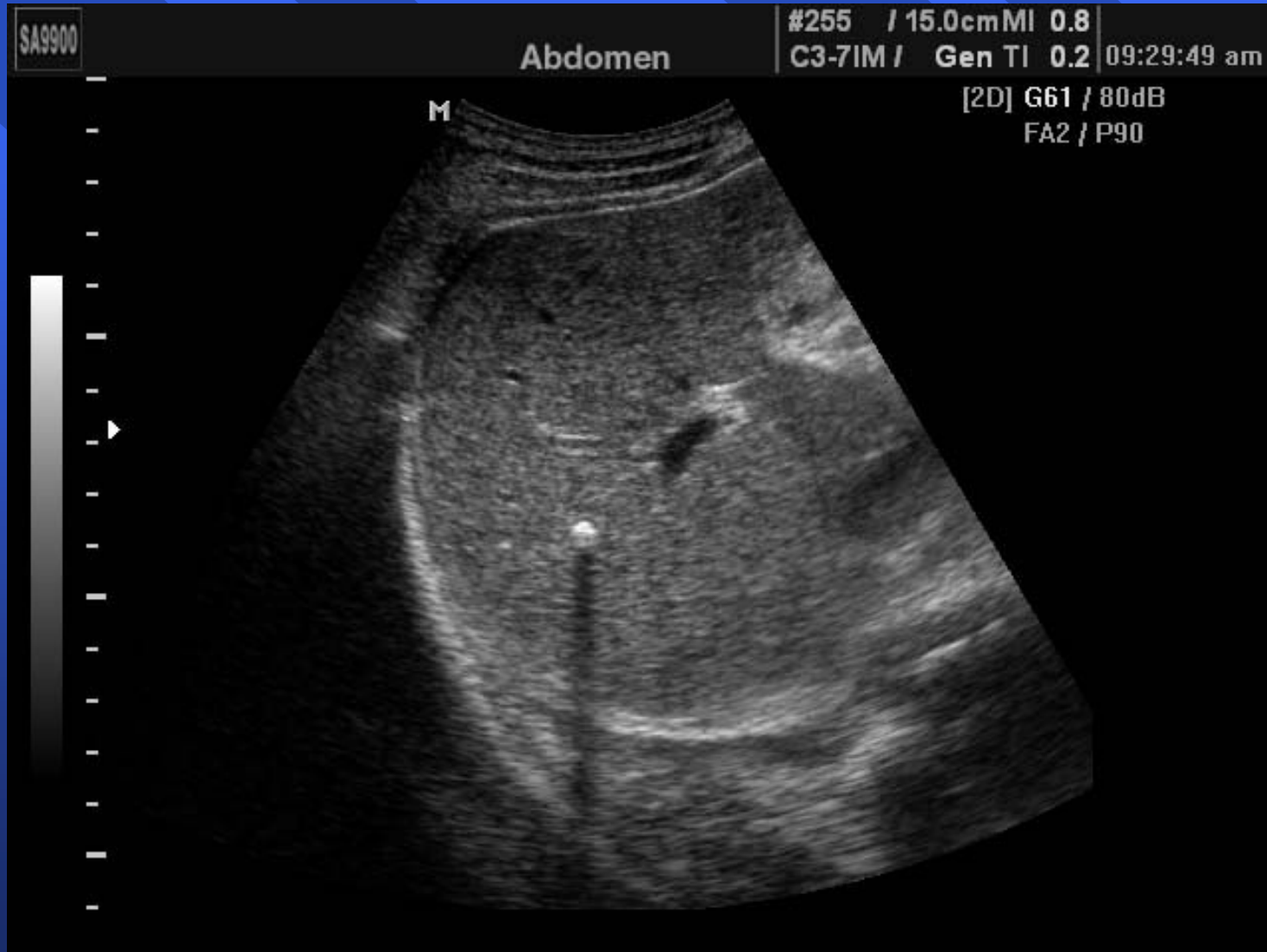

Splenomegalie a

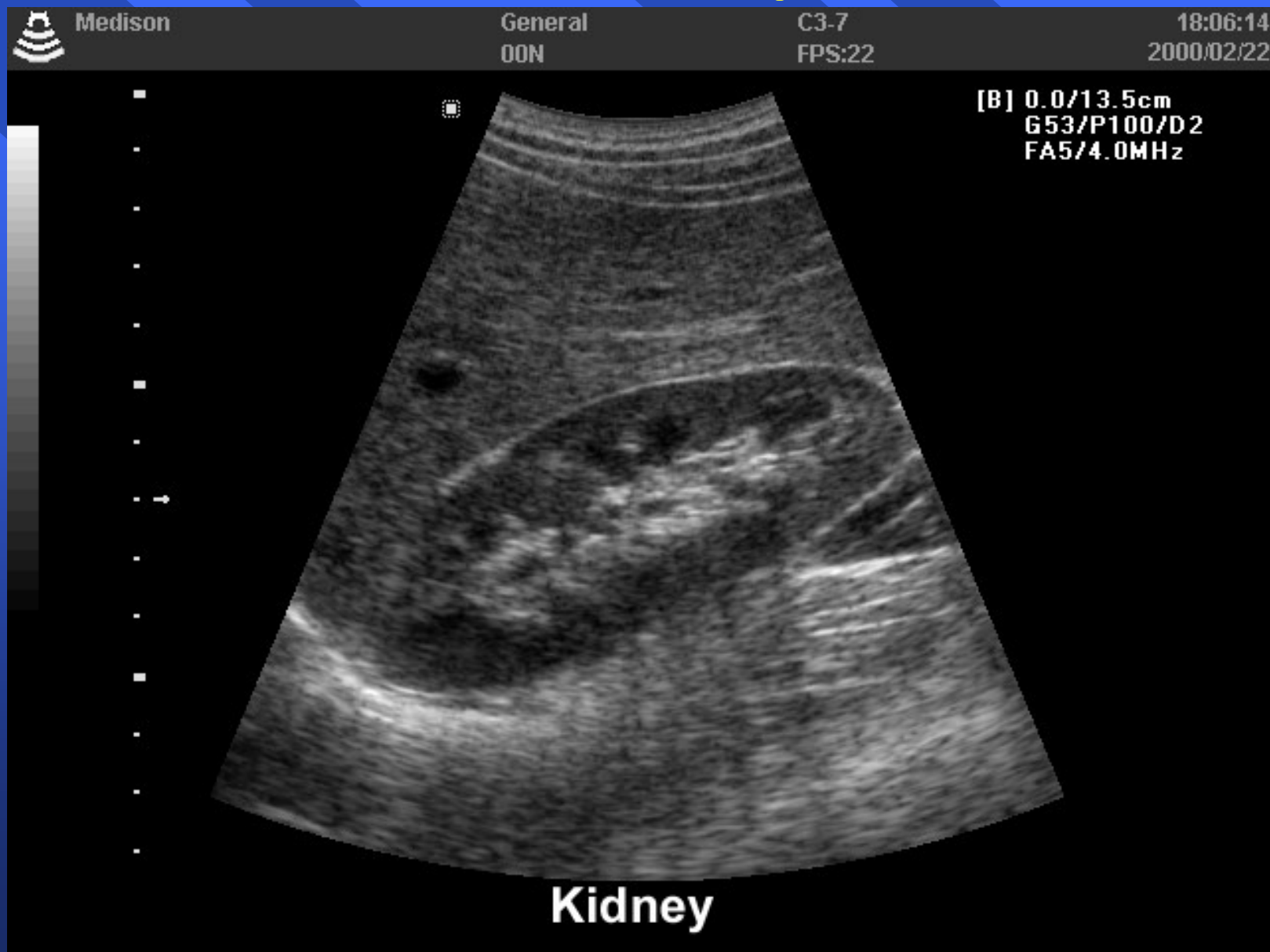
metastatický ascites



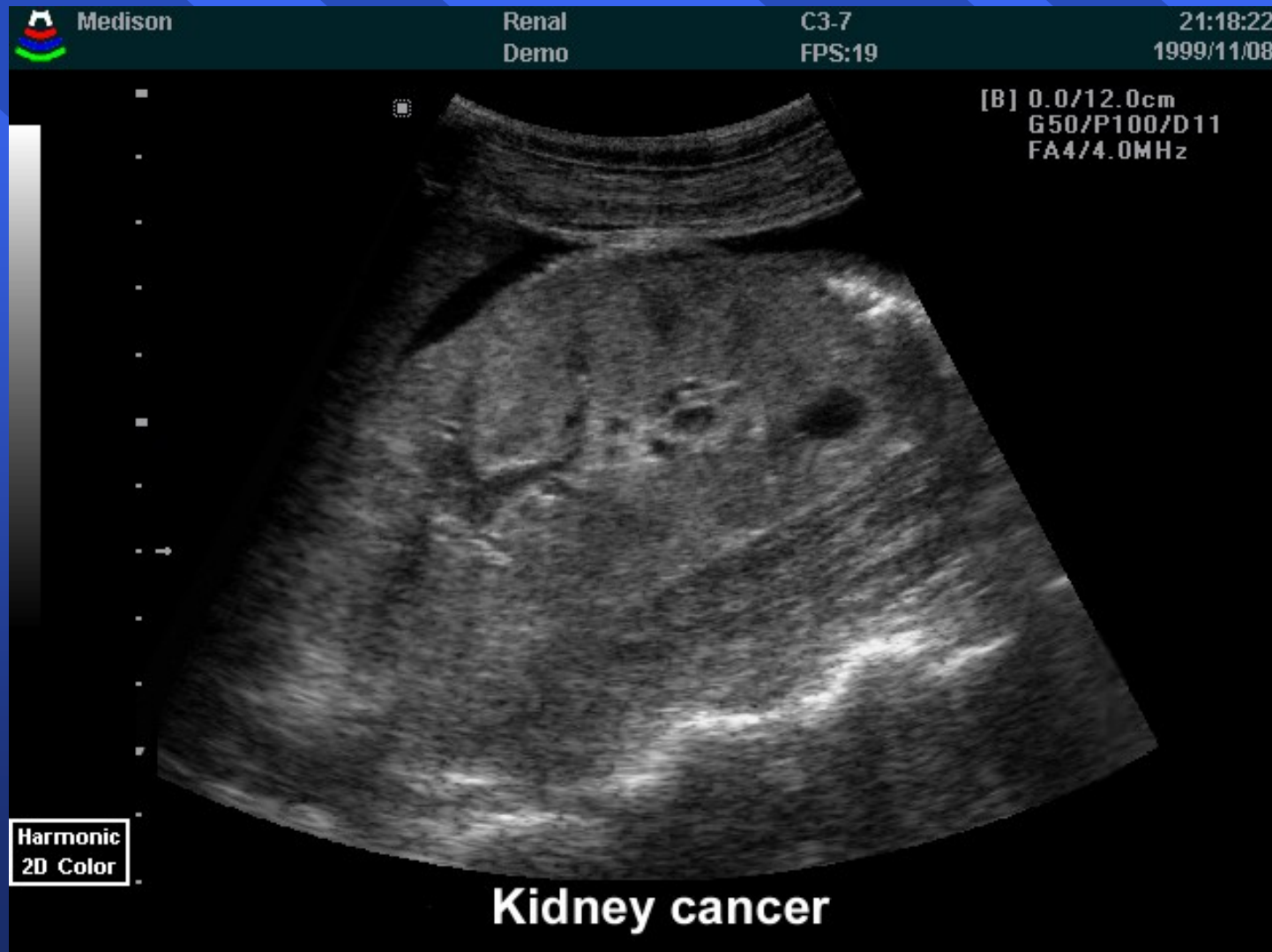
Intrahepatální kalicifikace



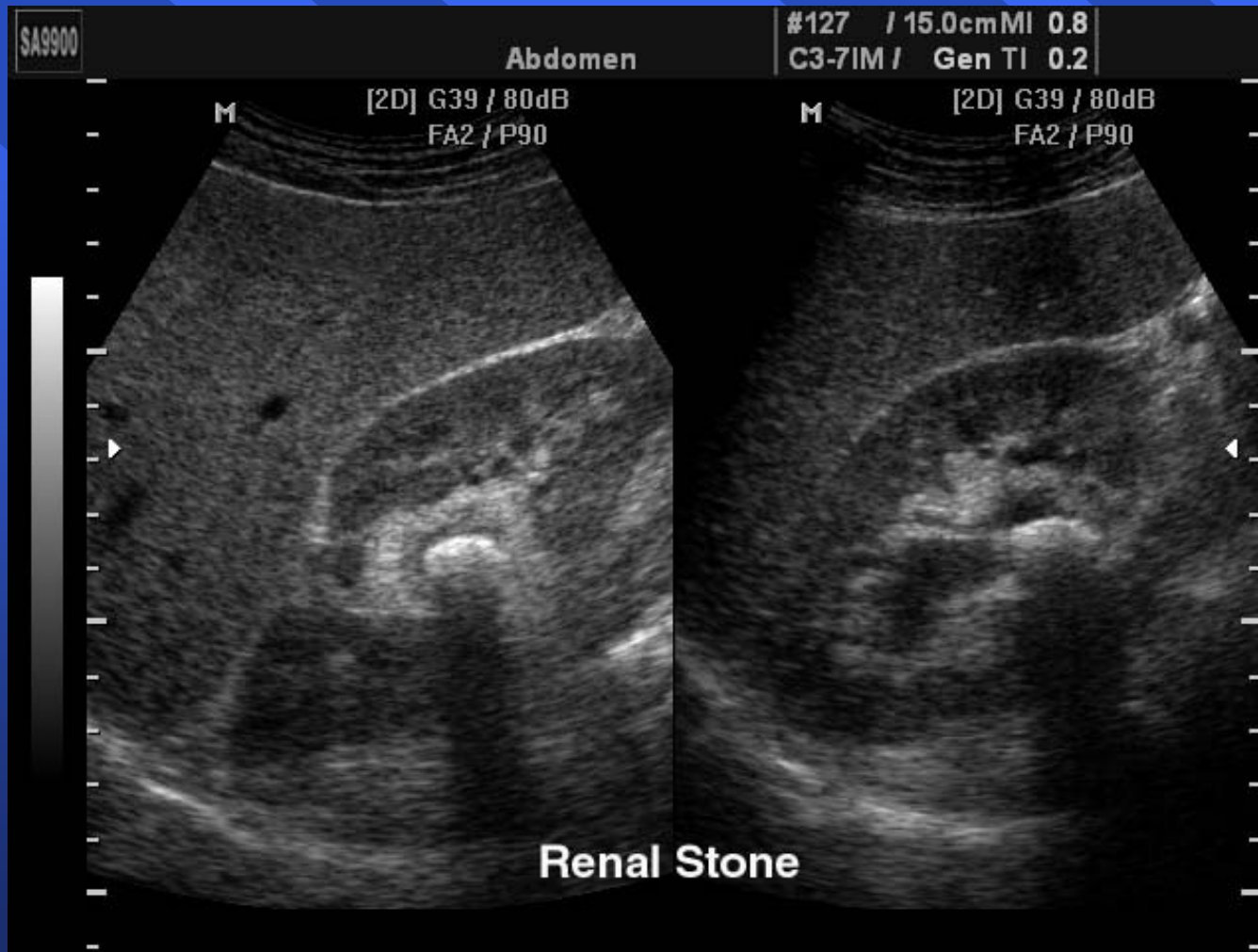Ledvina a sonda je dorzálně



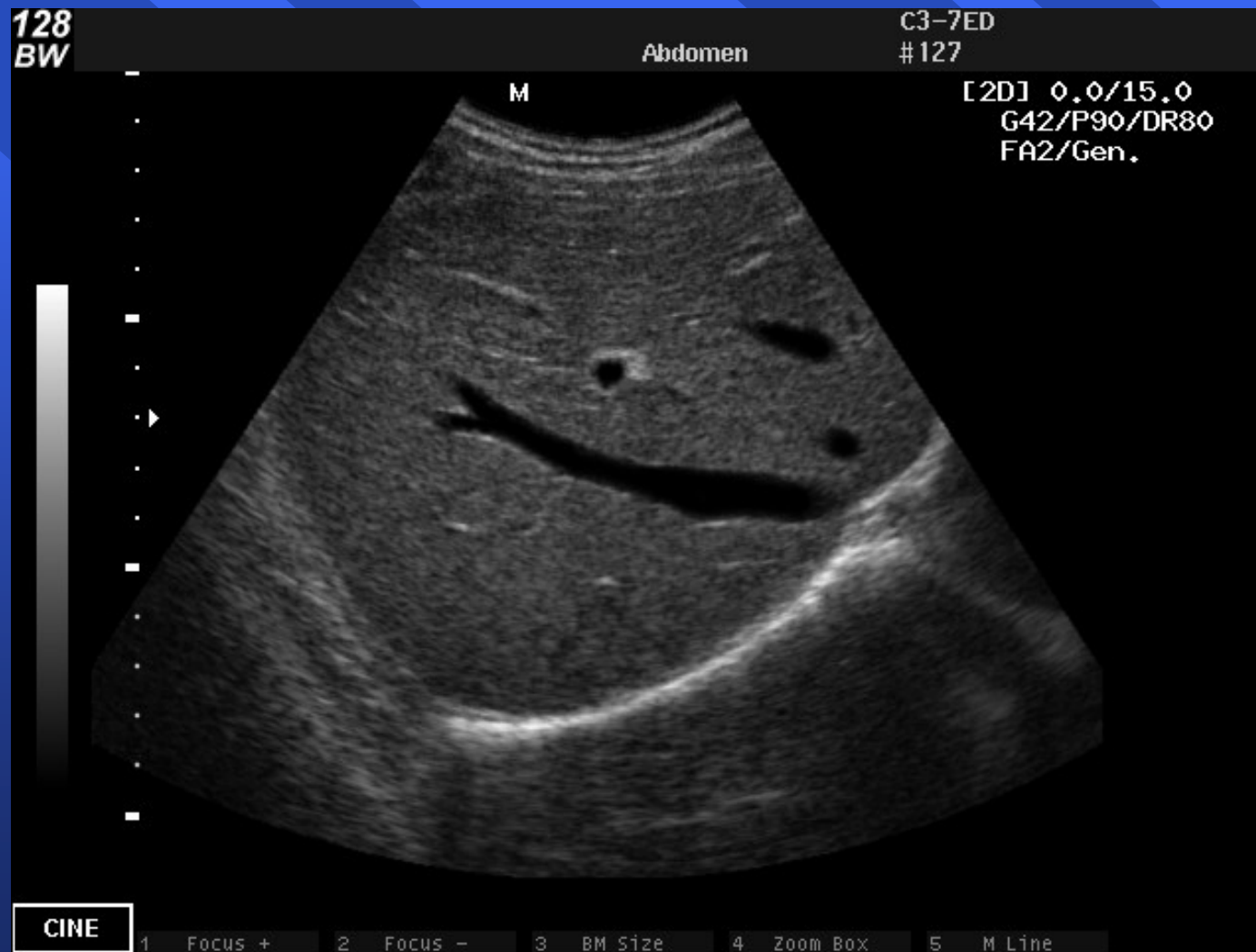Ledvina: Grawitzův tumor horního polu



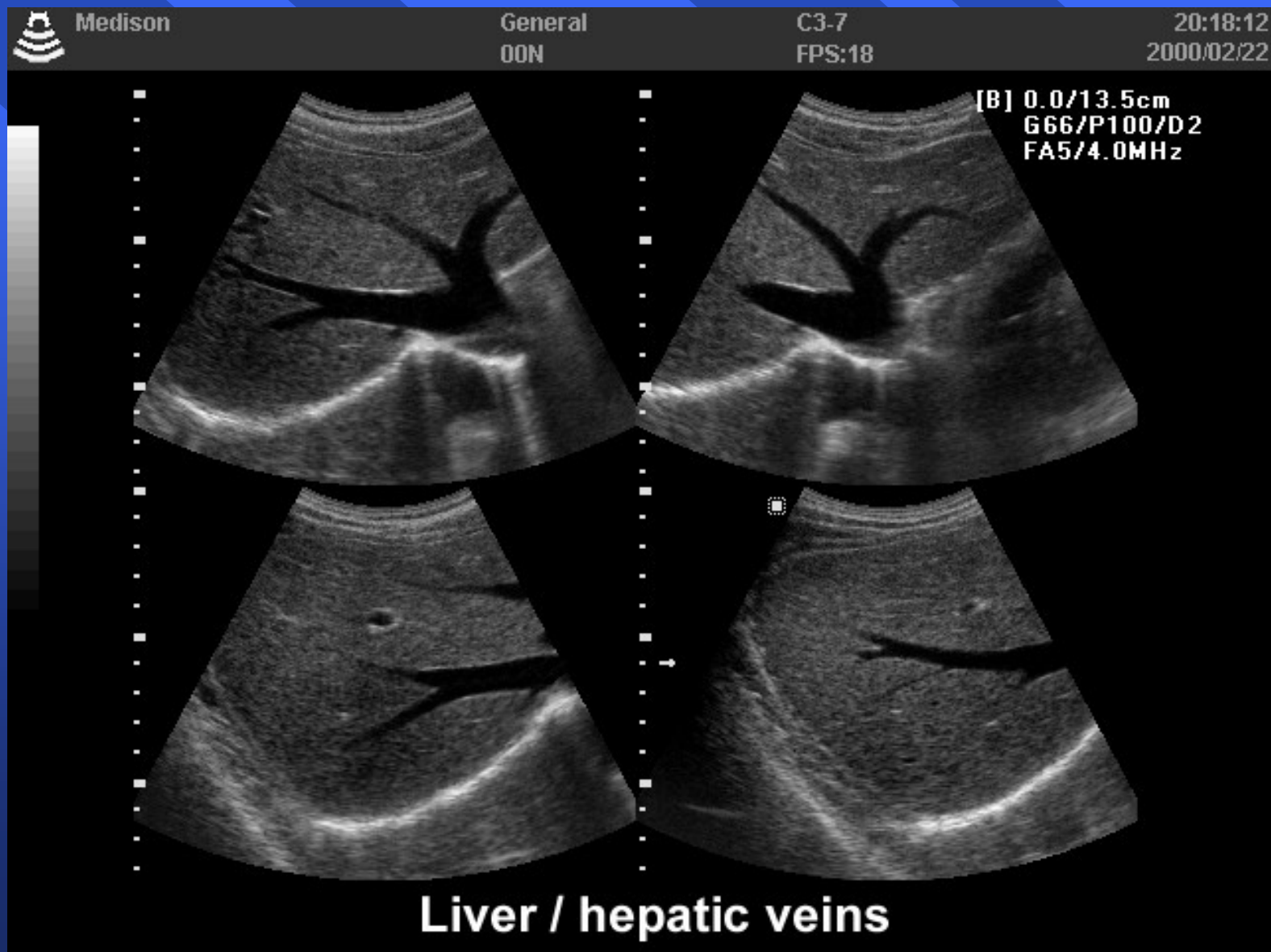Kámen v pánvičce ledviny



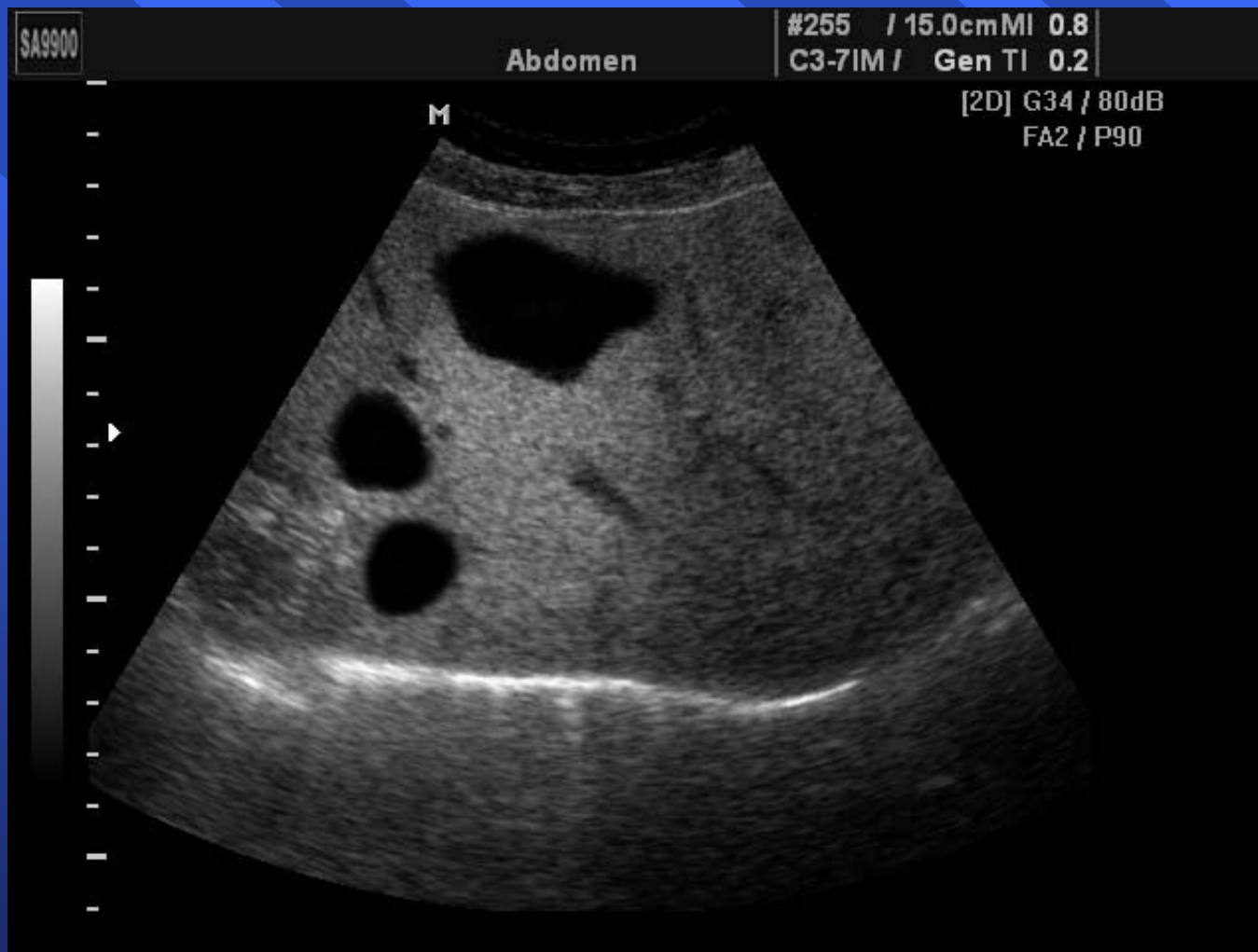Játra s obrazem jaterních žil



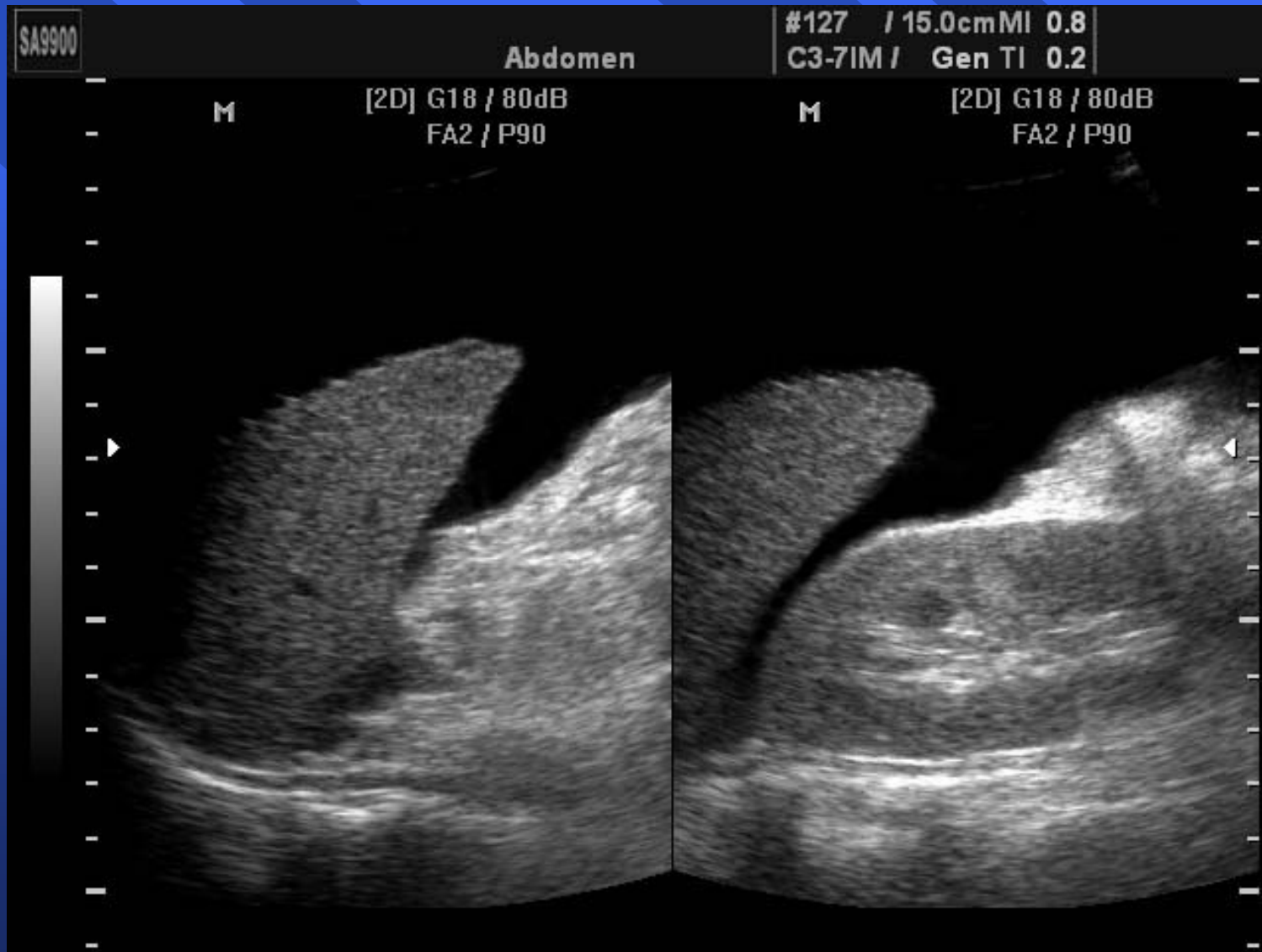
Pravostranné srdeční mětsnání



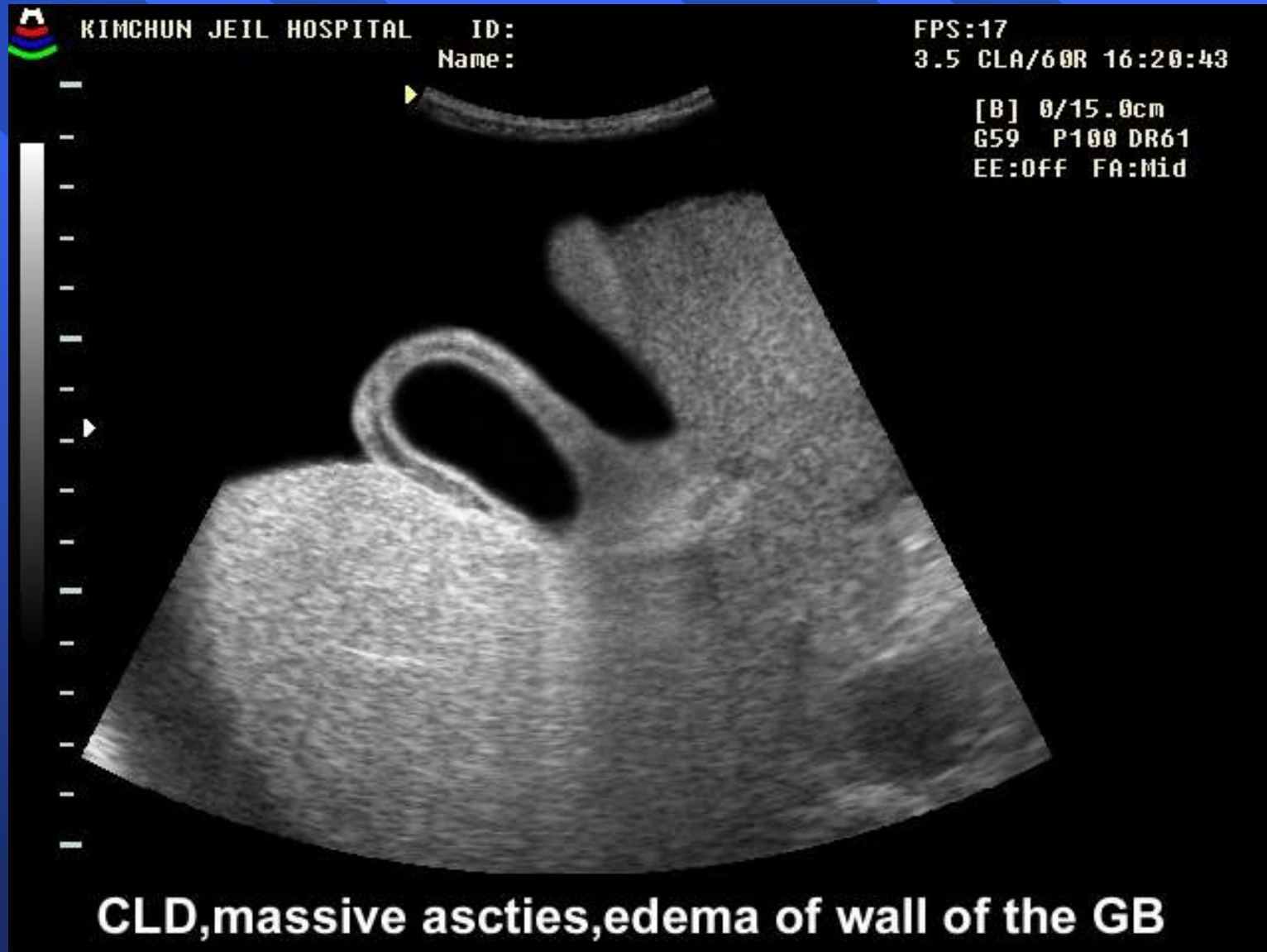Obraz jaterních cyst



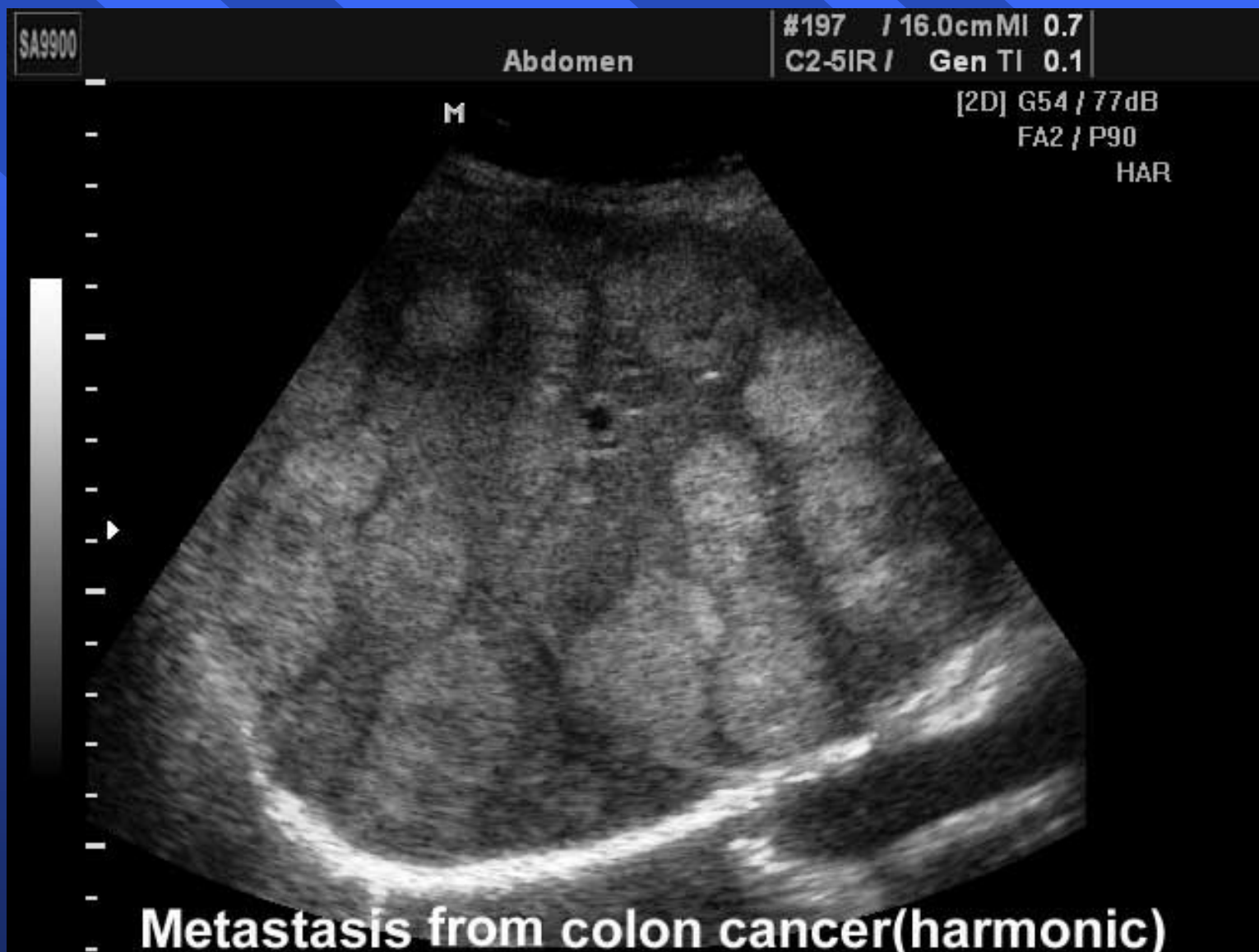Ascites při jaterní cirhóze



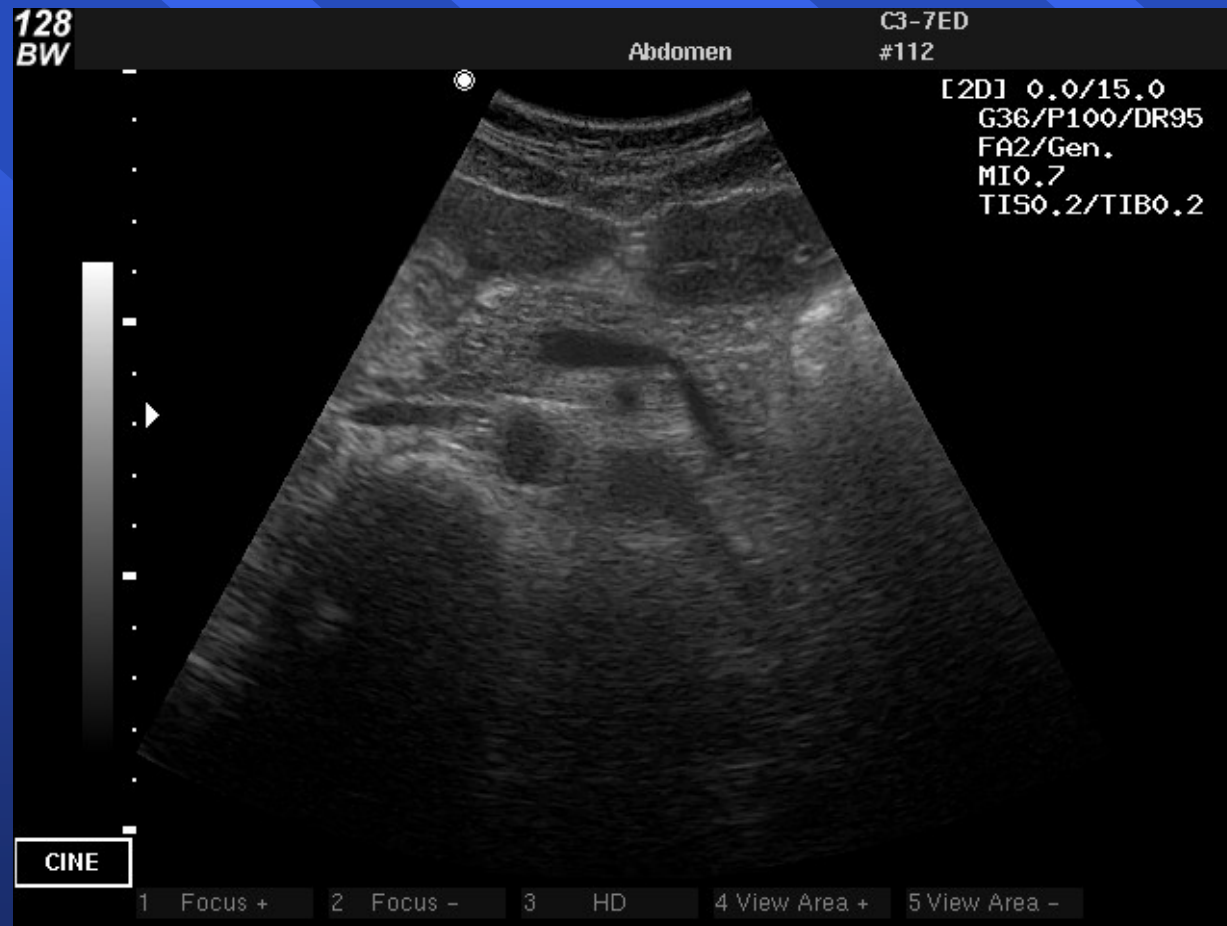
Cholecystitida v ascitu



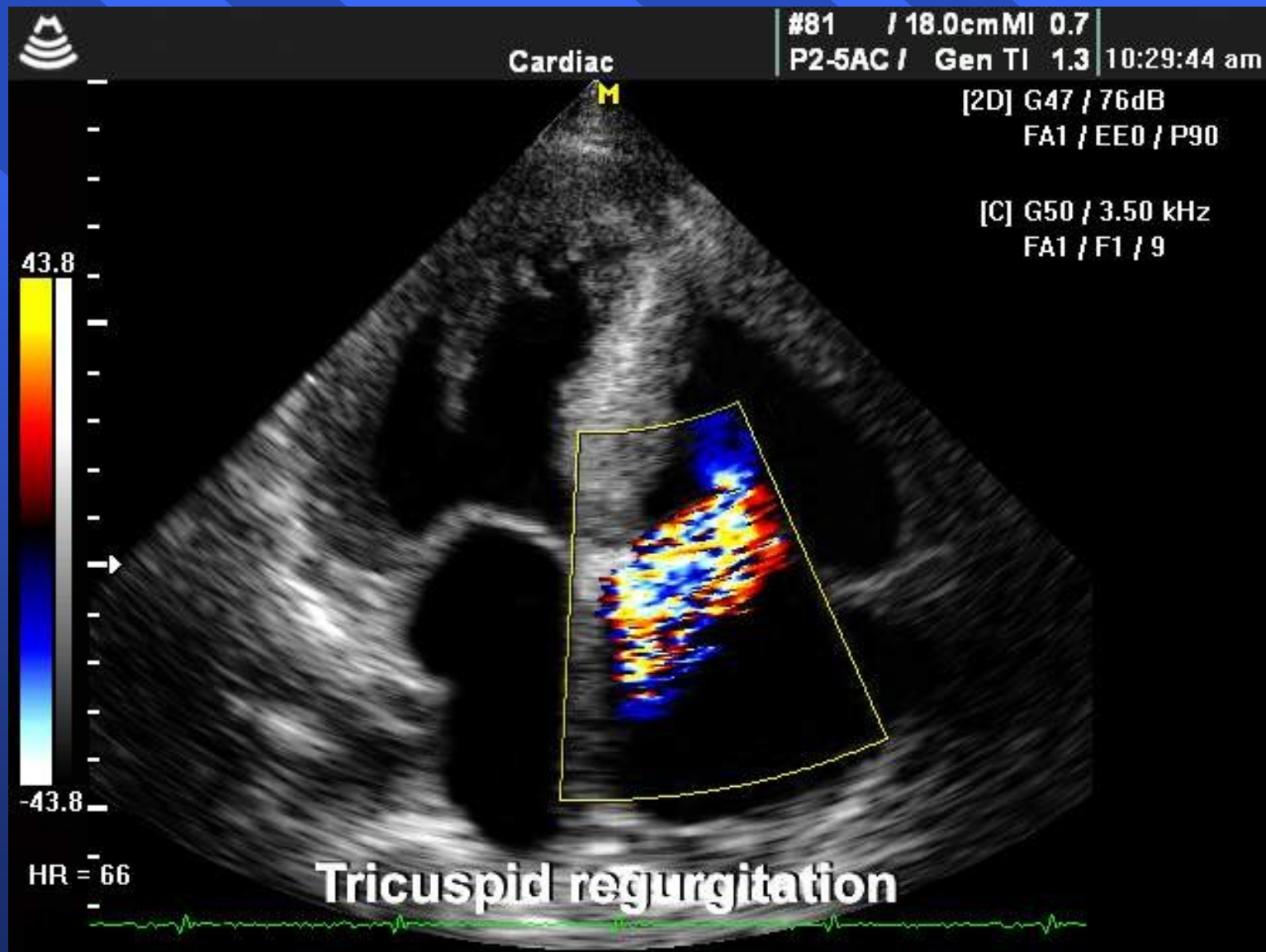
Mnohočetné meta jater



Obraz normálního pankreatu



Dopplerovský obraz regurgitace



Měření Dopplerovské v definovaném objemu

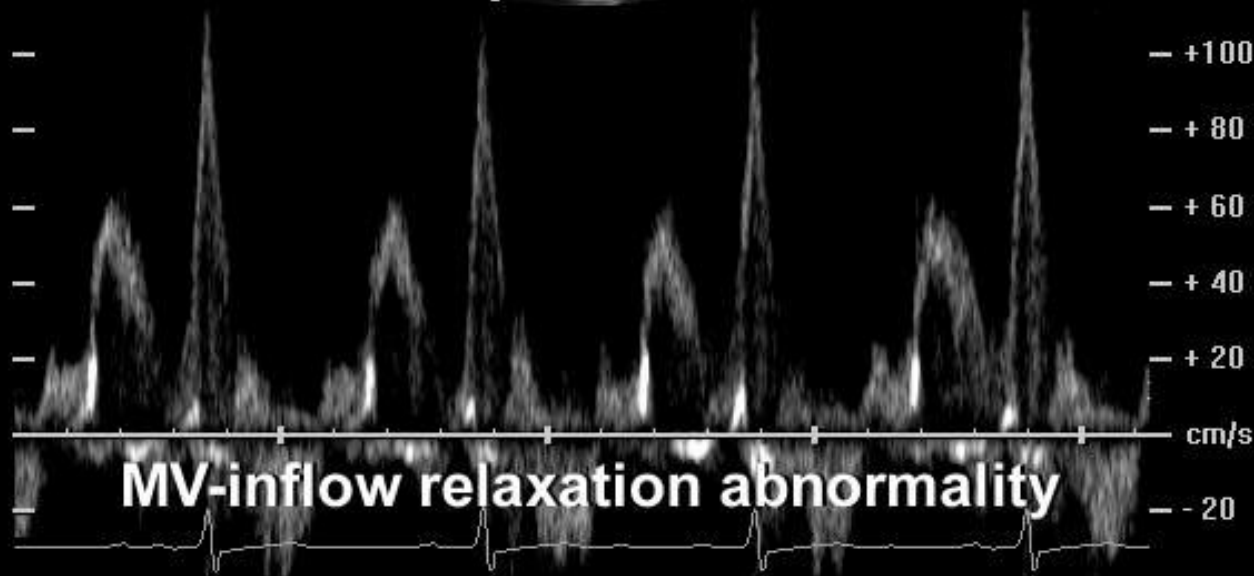
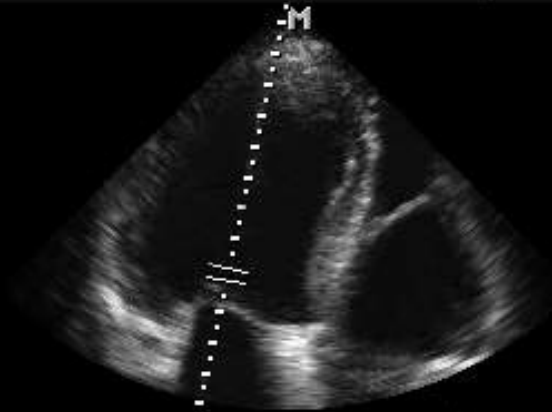
[PW] G35
F1 / 6.00 kHz
Depth 88
Size 4
Angle 0

Cardiac

#2020 / 13.0cmMI 0.4
P2-5AC / Gen TI 0.6

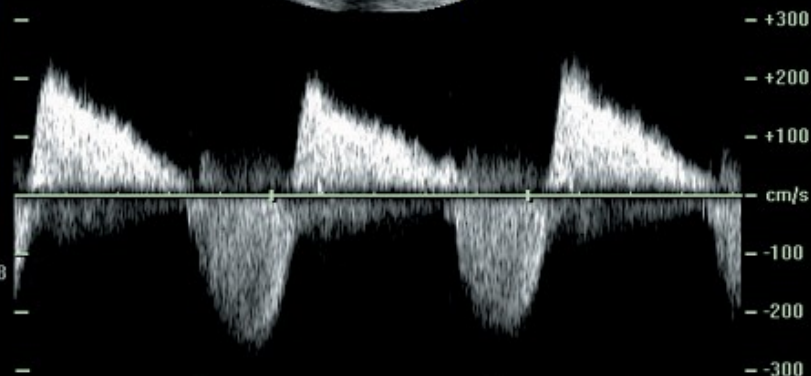

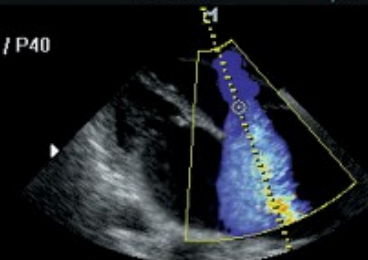
[2D] G41 / 8
FA0 / EI



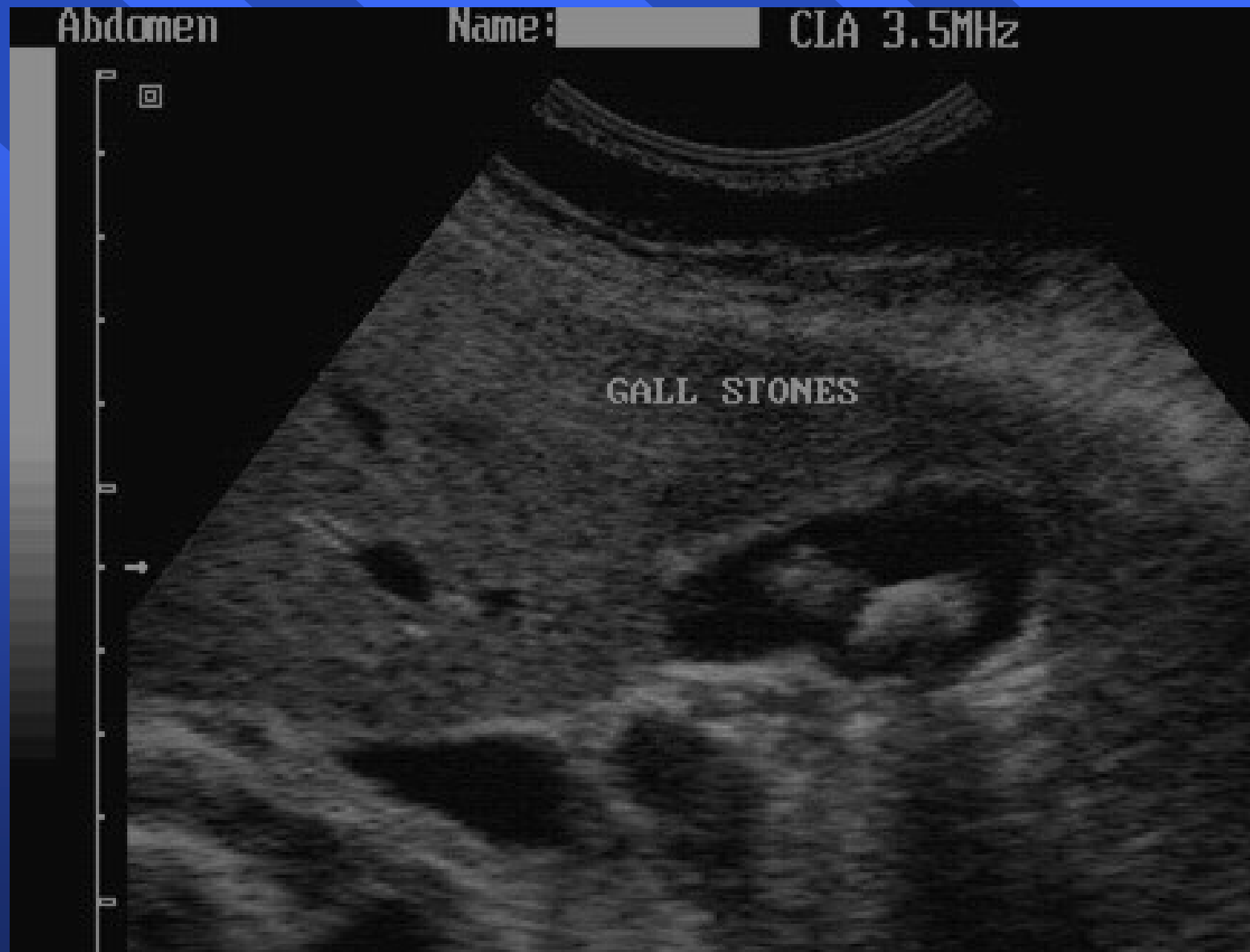[CW] G46
F1 / 15.63 kHz / P40
Depth 74

[2D] G47 / 76dB
FA1 / P90

[C] G42 / 3.50 kHz
FA1 / F1 / 11



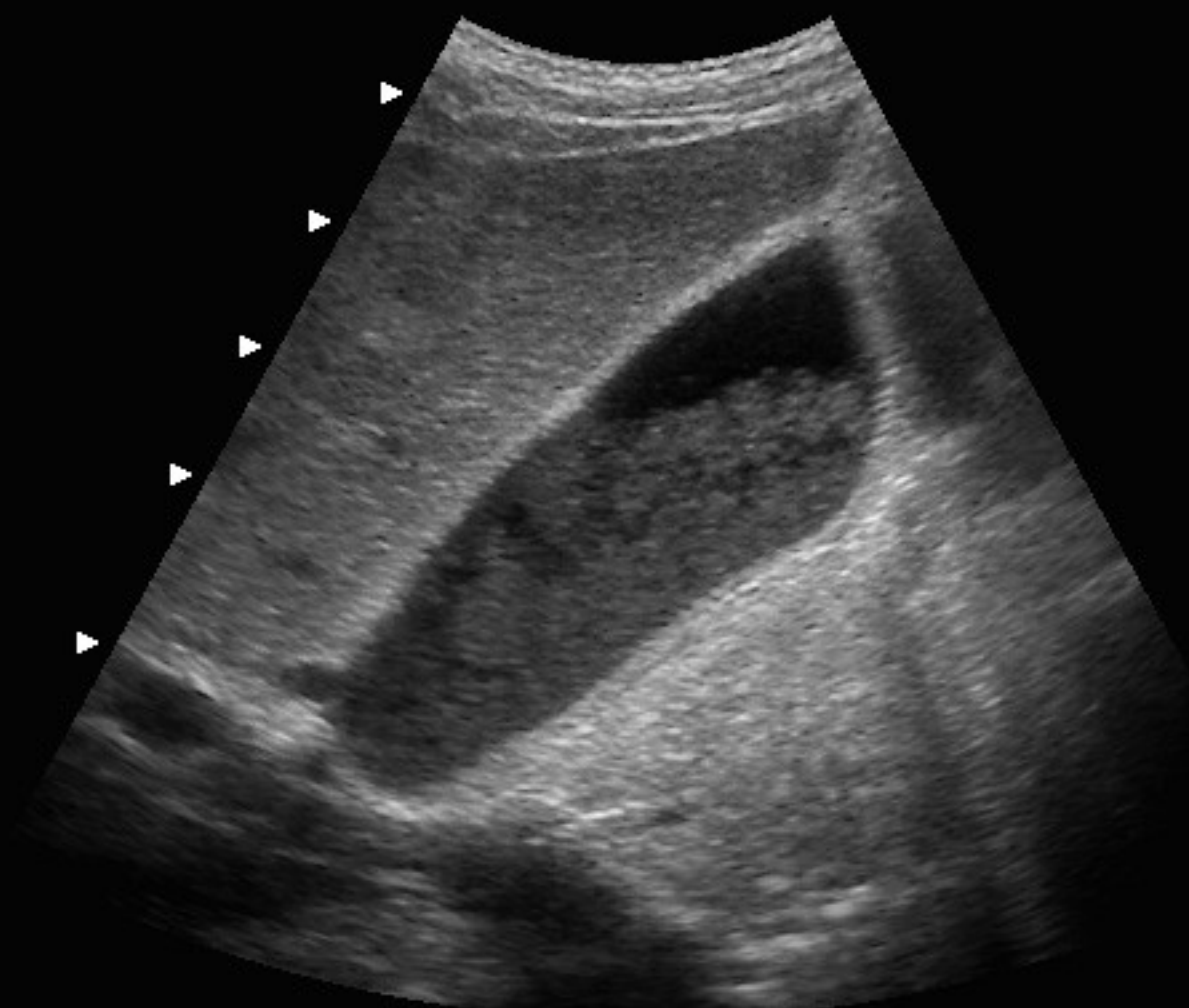Žlučníkové kameny



JACKSON MEMORIAL MED CTR
IM#10

GE

10cm 7548c
RENAL
FROZEN
39G
78DR



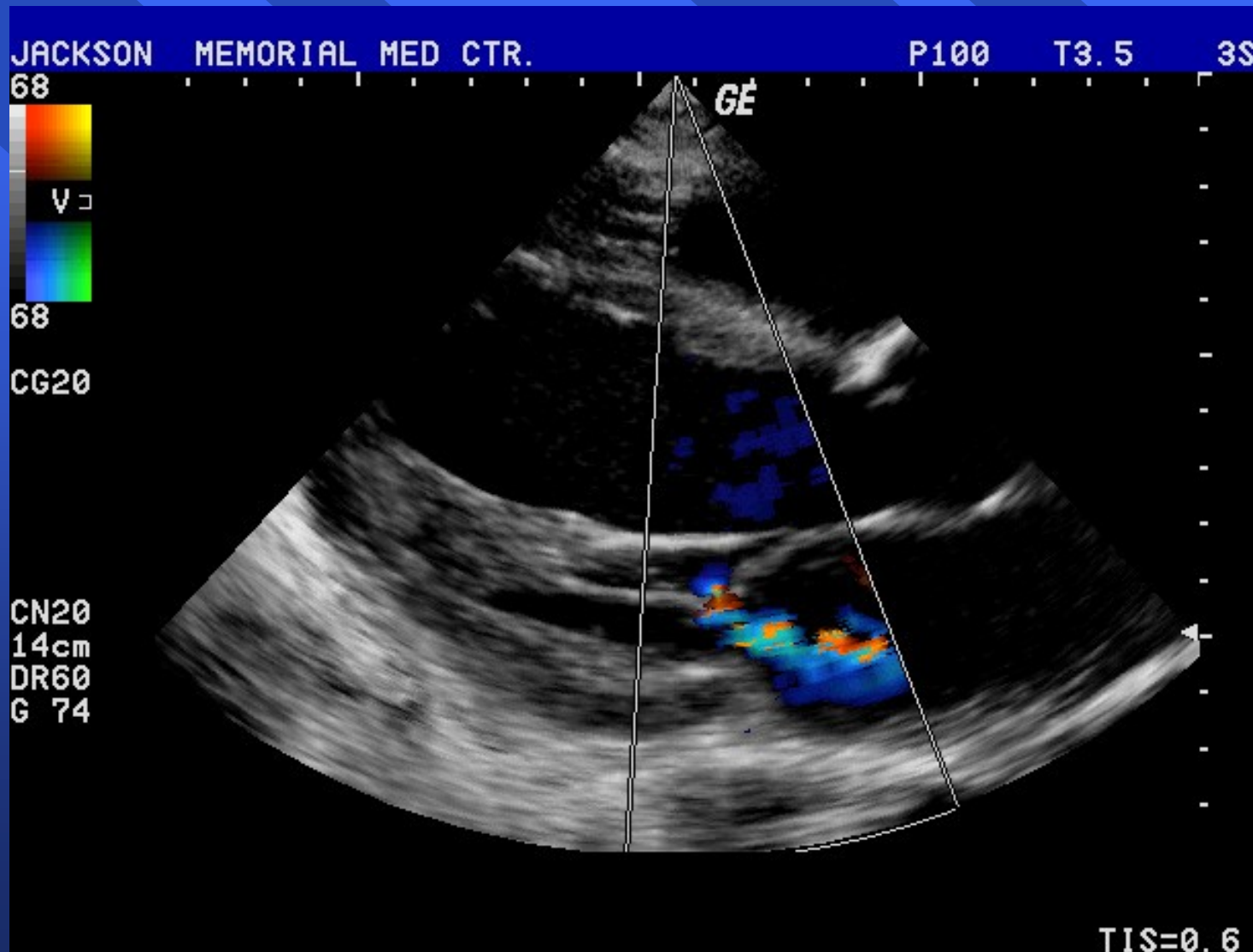
ACUTE CHOLECYSTITIS

MI<0.4 AO=100%

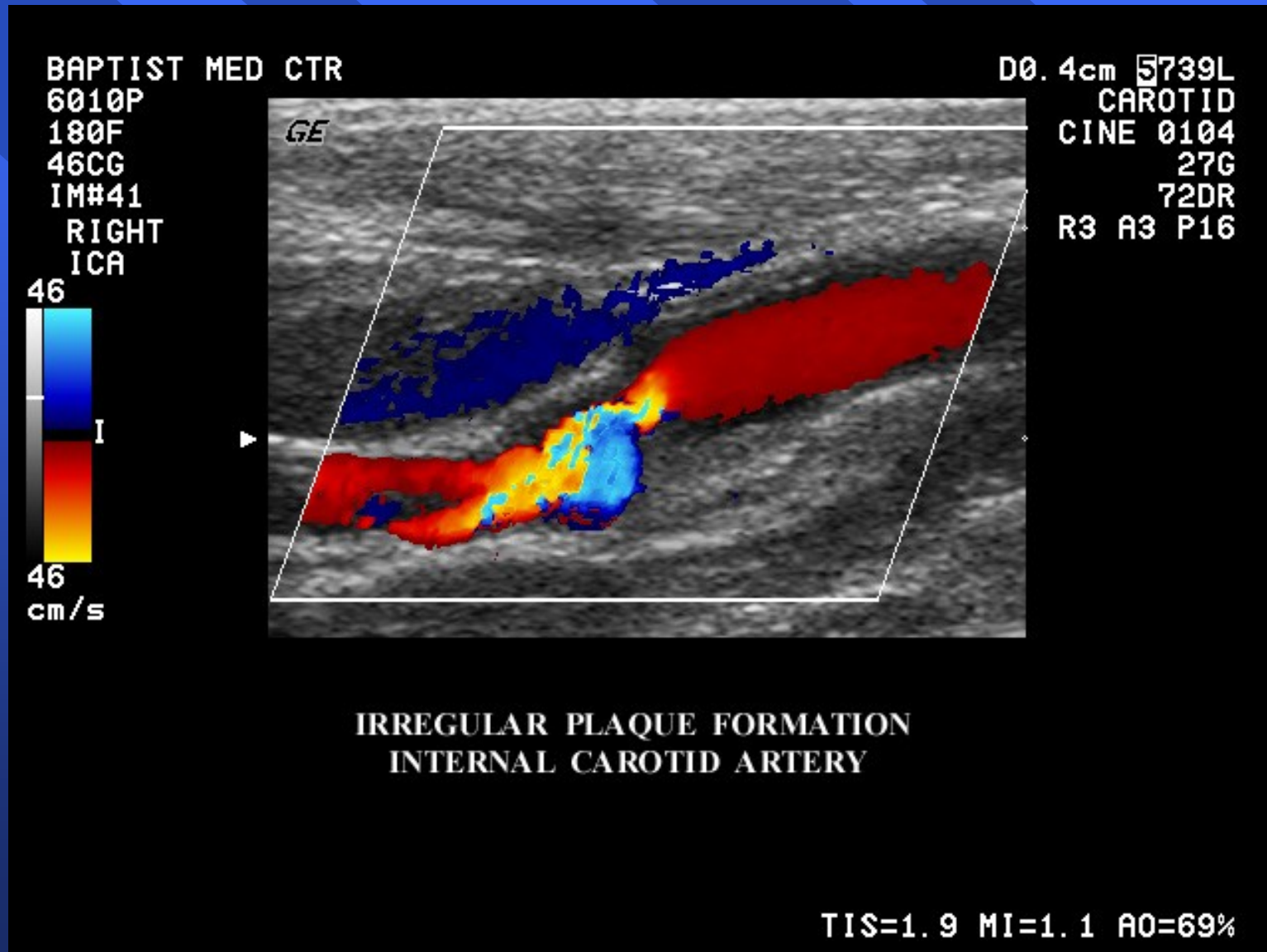
Akutni Chole- cystitida 2



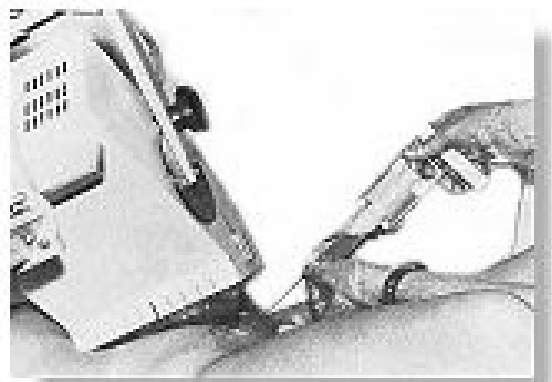
Barevný Dopplerův obraz



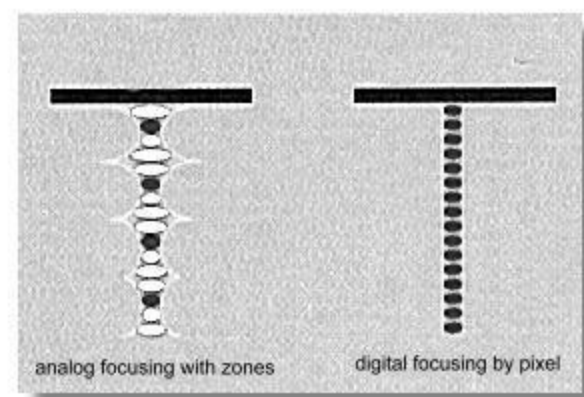
Arteria karotis interna



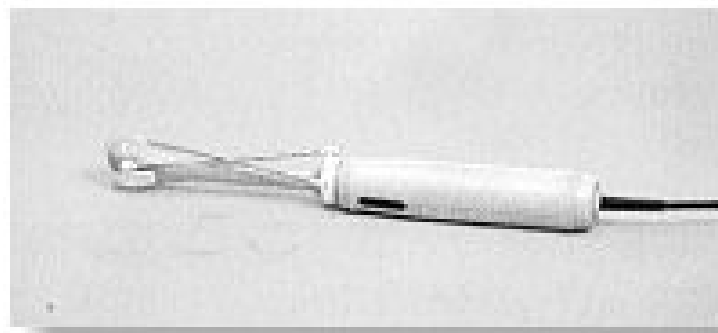
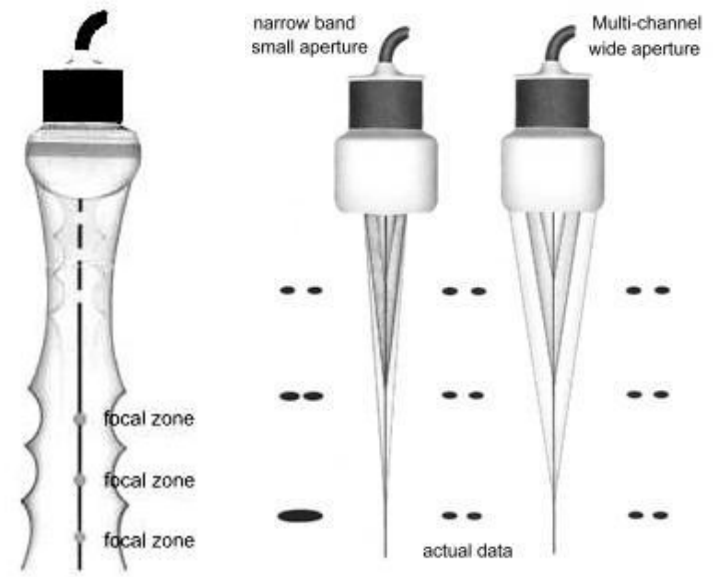
Přítomnost a novoty



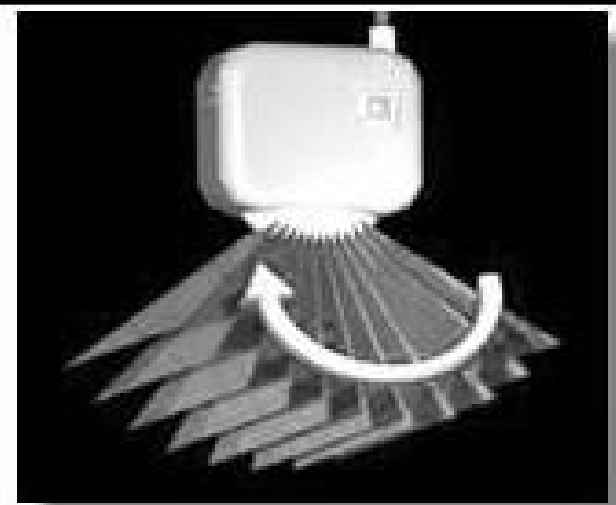
Amniocentesis with the Vidoson



Digital beamformer reduces noise and increase focal points



Kretztechnik's mechanical rotary vaginal scanner in 1985 with puncture attachment



Hand-held 3-D probe from Kretztechnik





Děkuji Vám za pozornost

