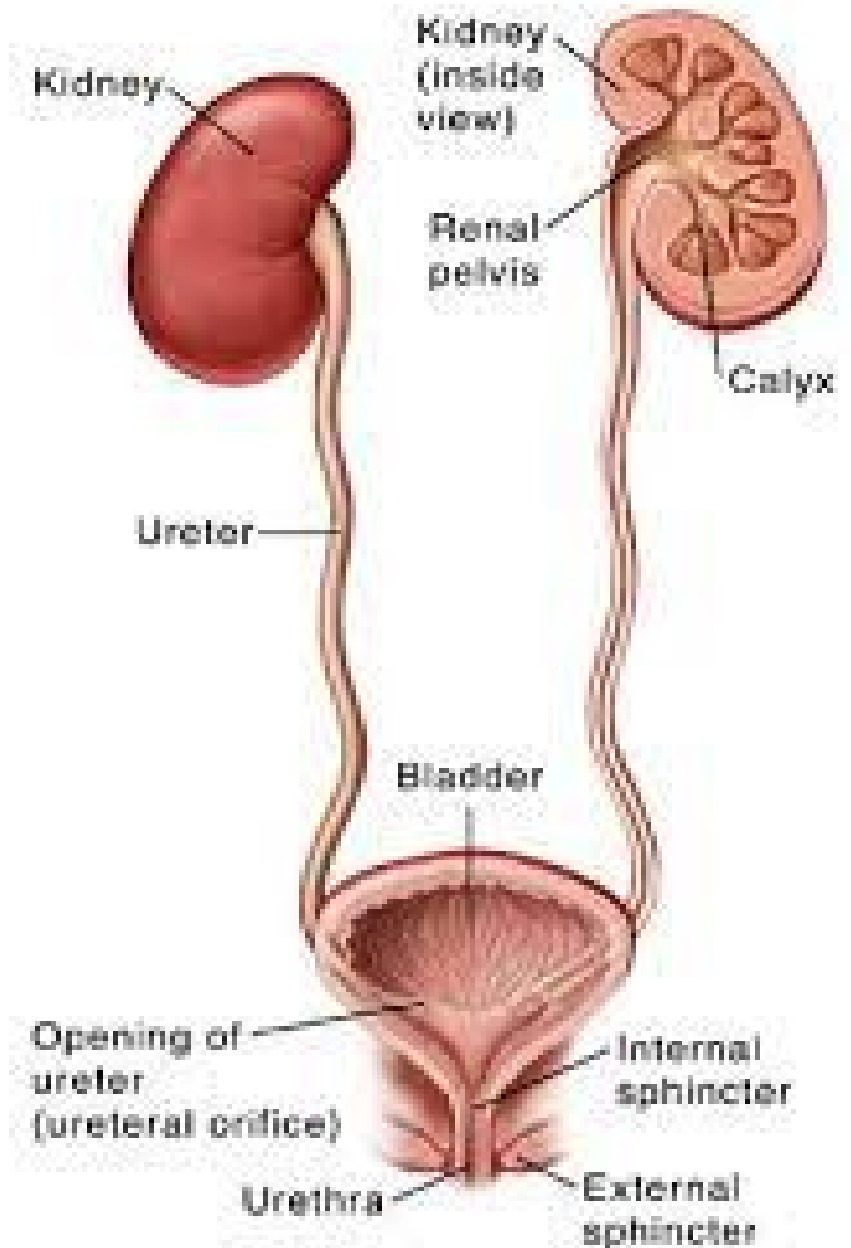
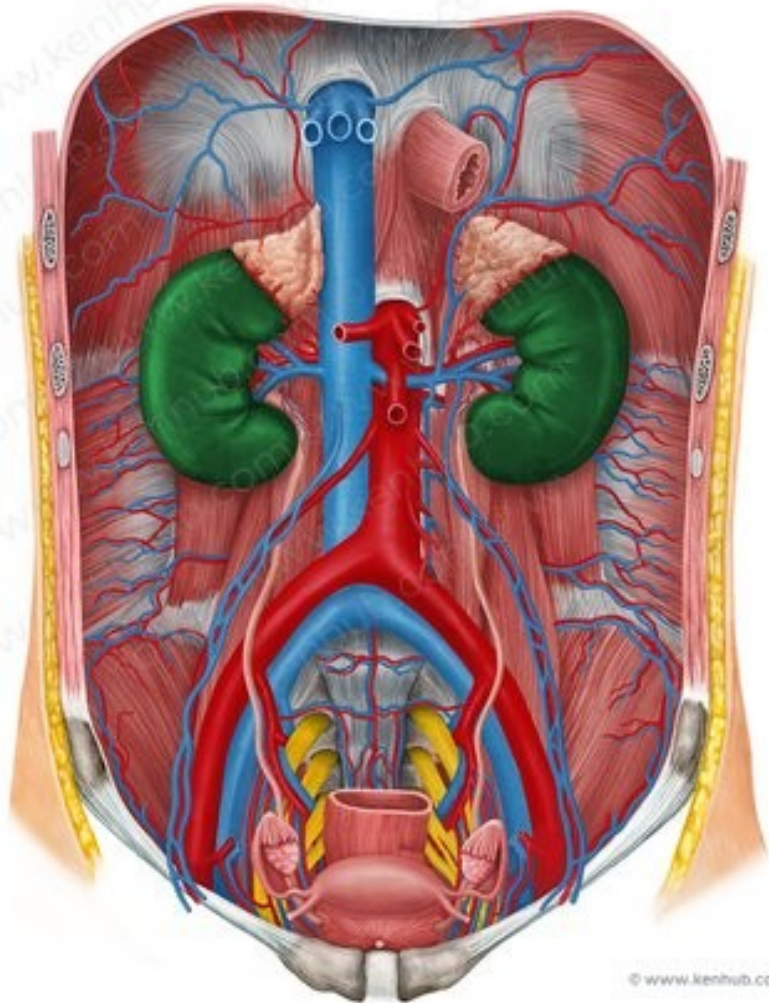
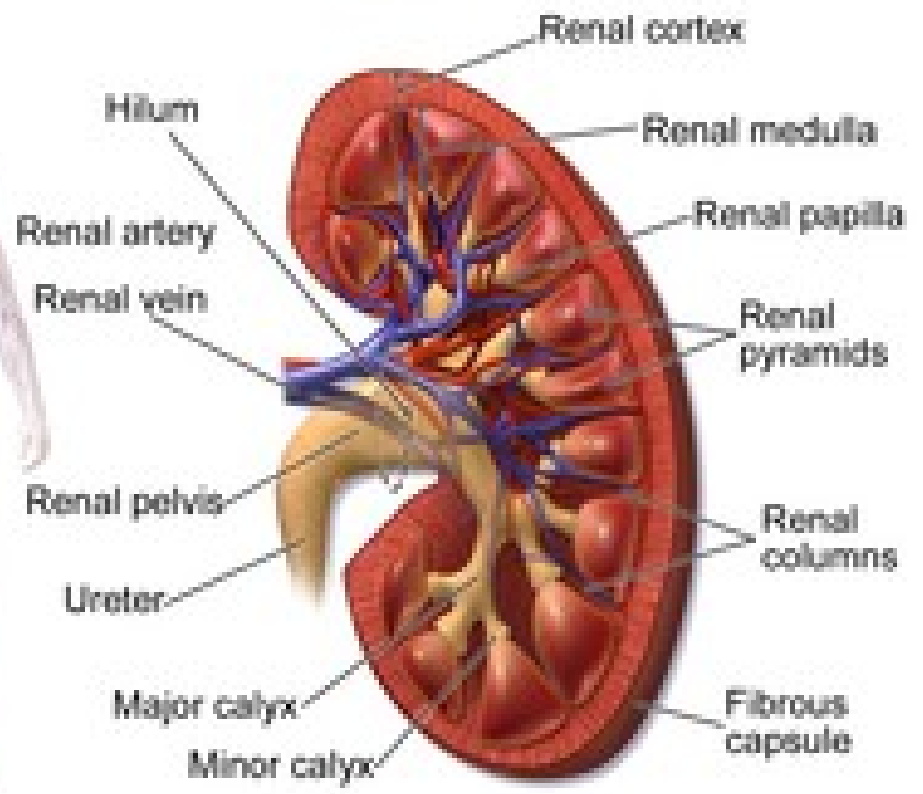
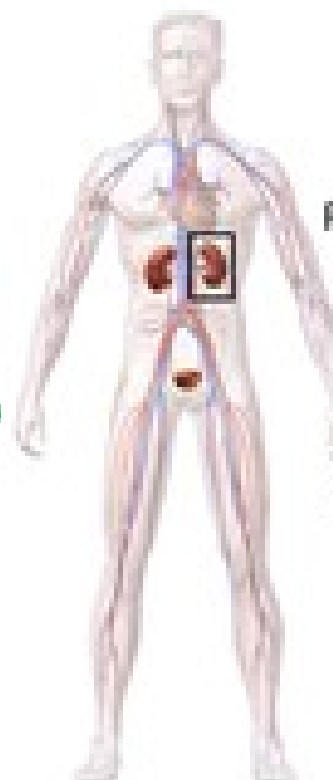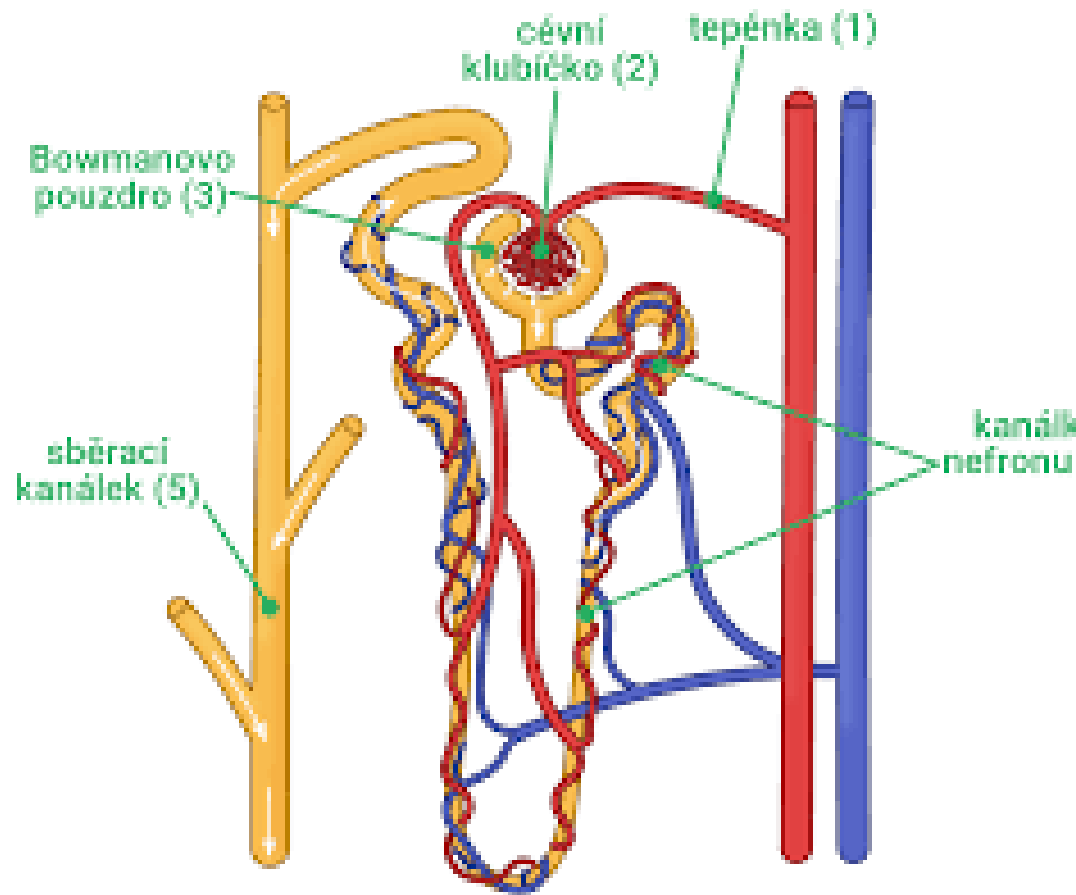


Vylučovací ústrojí



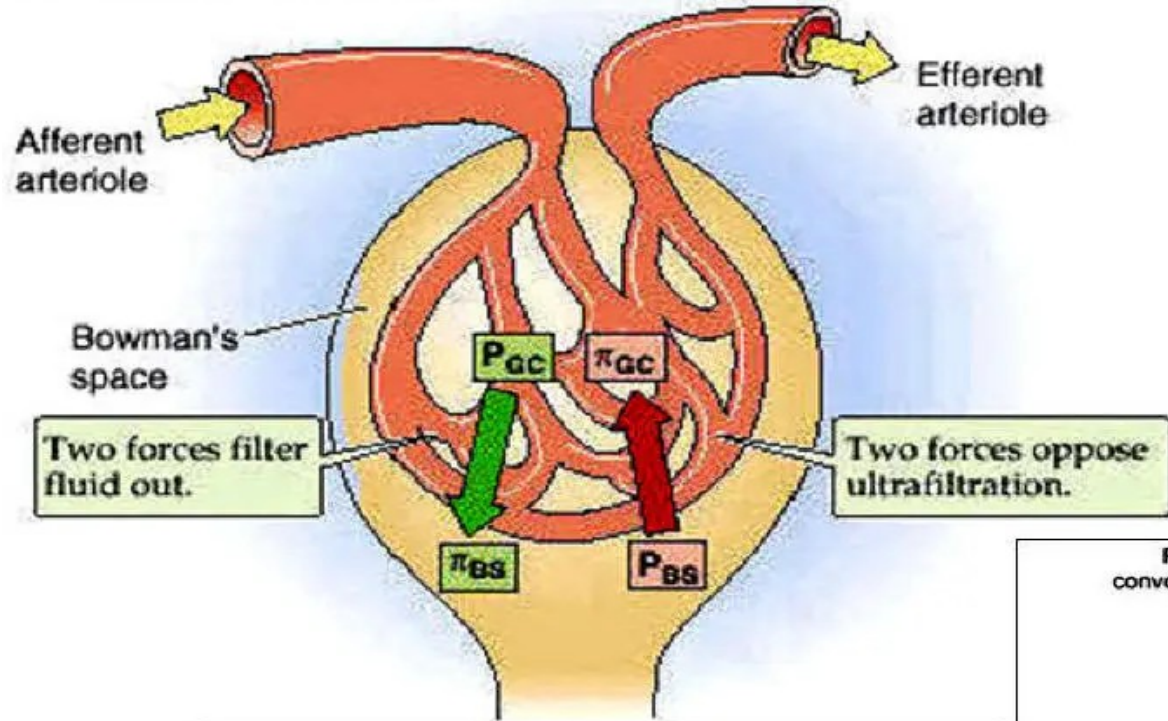
Ledvina, lat. ren

<https://en.wikipedia.org/wiki/Kidney>



Kidney Anatomy

A FORCES AFFECTING ULTRAFILTRATION

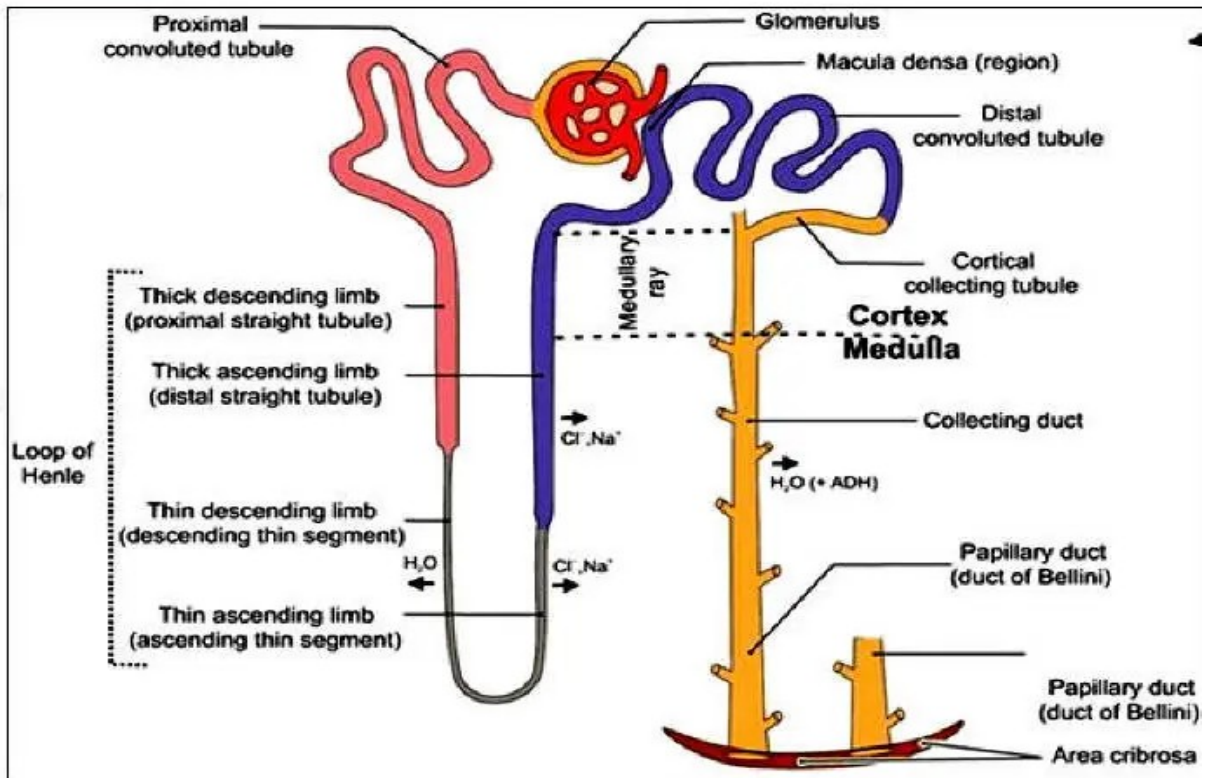
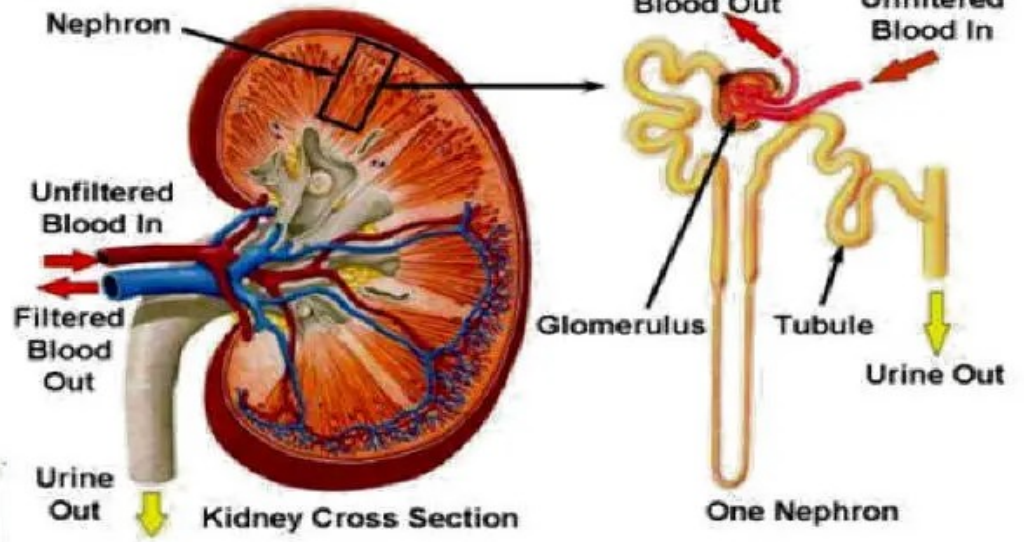


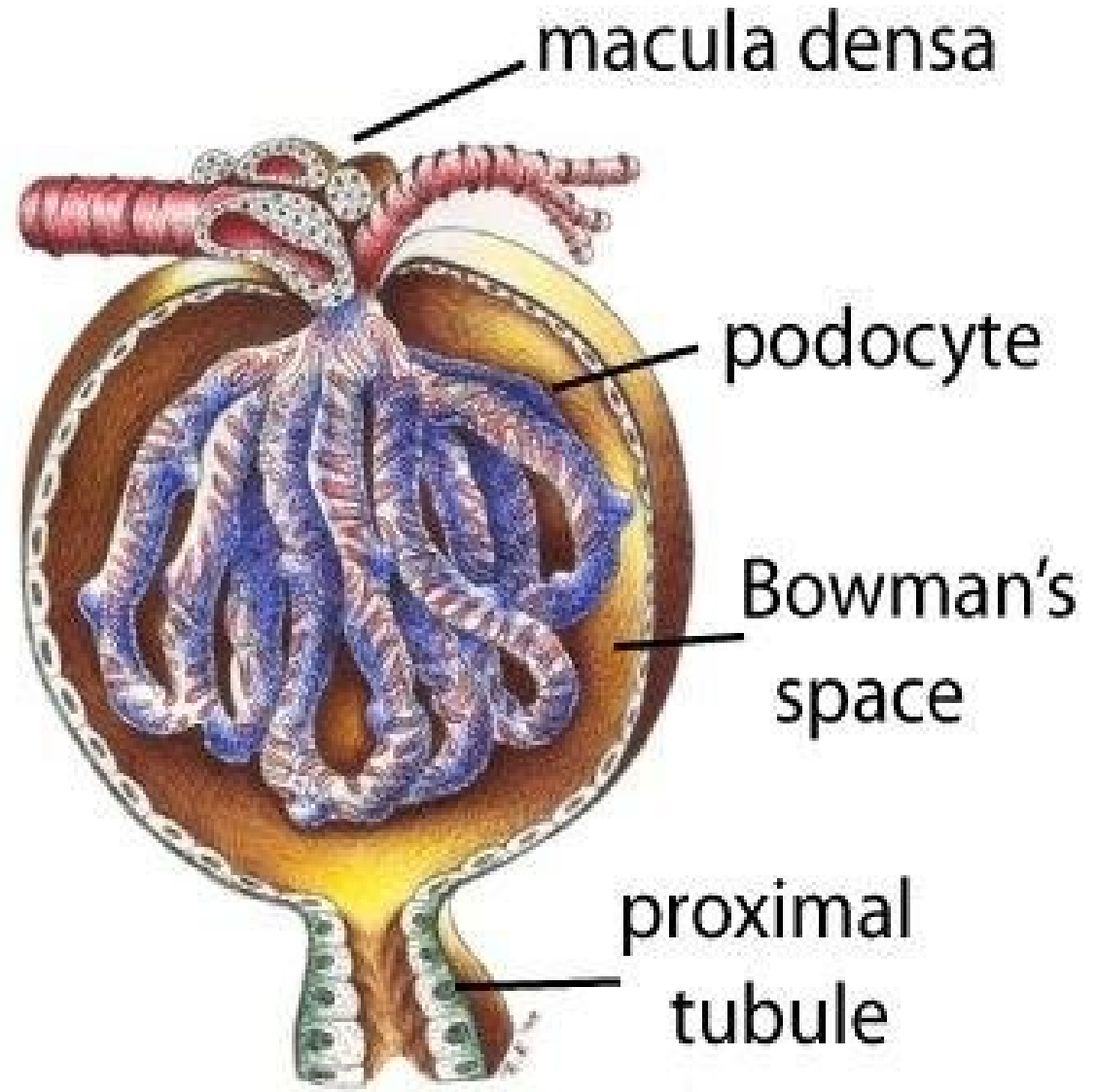
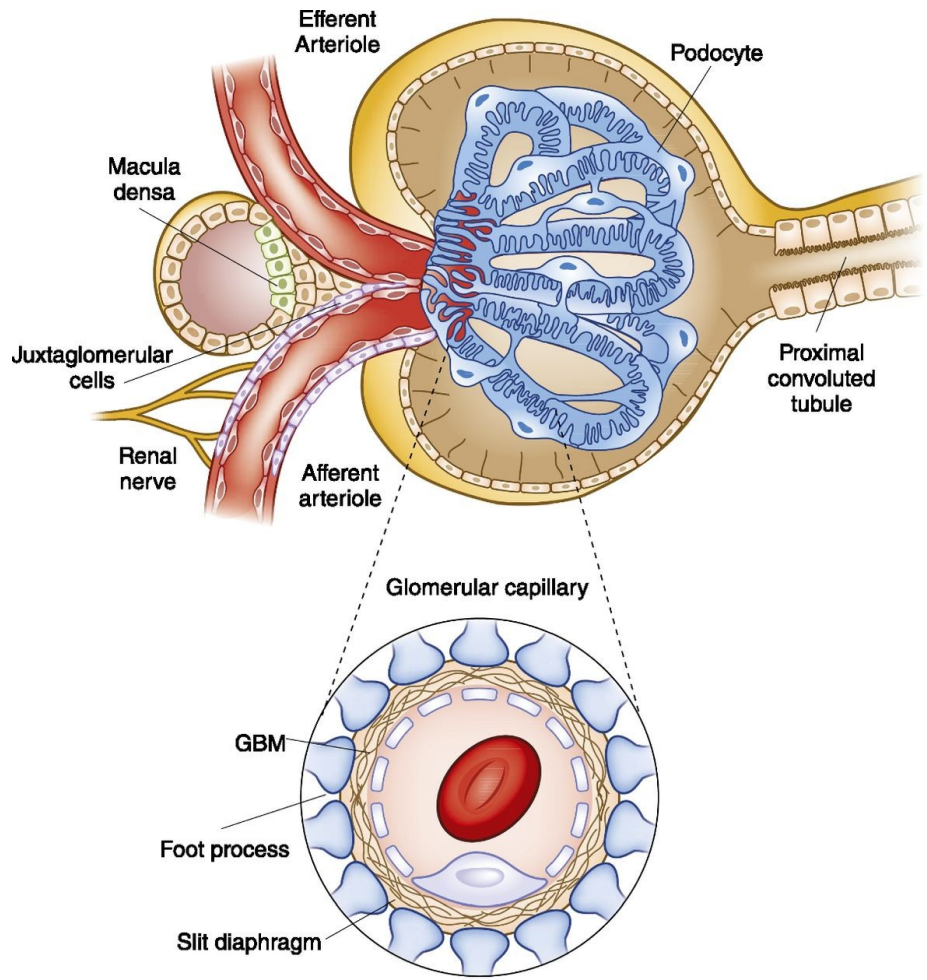
Two forces filter fluid out.

Two forces oppose ultrafiltration.

P_{GC} = Glomerular capillary hydrostatic pressure
 π_{BS} = Bowman's space oncotic pressure
 P_{BS} = Bowman's space hydrostatic pressure
 π_{GC} = Glomerular capillary oncotic pressure

Parts of the Nephron





<https://cjasn.asnjournals.org/content/clinjasn/9/8/1461111101ge.jpg?width=800&height=600&carousel=1>

Funkce ledvin

- Glomerulární filtrace: primární moč 180 l/d
- Tubulární resorpce: definitivní moč 1,5-2 l/d

- https://youtu.be/9_h0ZXx1IFw

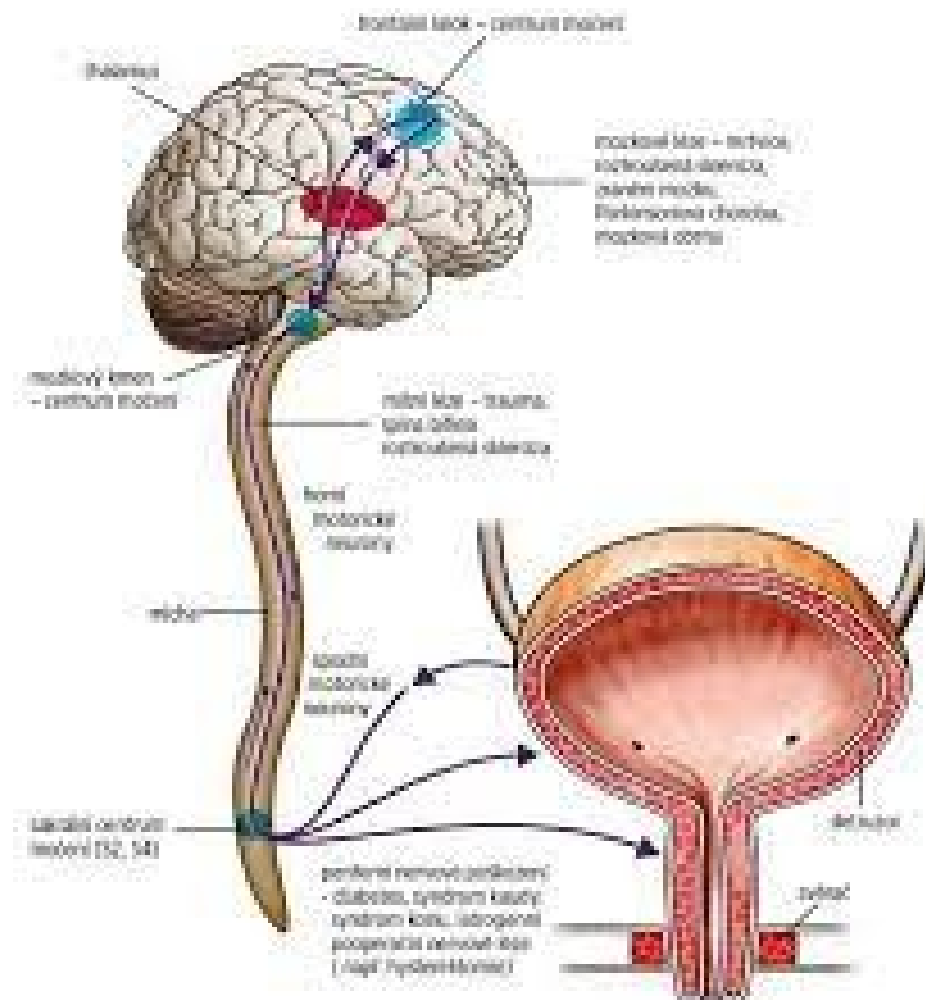
Močový systém

- <https://youtu.be/fQIt5tRYUNE>

Mikce

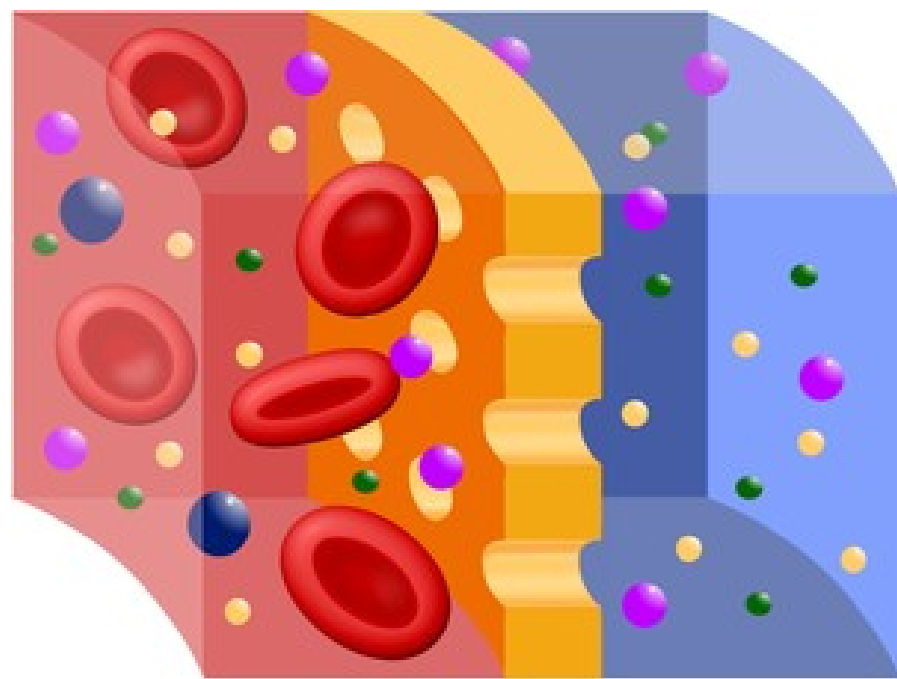
Moč

- <https://youtu.be/US0vNoxsW-k>
- Denní diuréza
- Oligurie
- Anurie
- Polyurie
- Polakisurie
- Dysurie
- Strangurie
- Hematurie
- Voda
- Močovina
- Urobilinogen
- NaCl
- pH 6
- Slámově žlutá

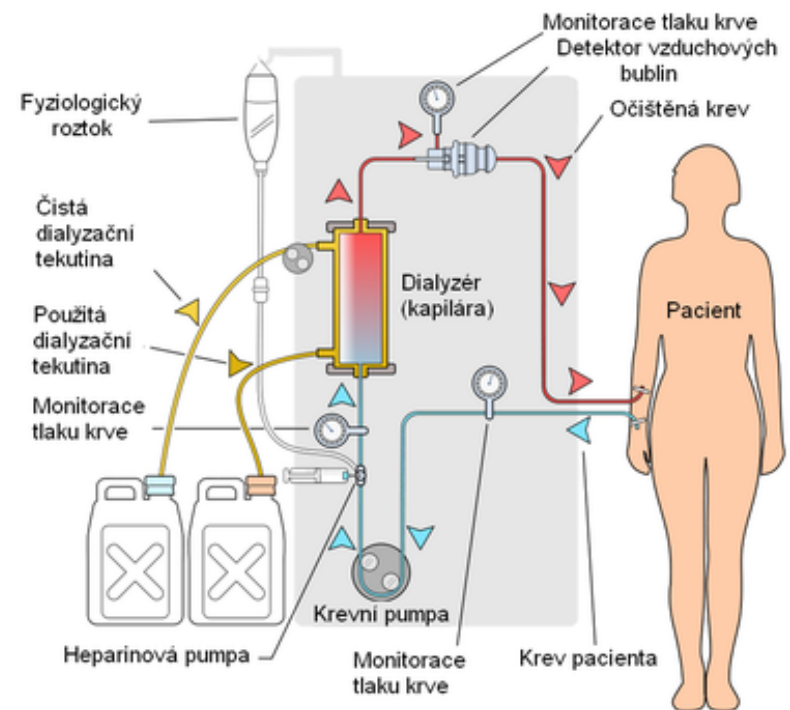


Dialýza

Hemodialýza

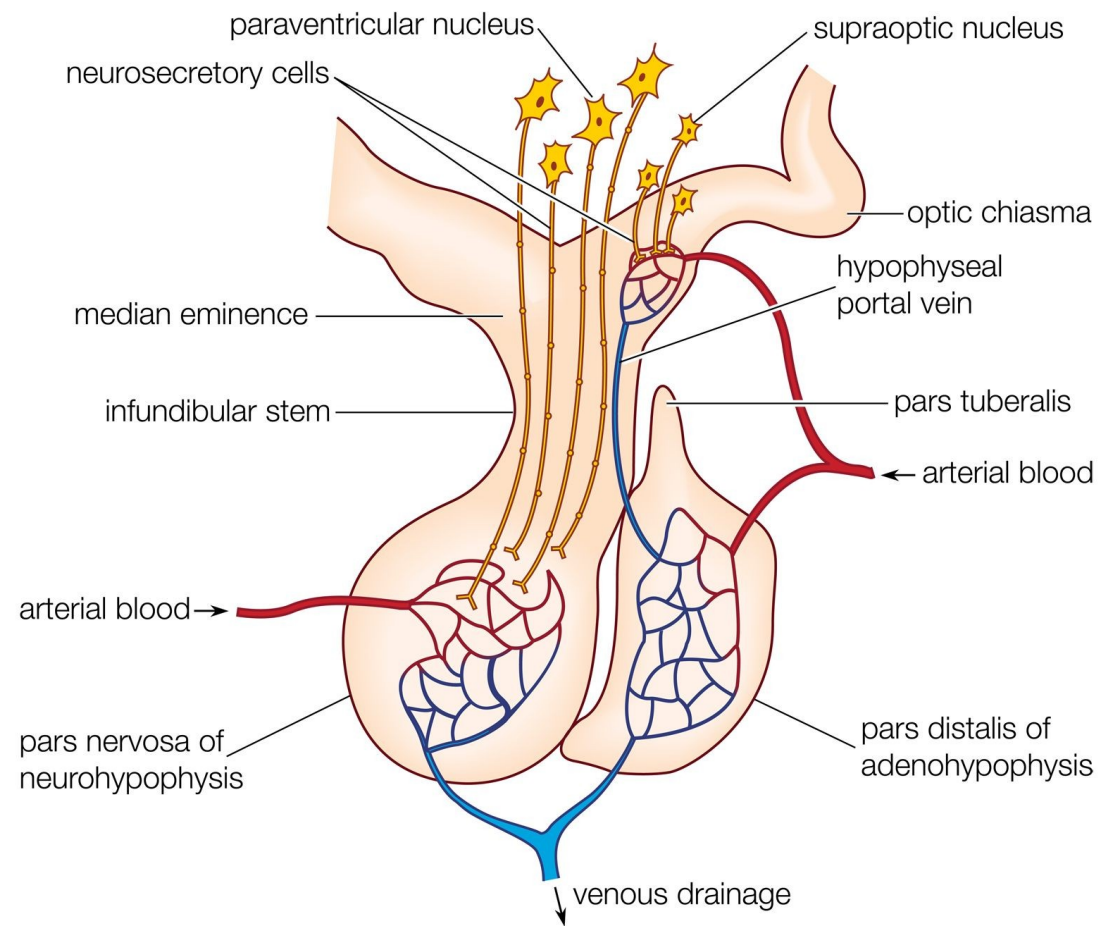
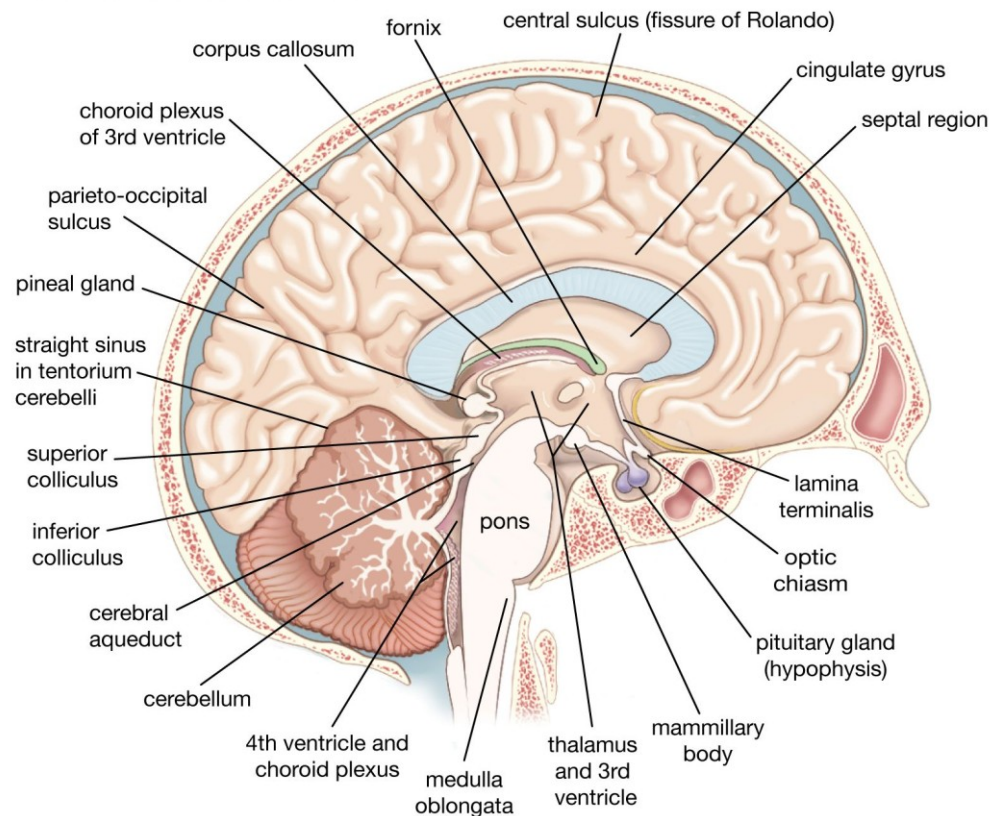


Peritoneální dialýza



Endokrinní systém

Human brain in cross section



Hypofýza

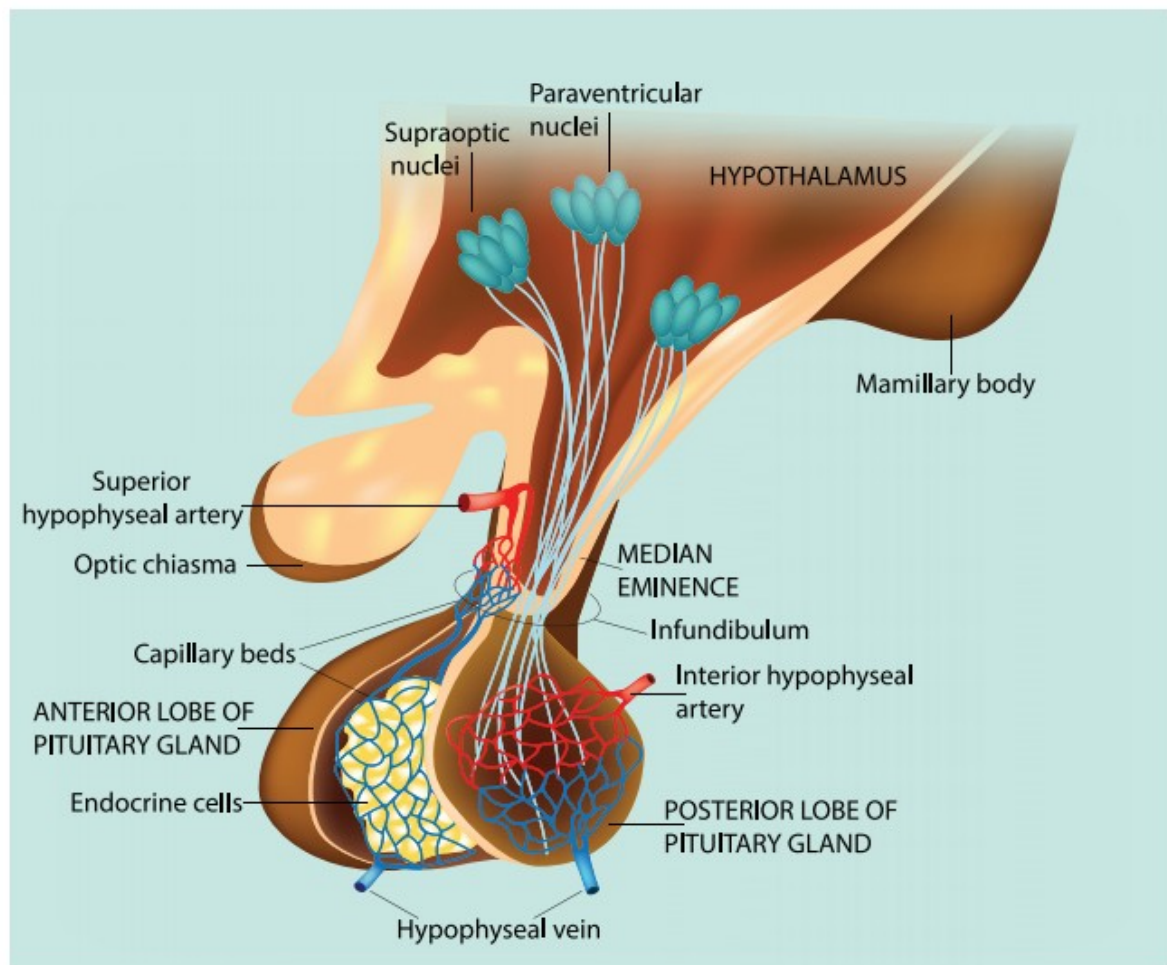
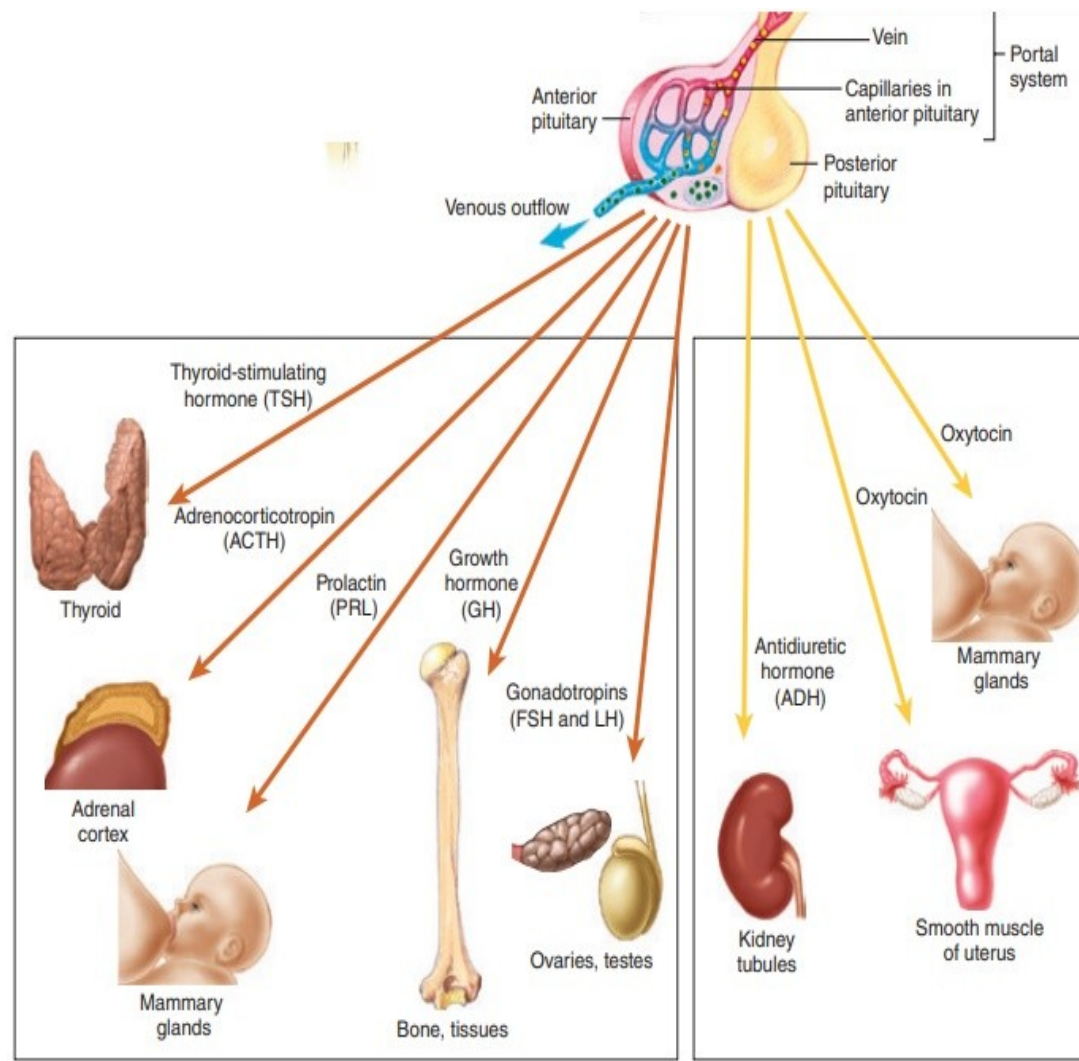
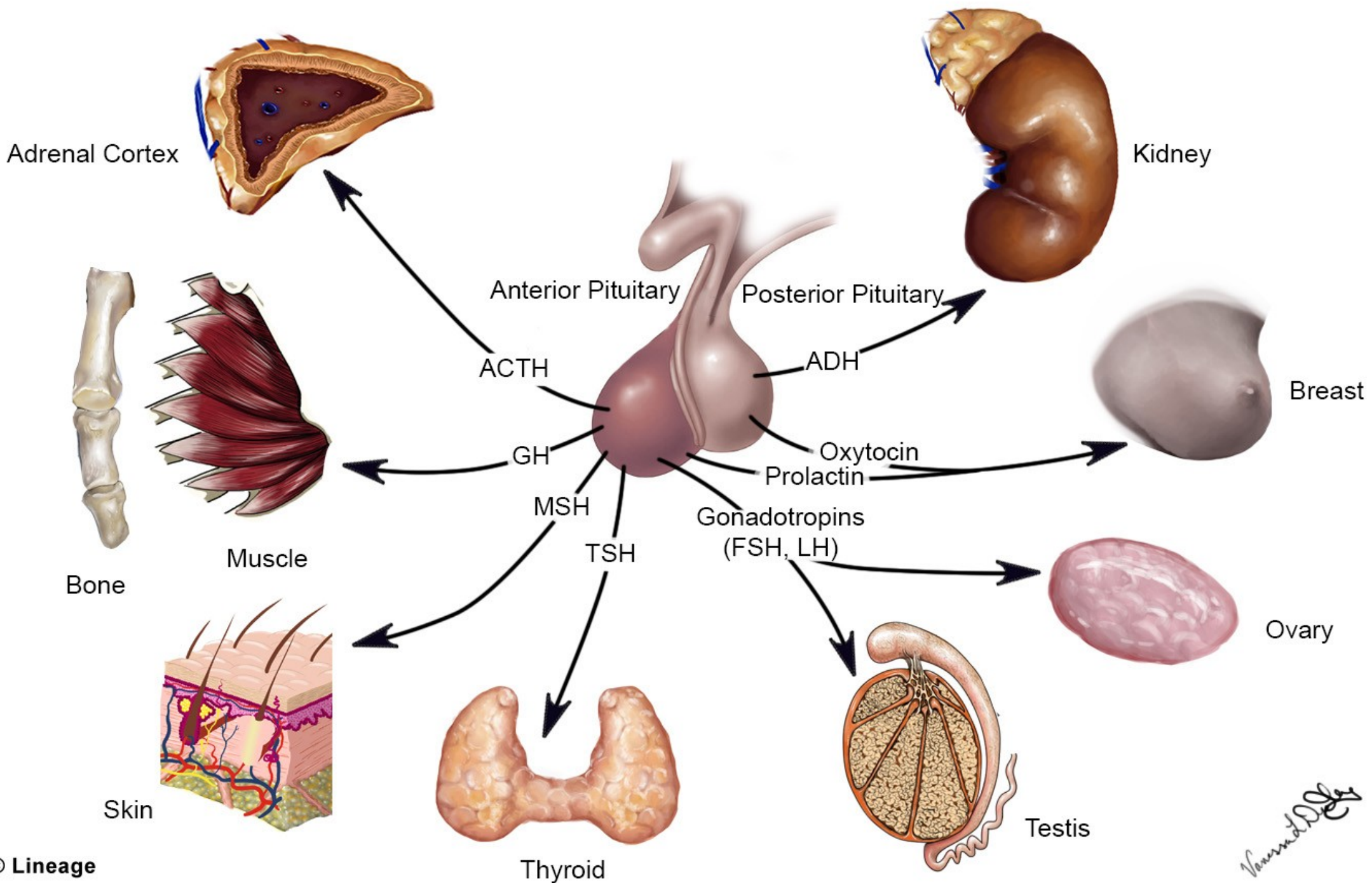


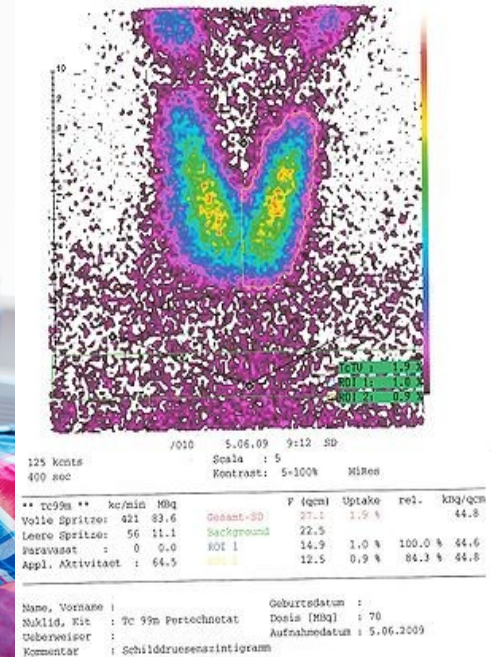
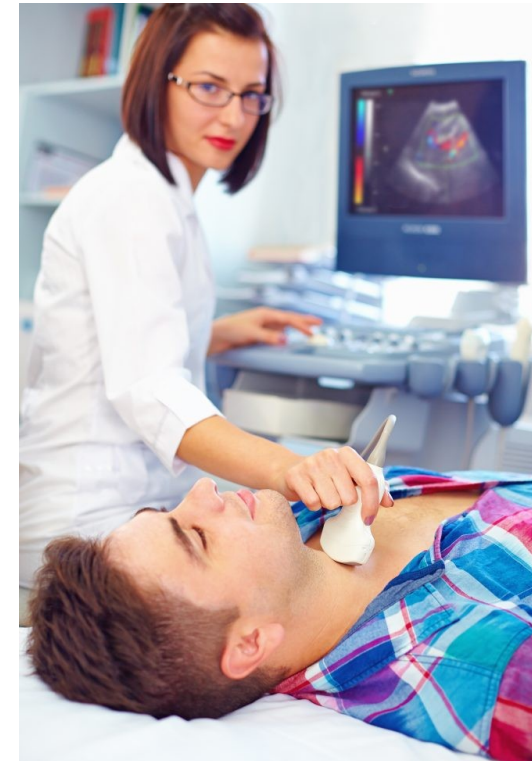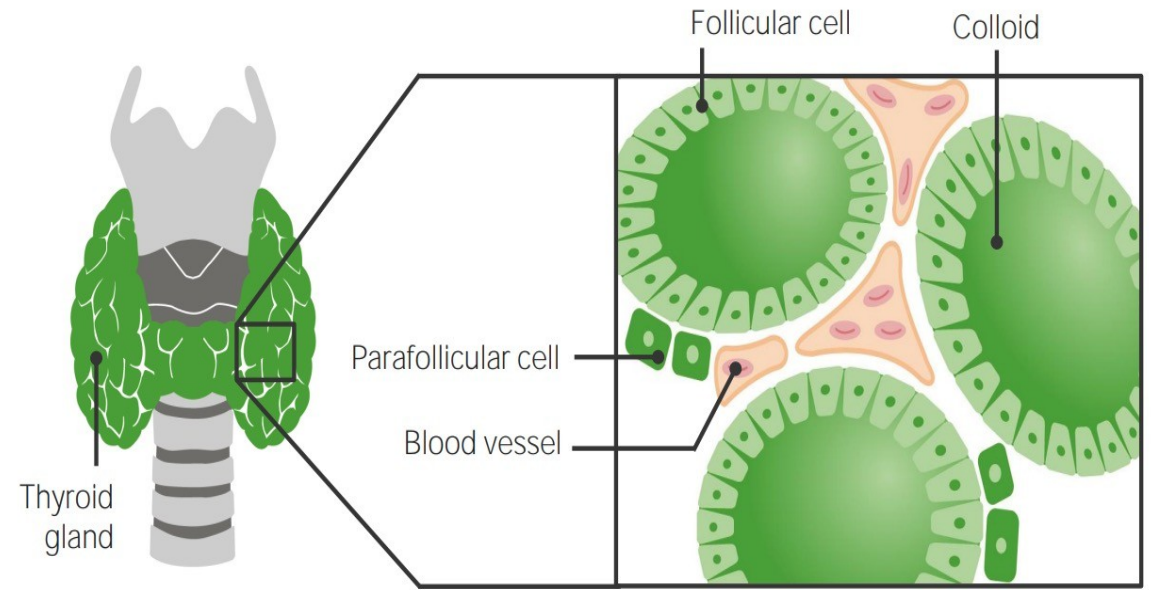
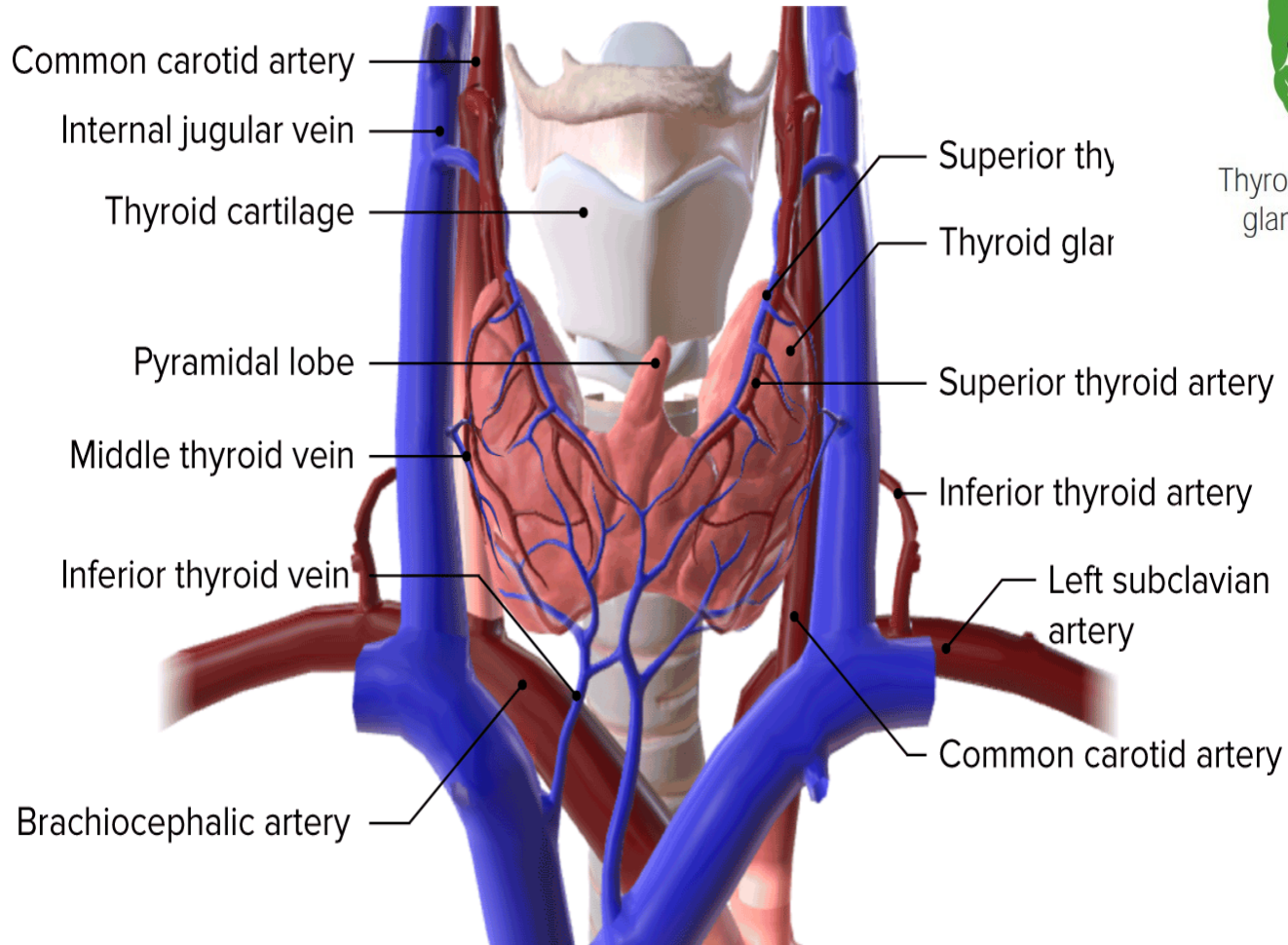
Figure.11.2 Hypothalamus and pituitary gland



The pituitary gland.



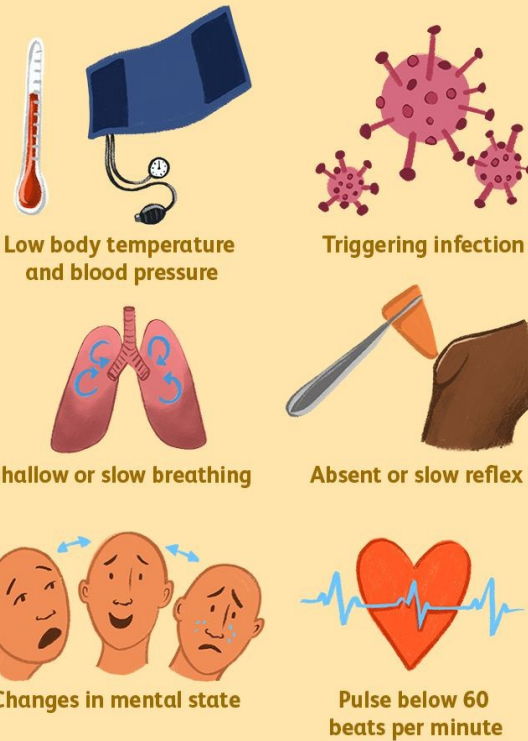
Štítná žláza



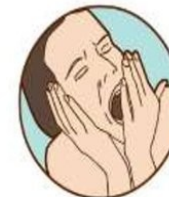Tyreopatie

Kretenismus, Myxedém

Symptoms of Myxedema



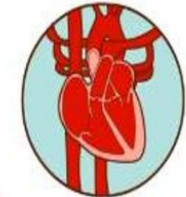Hypothyroidism symptoms



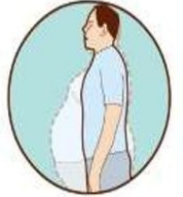feeling tired



feeling cold



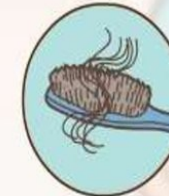heart problems



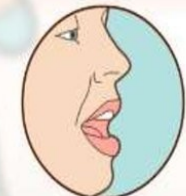increase in weight



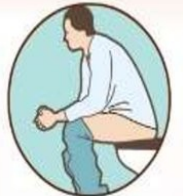depressed feelings



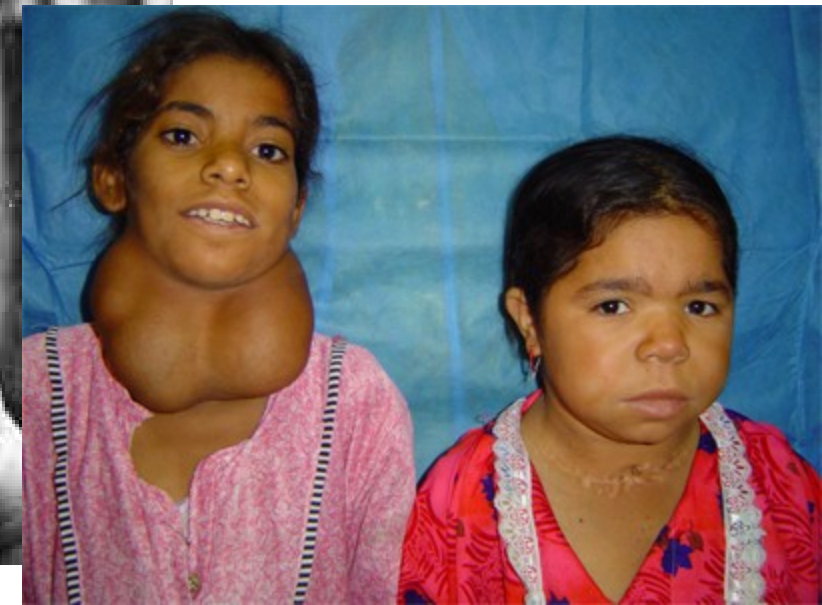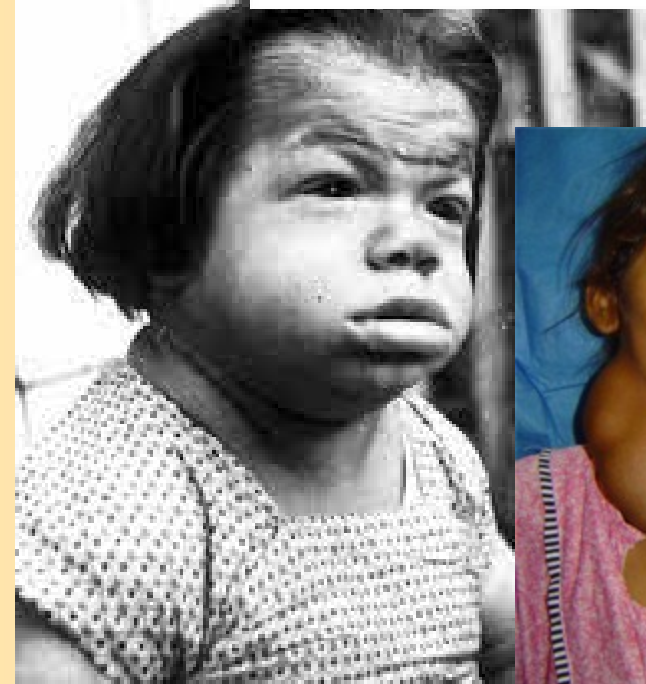hair loss



hoarse voice

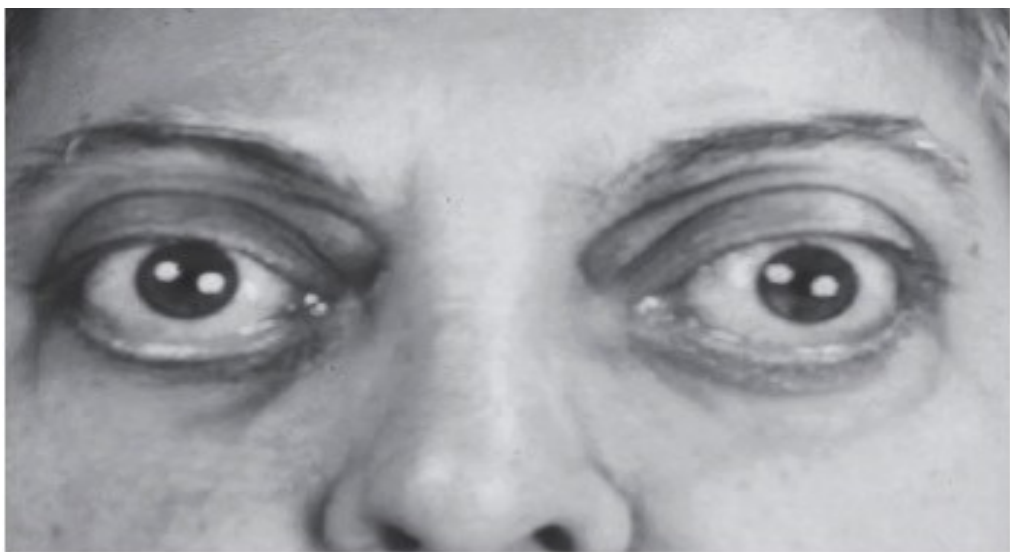

bowel problems



Tyreopatie

Graves-Basedowova choroba

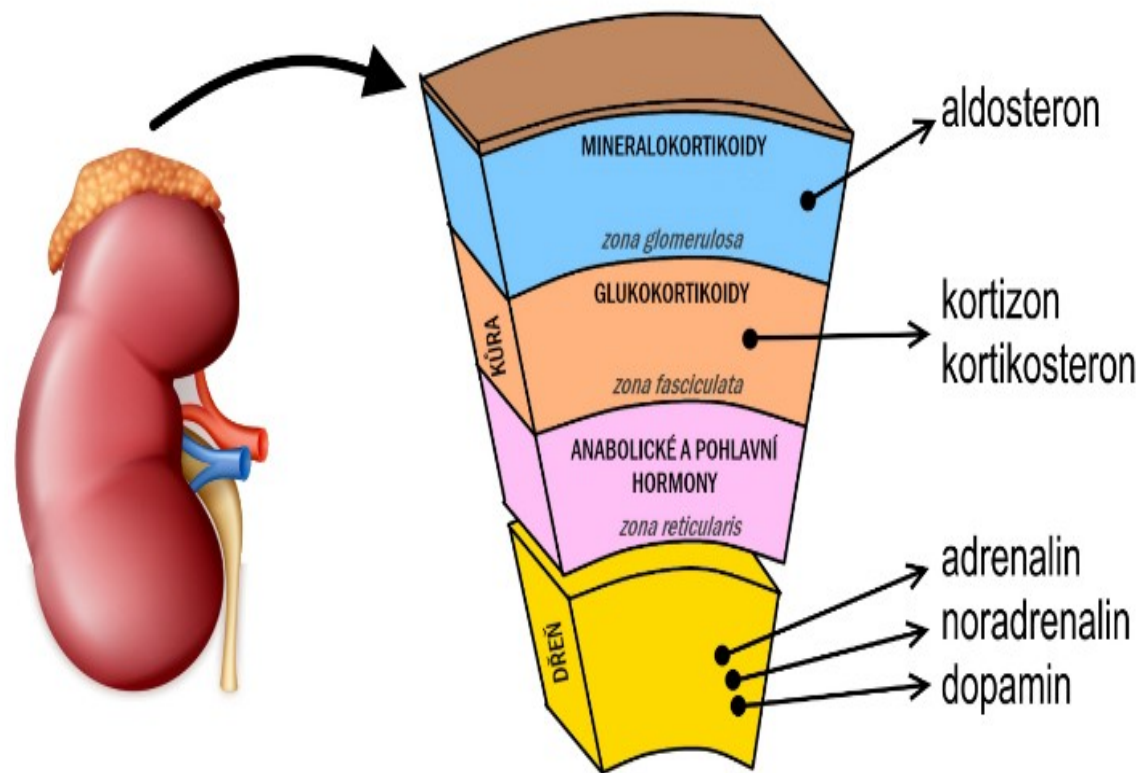
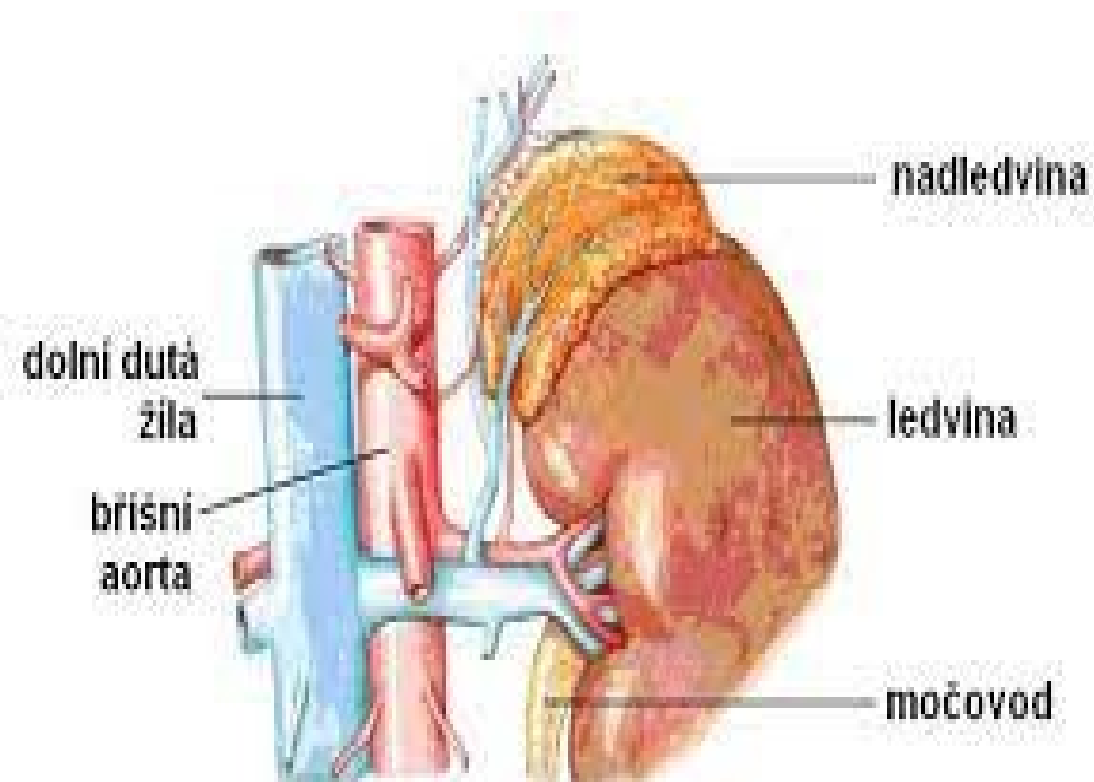


People with Graves' eye disease may develop red, bulging eyes when their eyelids retract and tissues behind the eyeball swell.

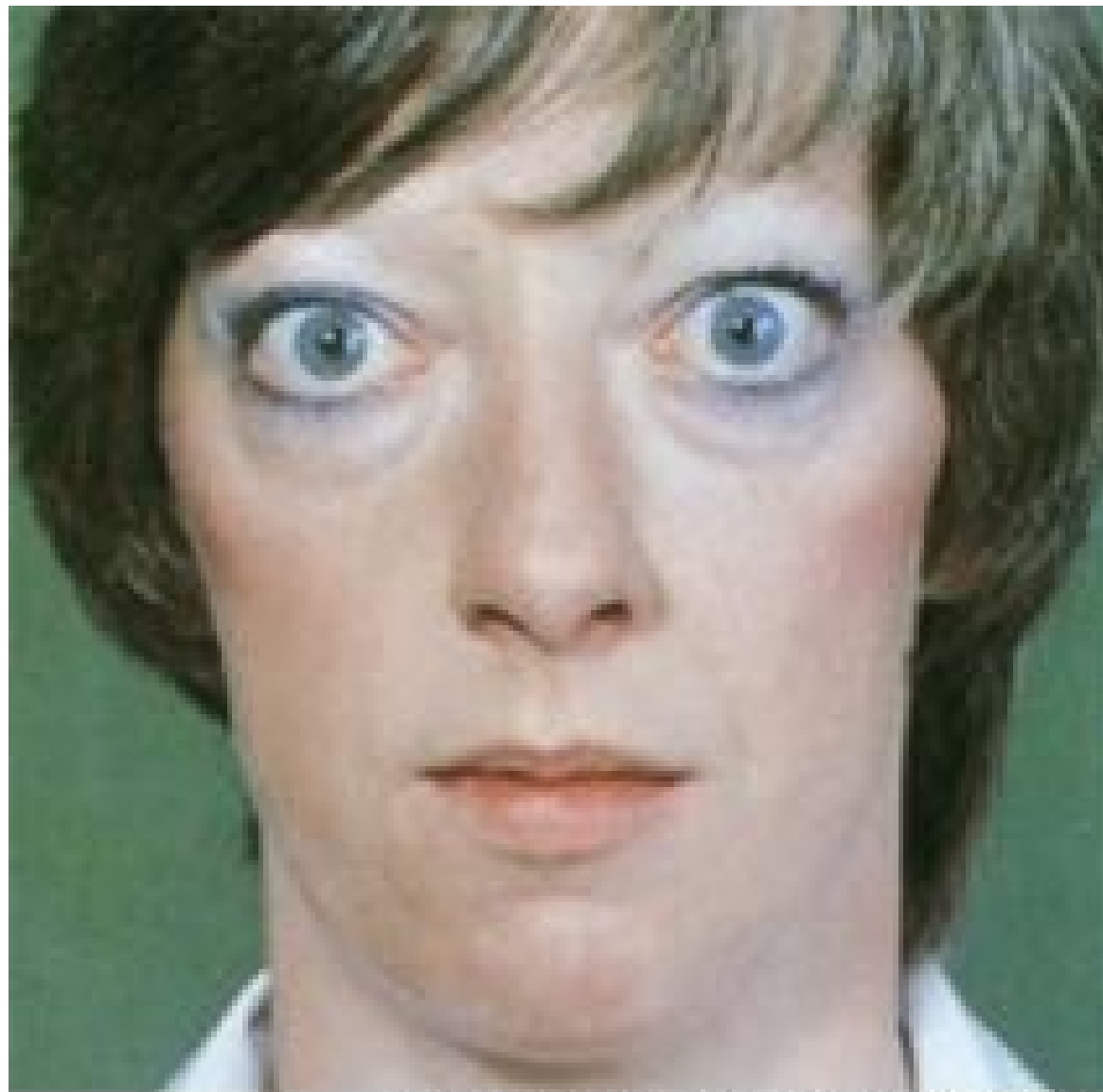

PHOTO RESEARCHERS/PHOTO ASSOCIATES

Nadledviny, glandulae suprarenales

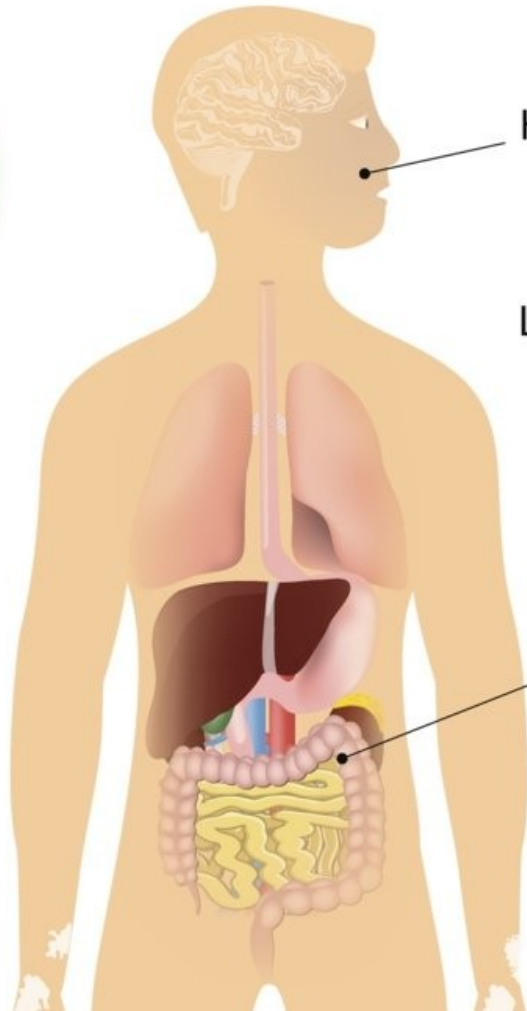


Addisonova choroba, hypokortikalismus

Addison's disease



Adrenal glands
not produce
sufficient steroid
hormones



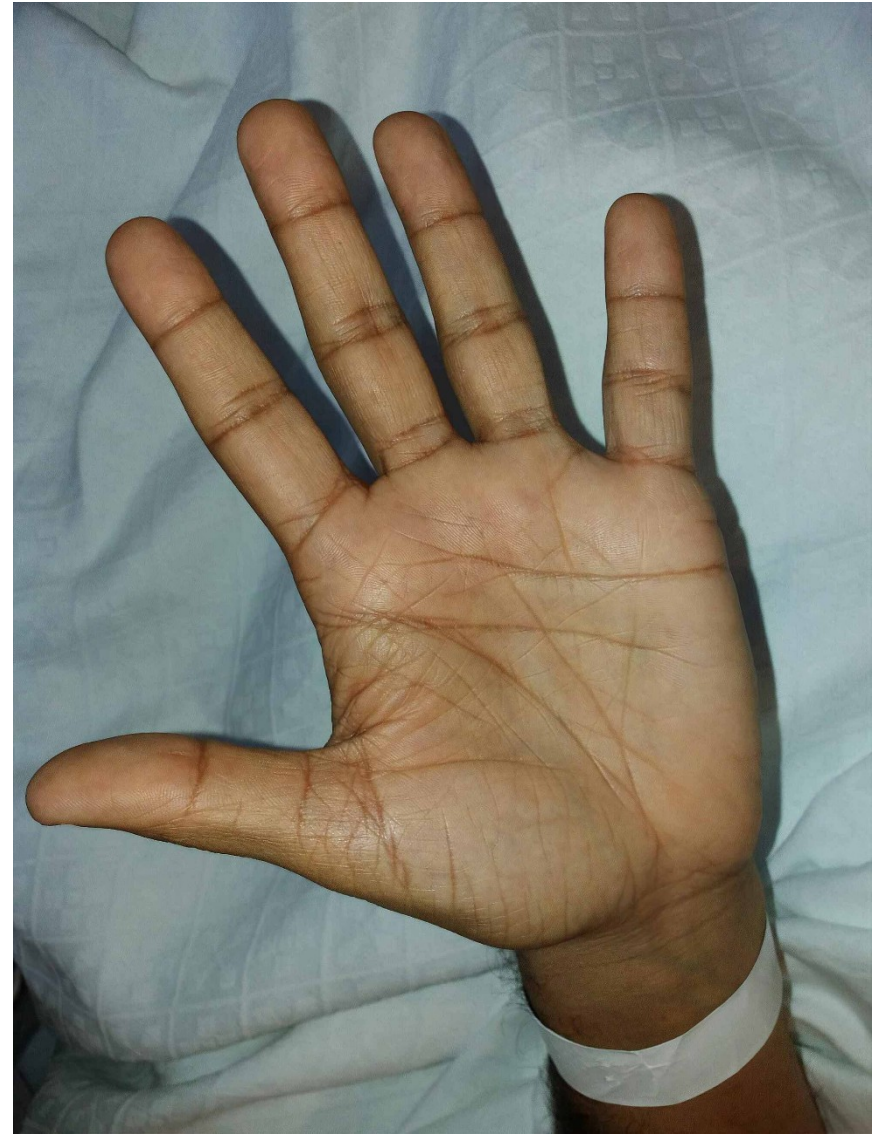Skin
Hyperpigmentation

Low blood pressure
Weakness
Weight loss

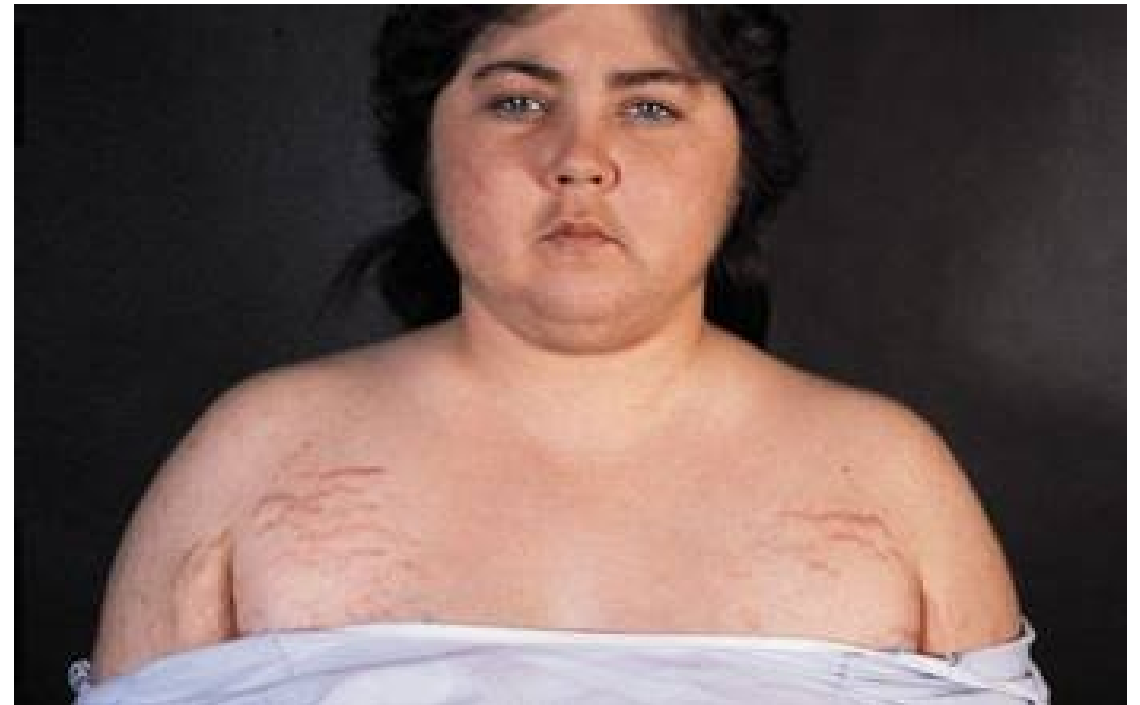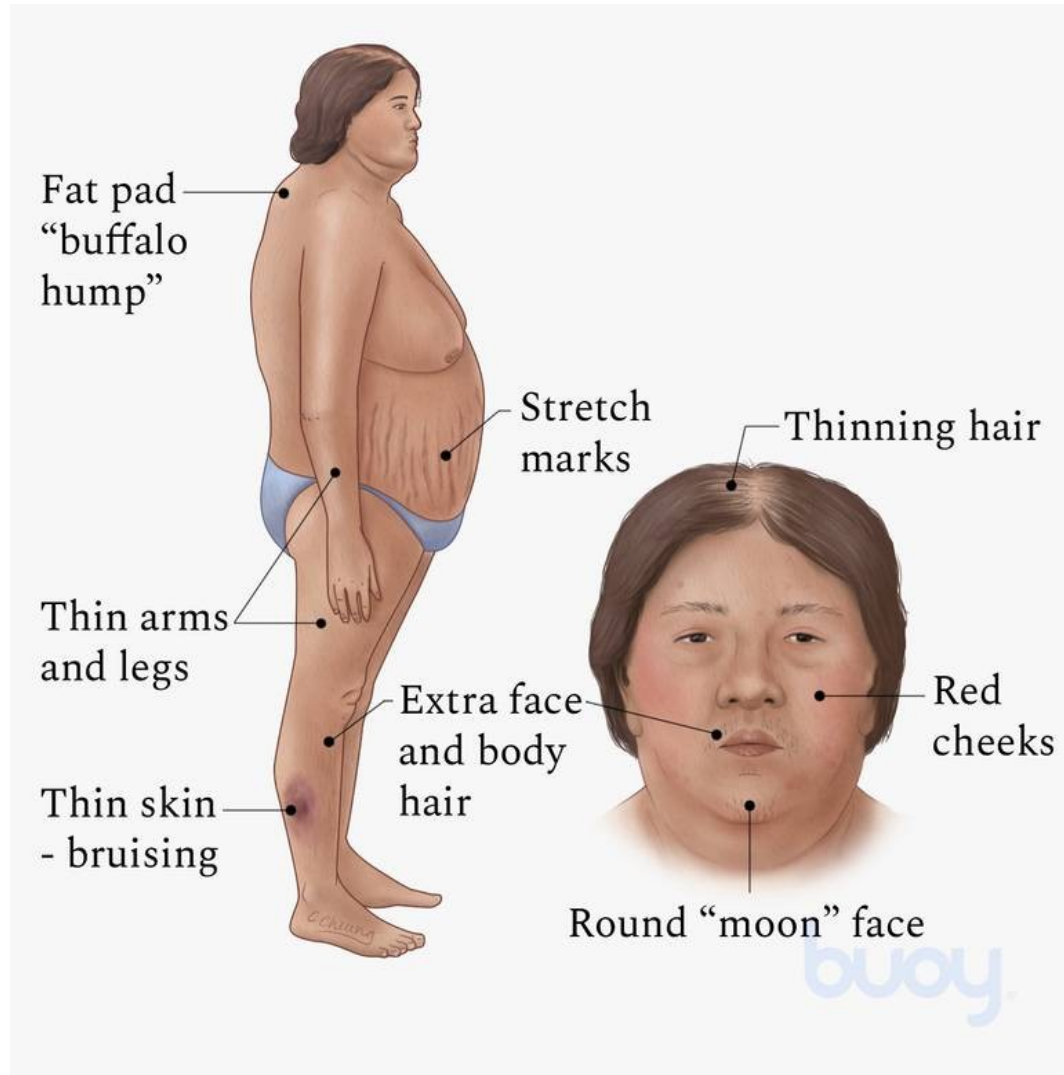
Gastrointestinal
Nausea
Diarrhea
Vomiting
Constipation
Abdominal pain

Adrenal crisis:

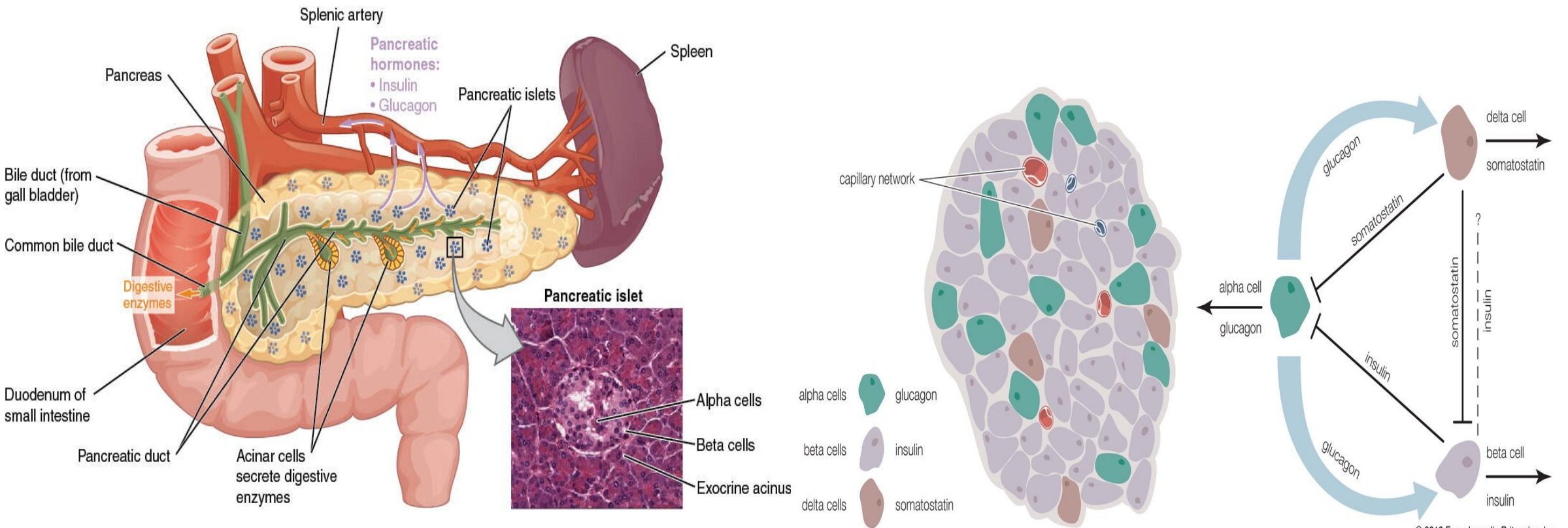
- fever;
- syncope;
- convulsions;
- hypoglycemia;



Cushingova choroba, syndrom, hyperkortikalismus

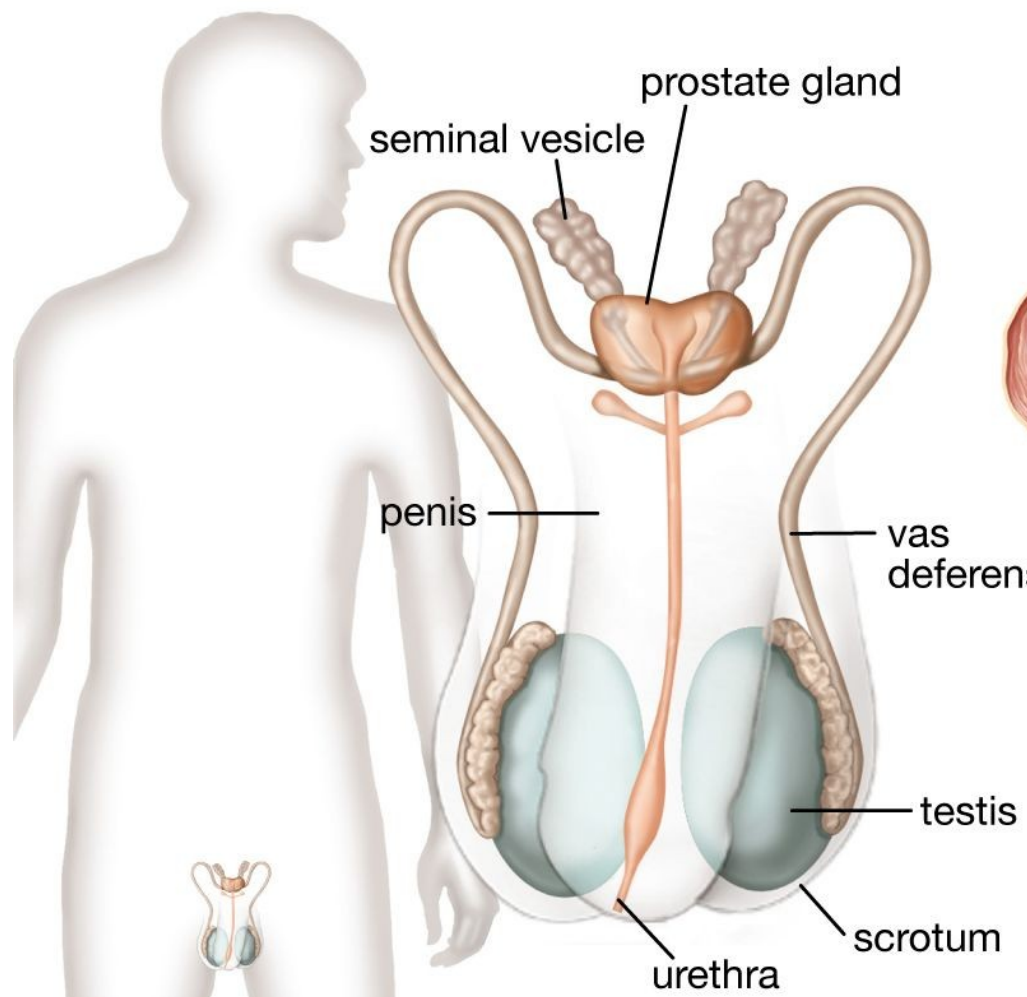


Slinivka břišní, *lat. pancreas*

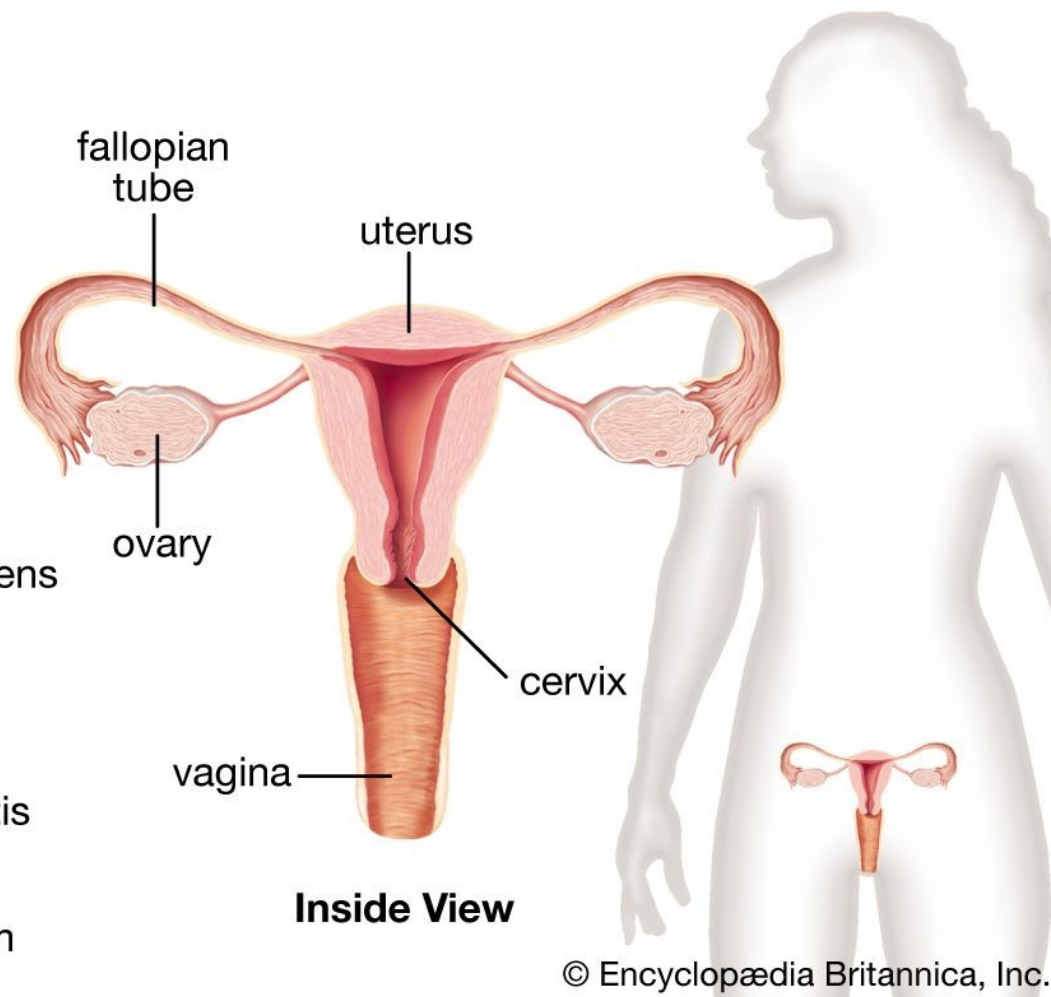


Reprodukční systém

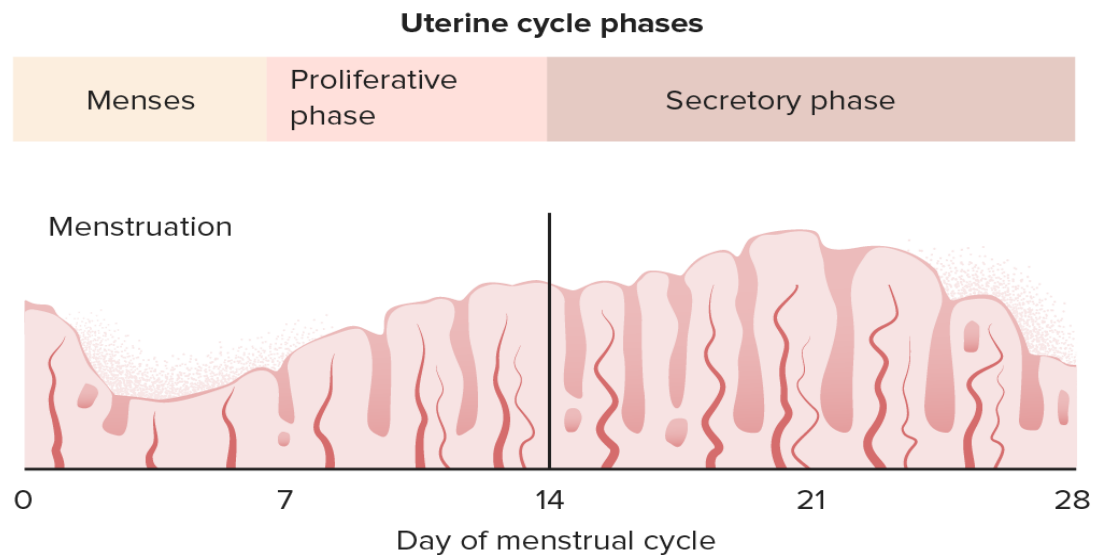
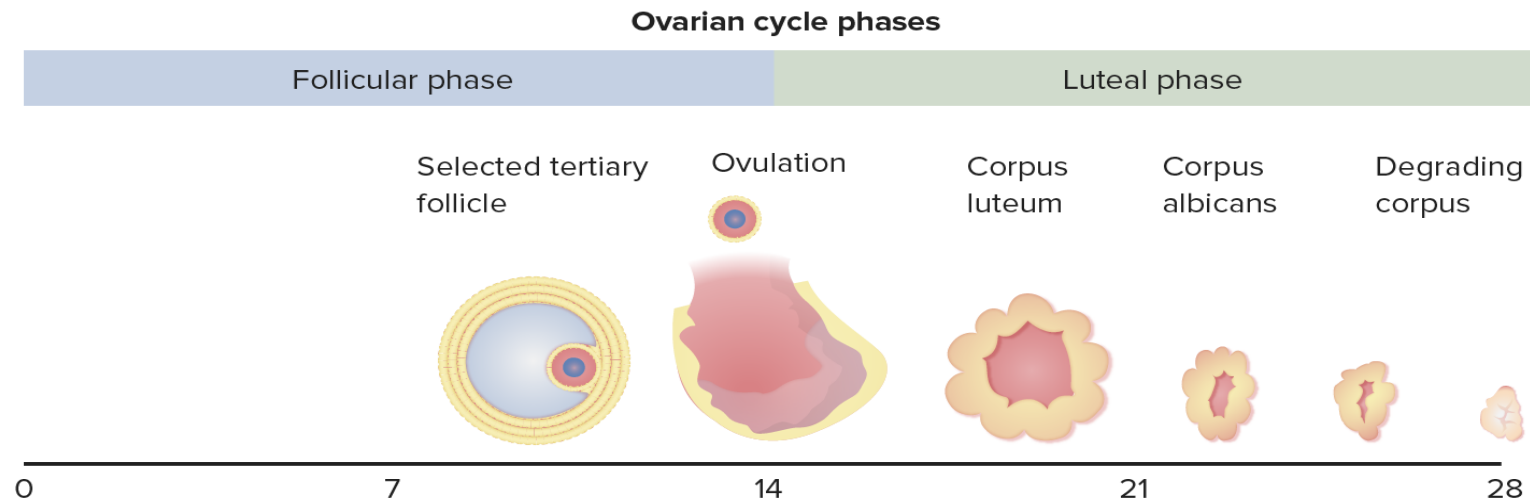
Male Reproductive System



Female Reproductive System



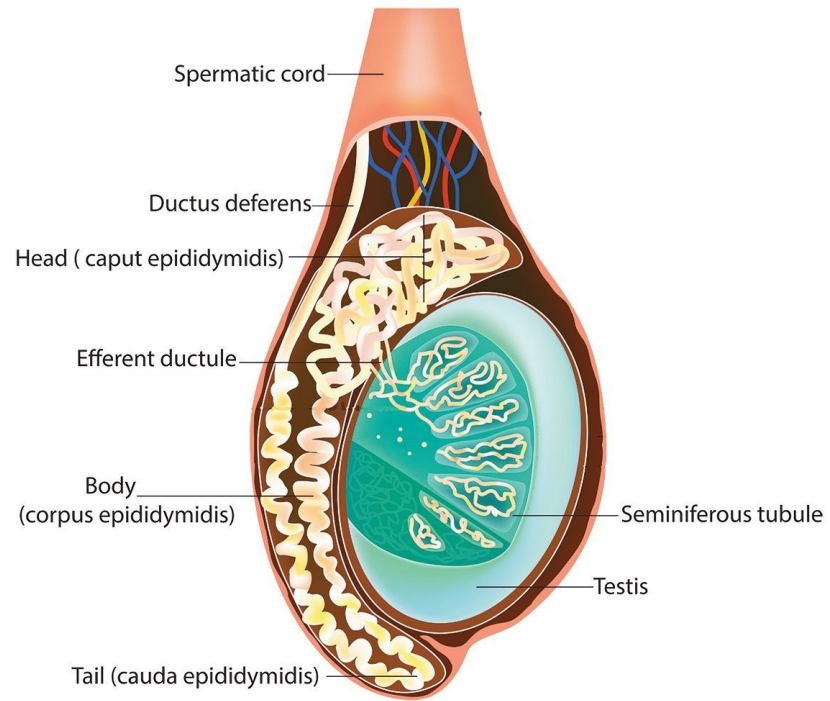
Vaječníky, lat. ovaria



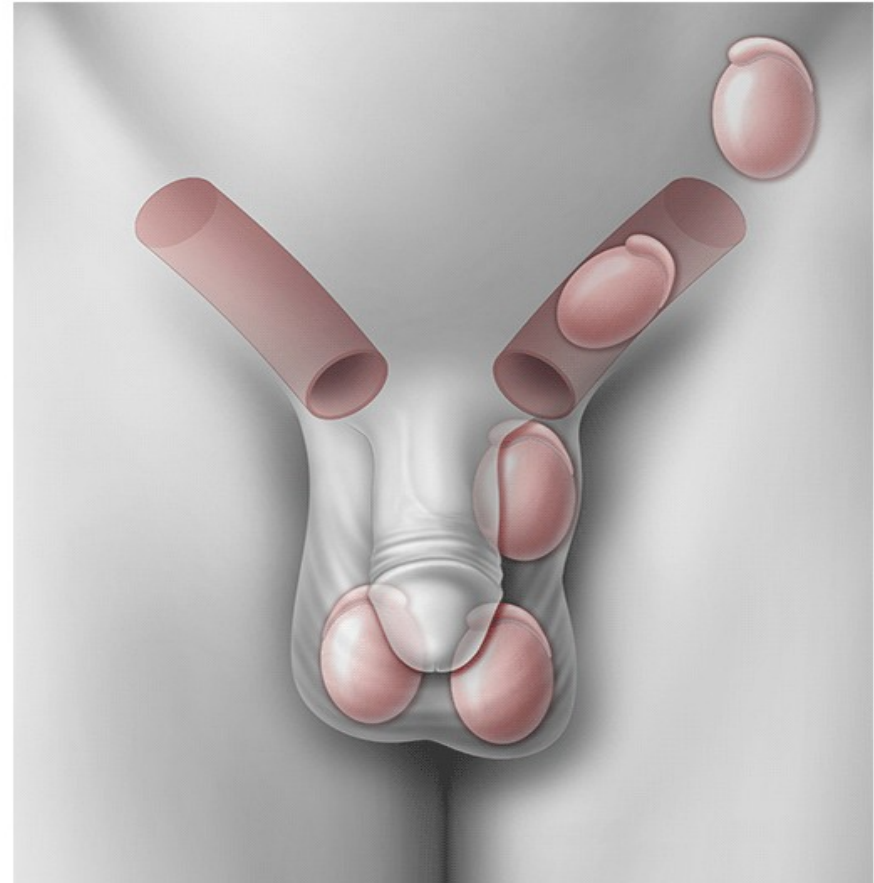
Oplození

- <https://youtu.be/5OvgQW6FG4>
- <https://youtu.be/y4HK5CTVkXM?si=YziWLXiRyo959pkL>
- https://youtu.be/Qn80_xv40ug
- <https://youtu.be/8312a32dcQc>
- https://youtu.be/usxM_dhEK6M
- <https://youtu.be/WH9ZJu4wRUE>
- <https://youtu.be/dYu-0rOnLpA>

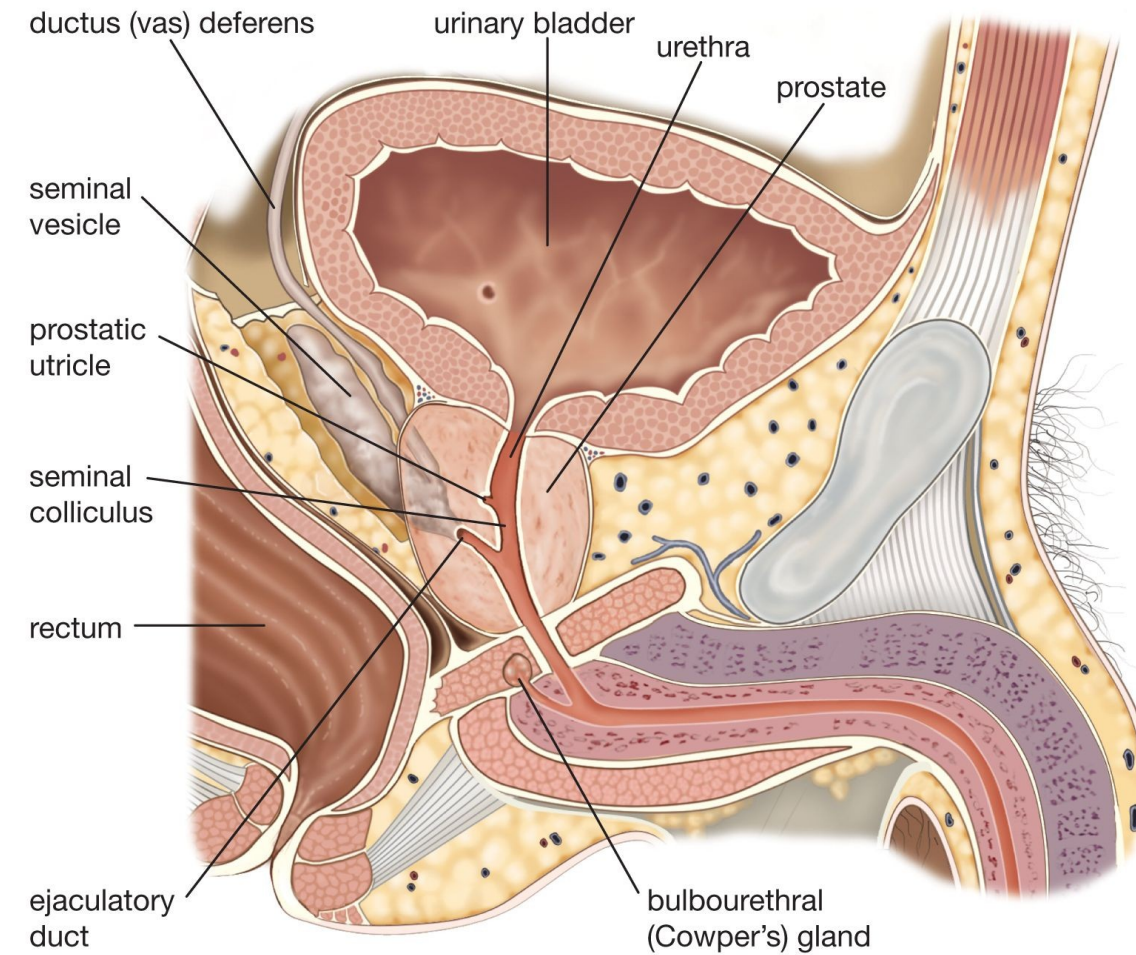
Varlata, lat. testes



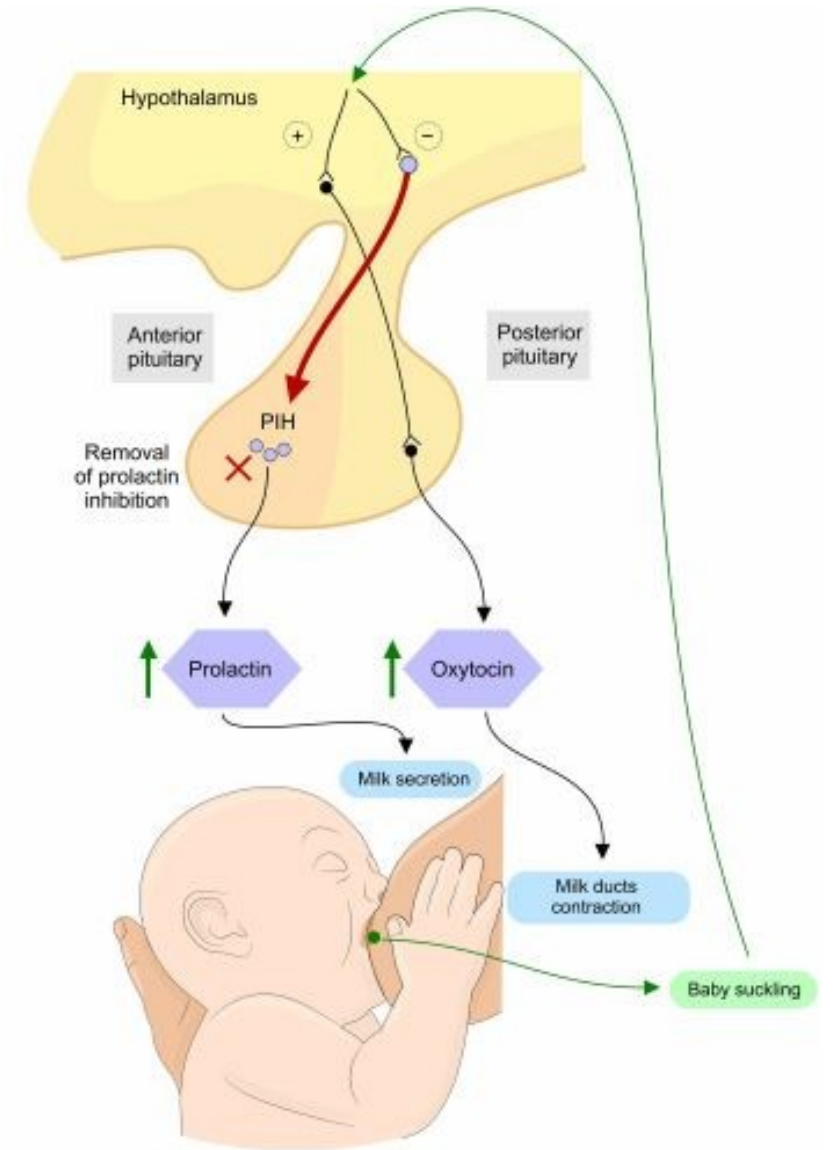
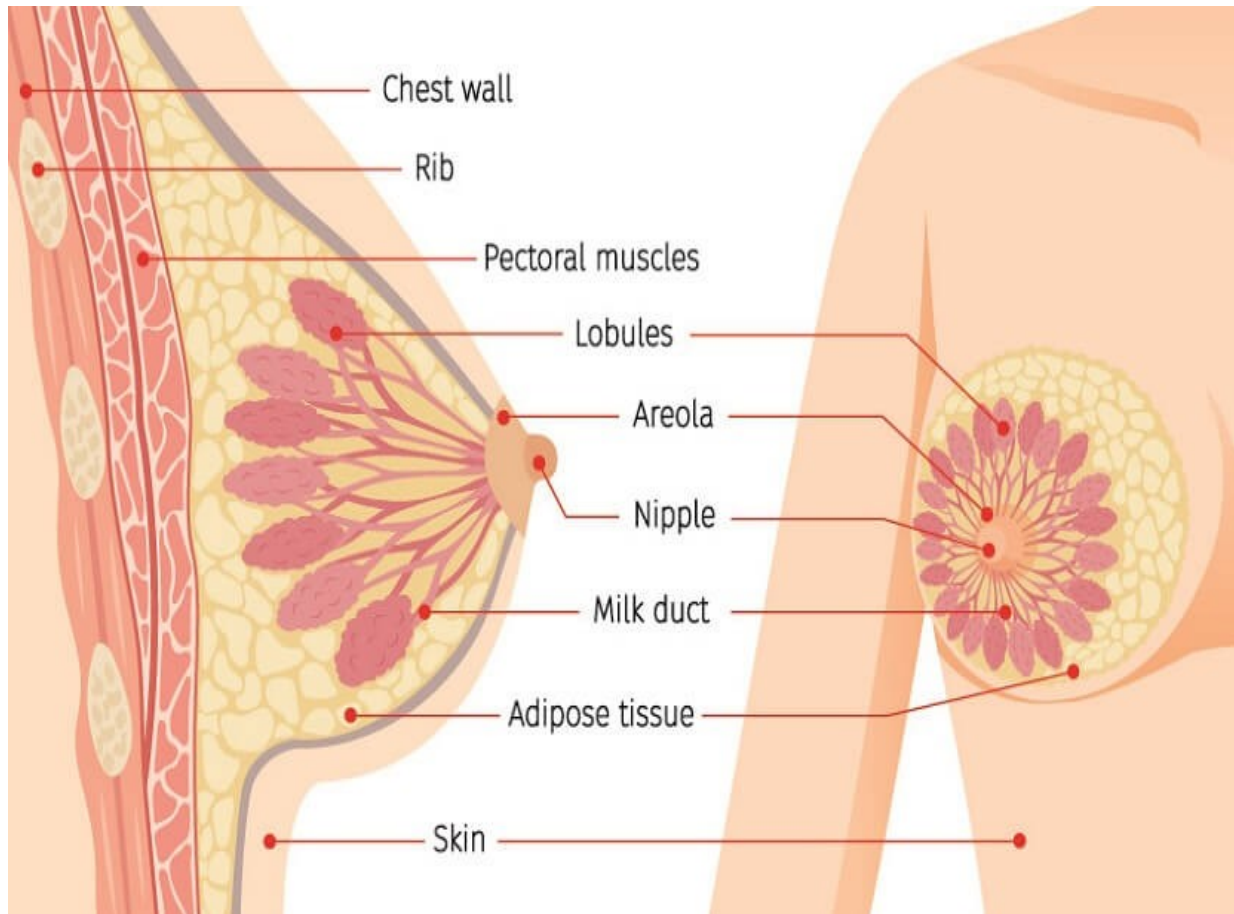
Undescended Testes



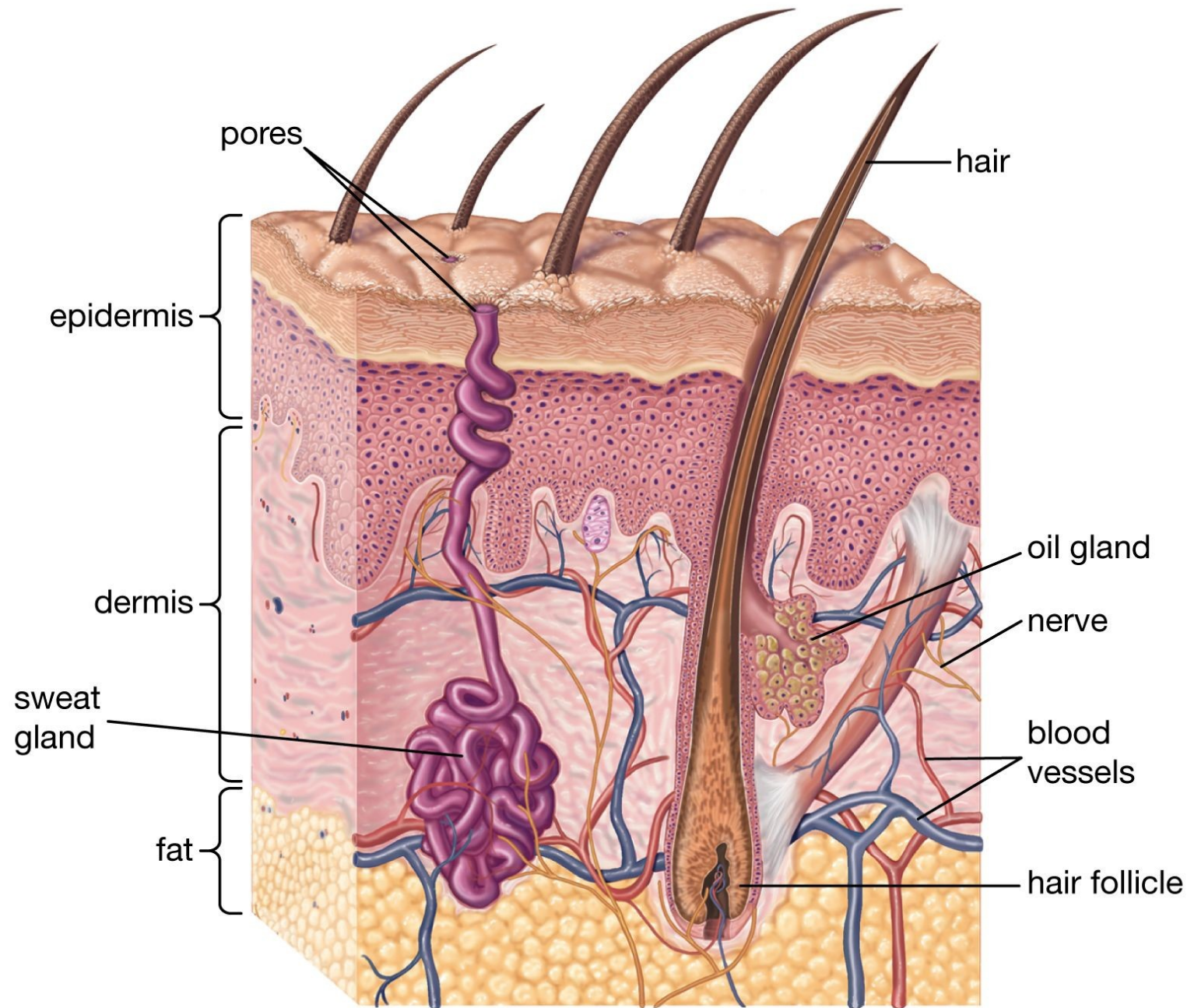
Prostata



Mléčná žláza, laktace

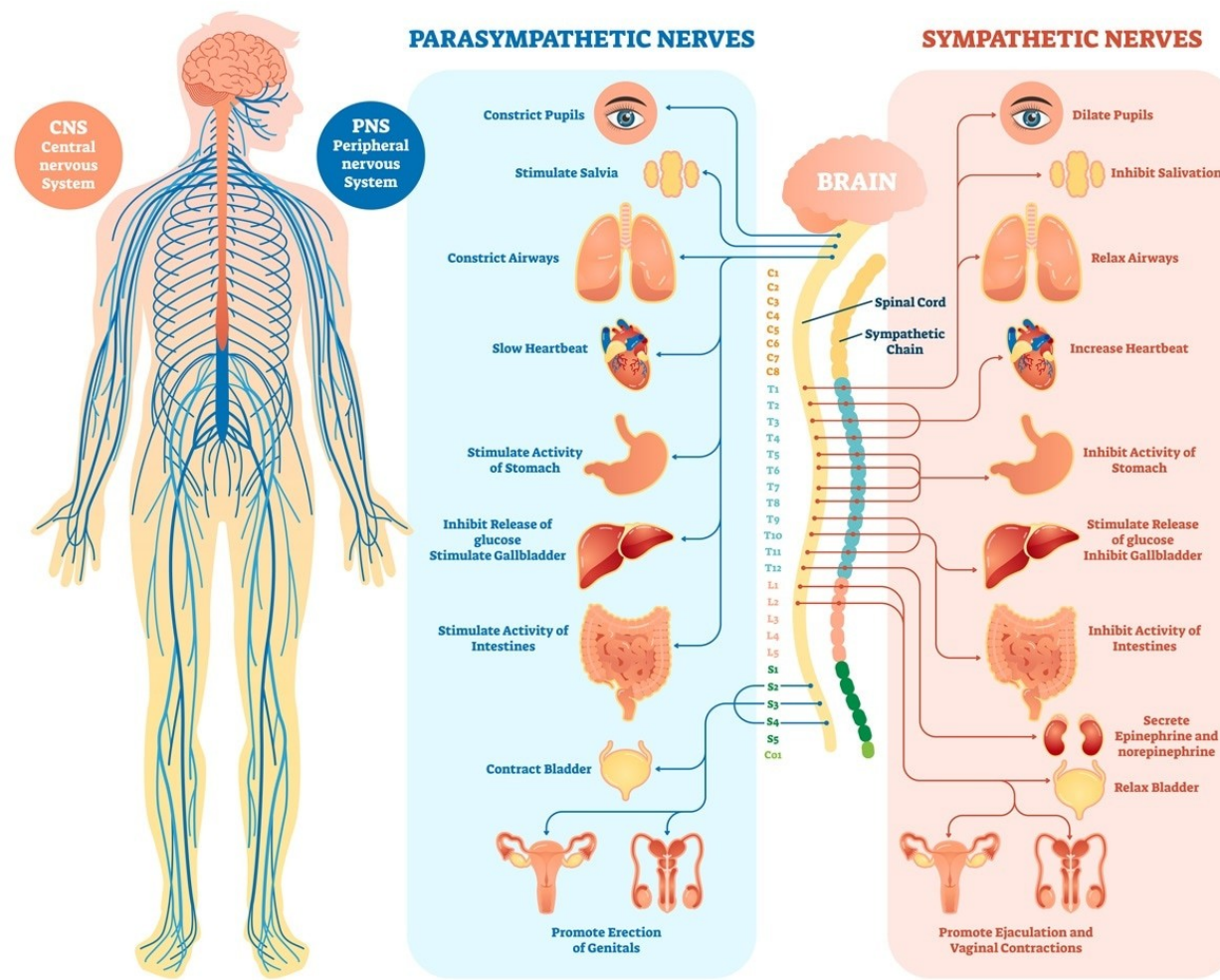


Kůže, lat. derm




Nervový systém

HUMAN NERVOUS SYSTEM



Mozek, lat. cerebrum



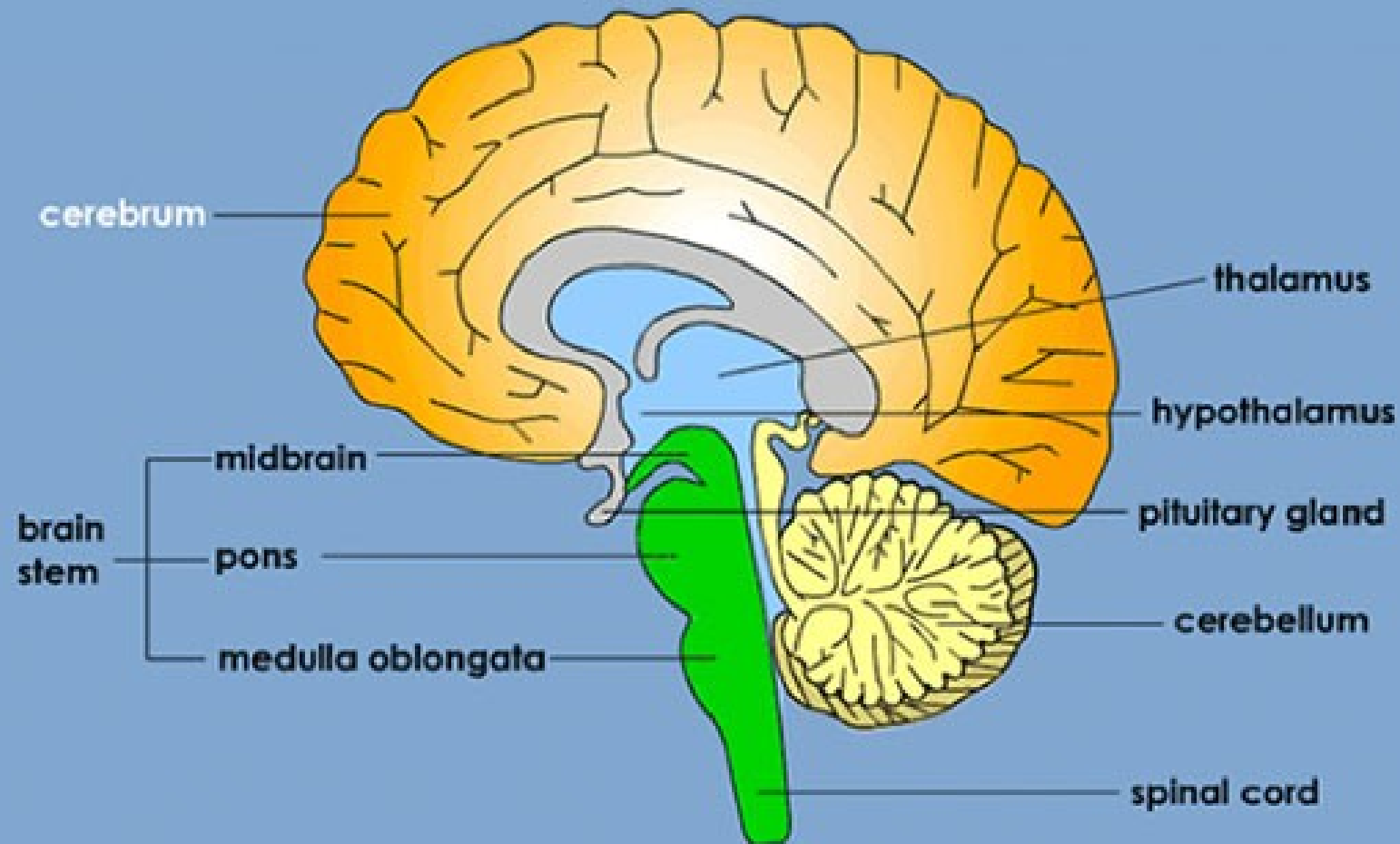
- <https://youtu.be/1-5Dc8w6Cp4>

[MozeK v 7 minutách](https://youtu.be/FczvTGluHKM)

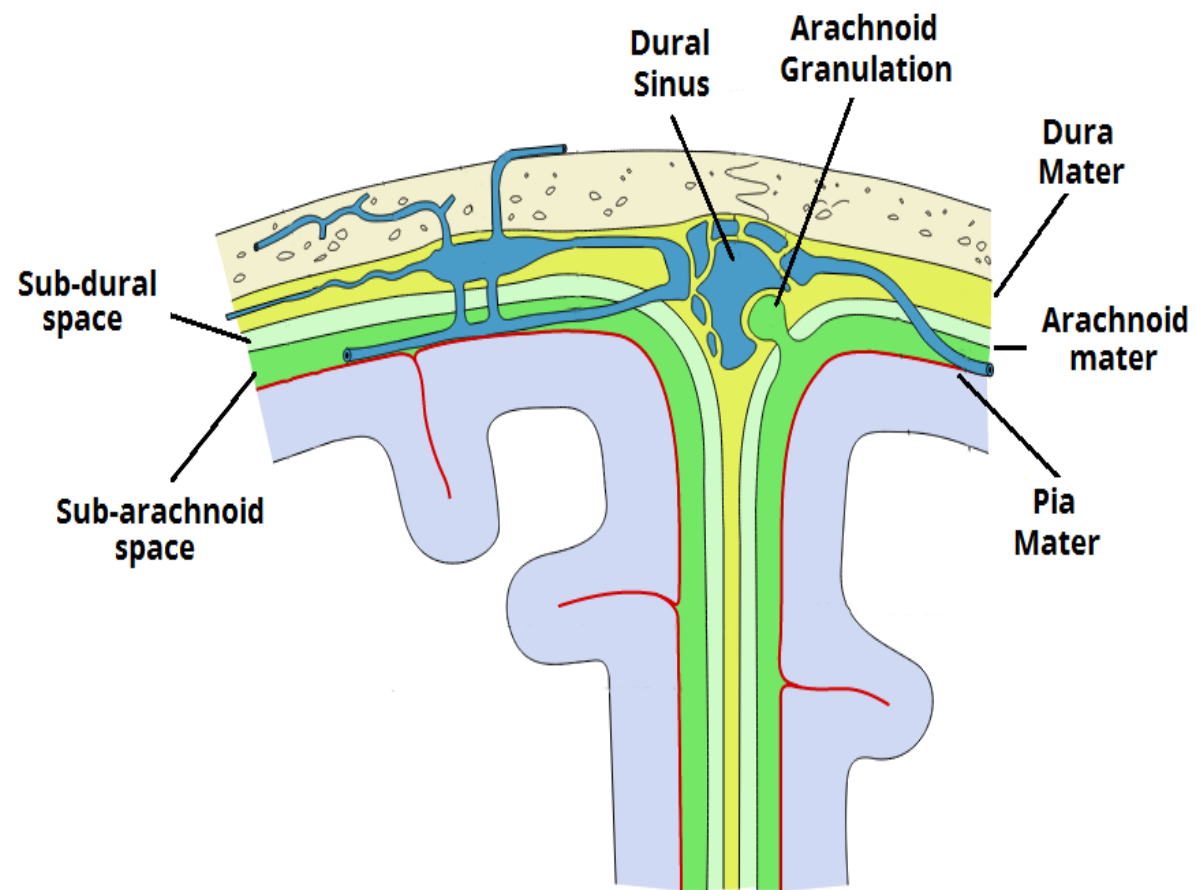
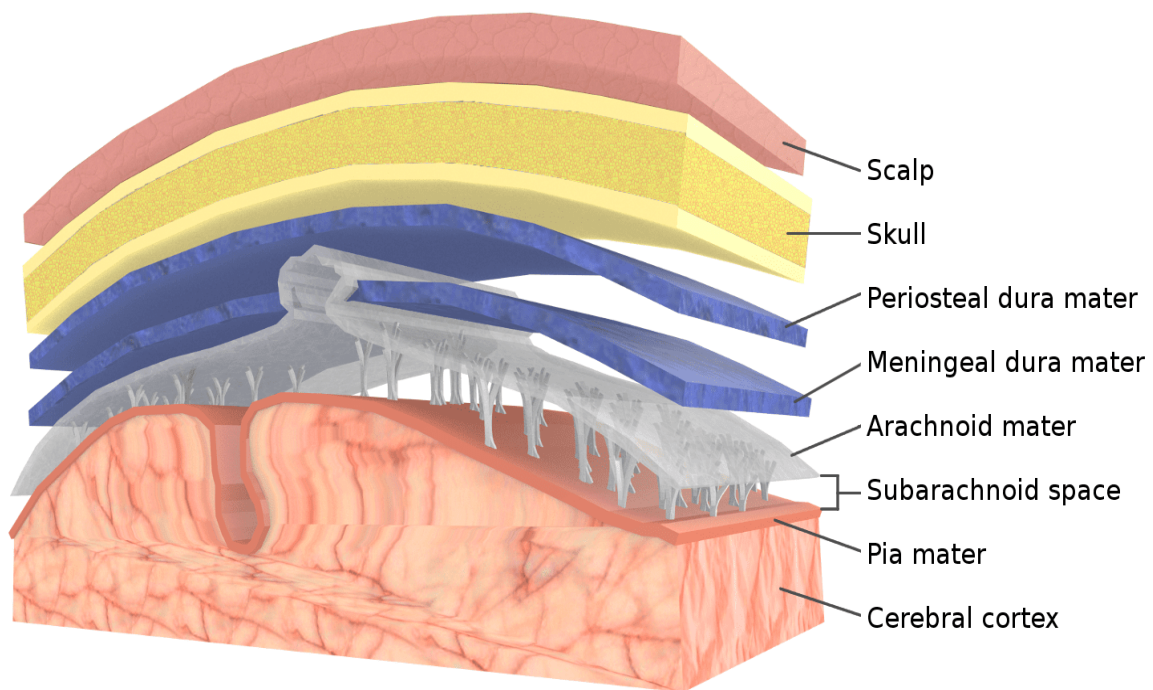
<https://youtu.be/FczvTGluHKM>

The Brain and Nervous System

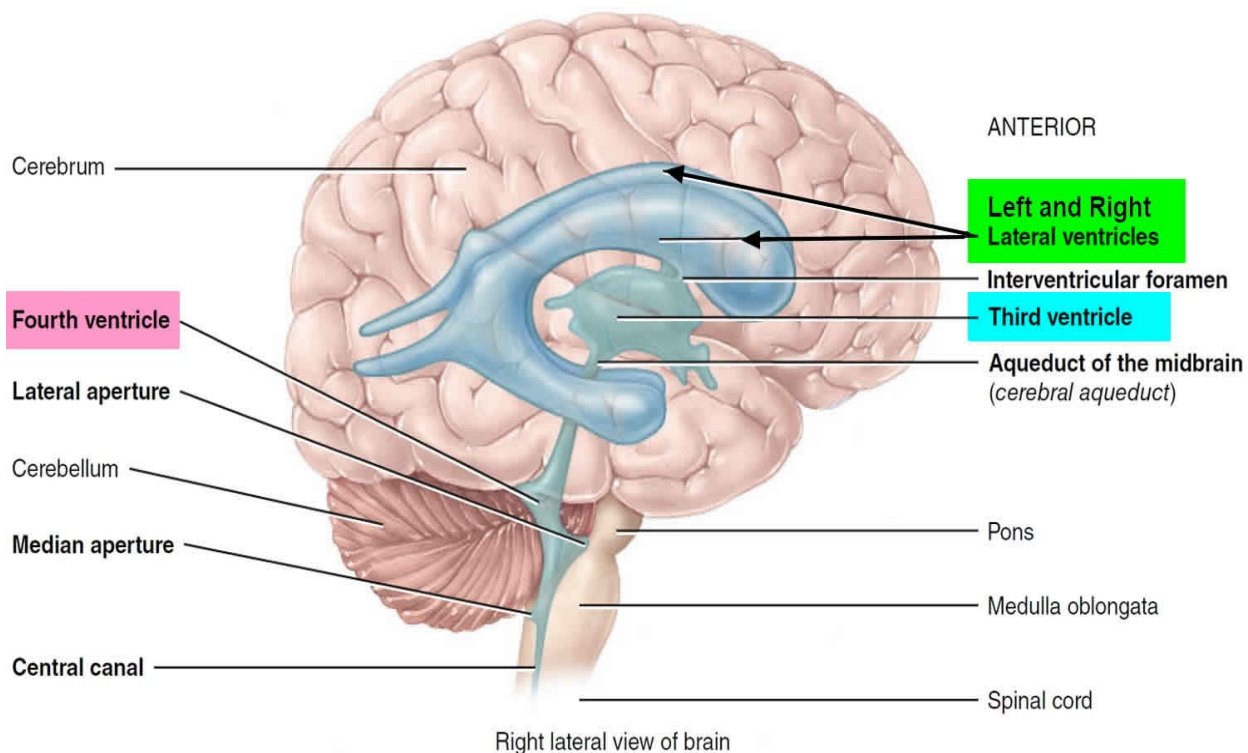
Slideshow



Mozkové obaly



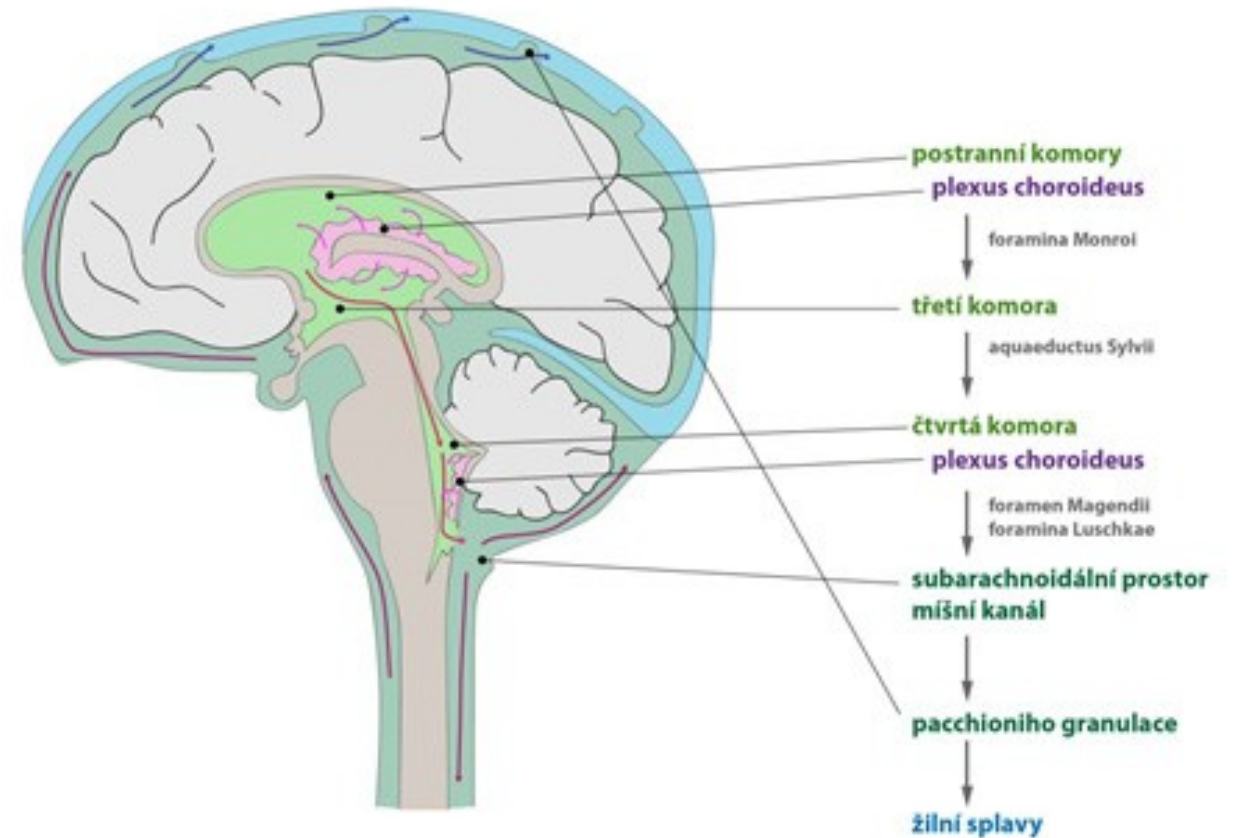
Mozek – komorový systém



- <https://youtu.be/7B1w6lDw-yM>
- Mozkomíšní mok, liquor cerebrospinalis
- <http://fb.lt.cz/skripta/regulacni-mechanismy-2-nervova-regulace/12-likvor-hematoencefalicka-a-hematolikvorova-bariera/>

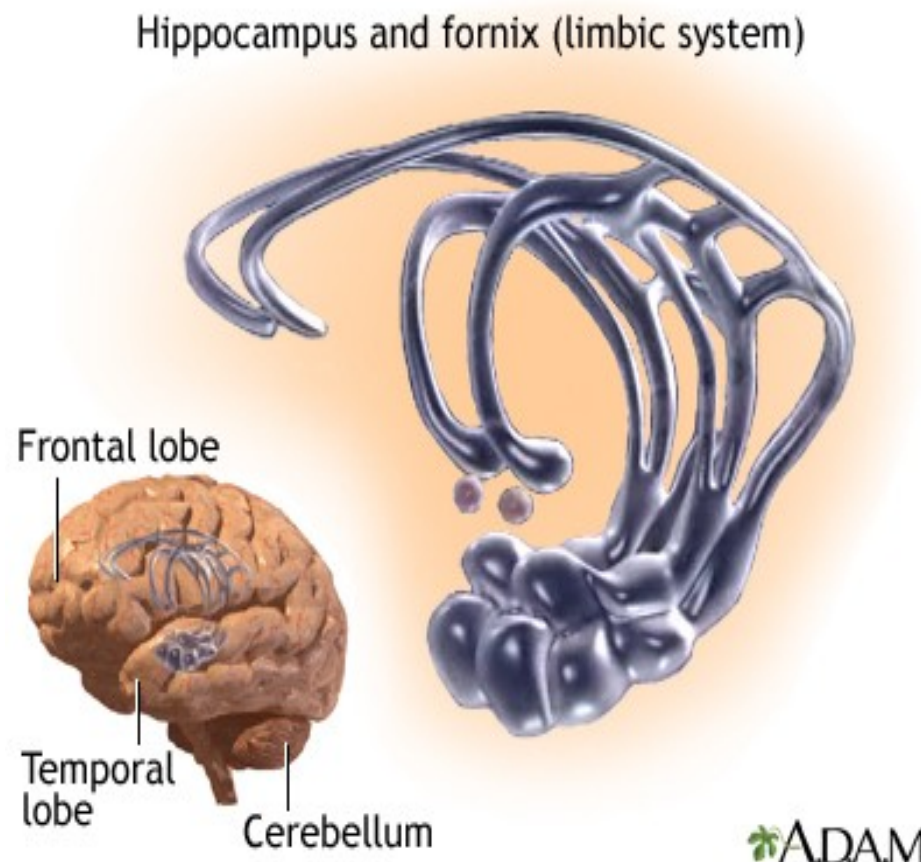
Mozkomíšní mok, lat. Liquor cerebrospinalis

- Komorový systém
- <https://youtu.be/P49ZJWpu06k>
- https://is.muni.cz/el/med/podzim2016/BLK051c/um/vysetreni_mozkomisniho_moku/pages/01-anatomicke-fyziologicke-poznatky.html



Limbický systém, lat. Limbus = čes. límec

- <https://youtu.be/mN9y2LTg8nk>
- <https://youtu.be/lcmrASRBjxk>
- Limbický systém mozku je skupina struktur, které řídí emoce a chování.
- Thalamus, hypothalamus, hipokampus a amygdala, se podílí na tvorbě dlouhodobé paměti a je úzce spojen s čichovými strukturami (s čichem).
- https://cs.wikipedia.org/wiki/Limbick%C3%BD_syst%C3%A9m



Diencephalon, mezimozek

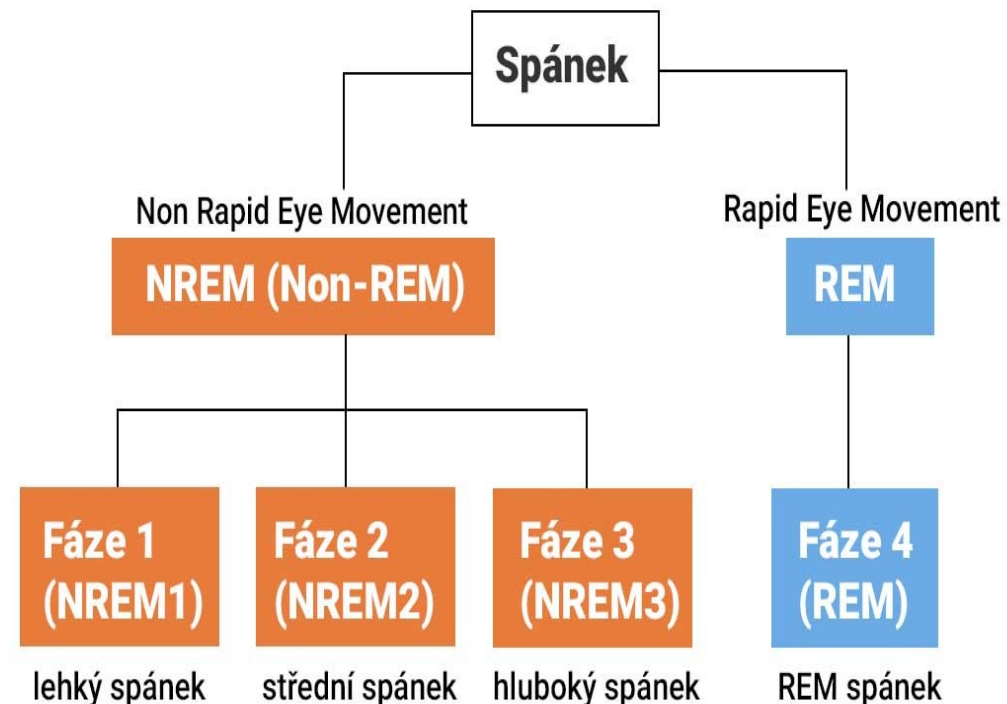
- <https://youtu.be/5BvVjjs664w>
- <https://neuroscientificallychallenged.com/posts/know-your-brain-diencephalon>
- epitalamus
- thalamus
- subthalamus
- hypotalamus.

Parkinsonismus

- <https://youtu.be/ckn9zybpYZ8>

Spánek

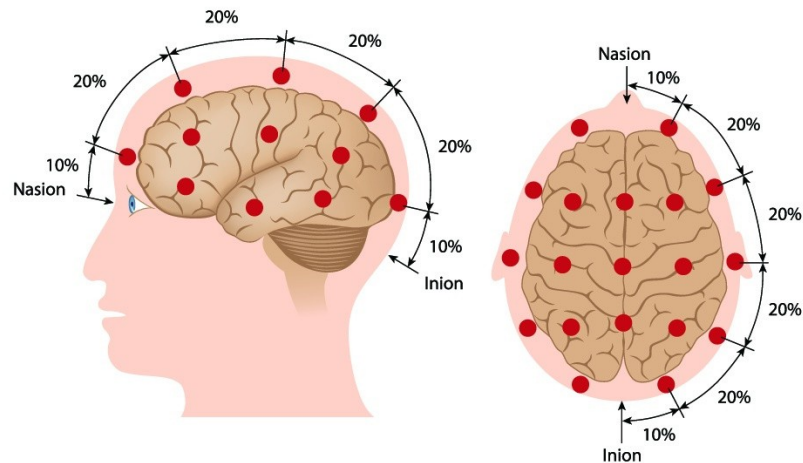
- REM
- Non REM
- <https://youtu.be/xrlqDgThA3c>
- <https://slideplayer.cz/slide/2324849/>



EEG, <https://youtu.be/3M7xj1Tomhw>

Umístění elektrod při vyšetření EEG

EEG – neinvazivní vyšetření
zápis elektrické mozkové aktivity v podobě křivek.
Elektrody rozmístěny po celé hlavě – dle systému 10/20
nazývá se podle způsobu rozměření,
kdy je obvod hlavy rozdělen na úseky po 10% a 20%

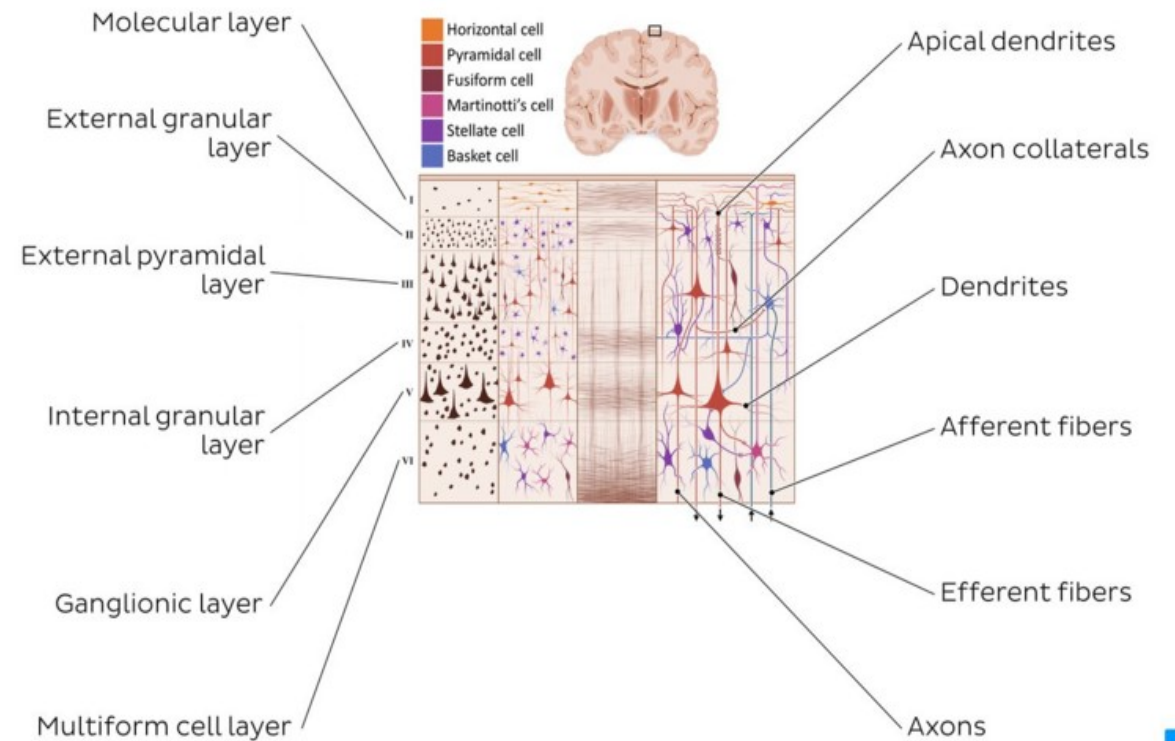
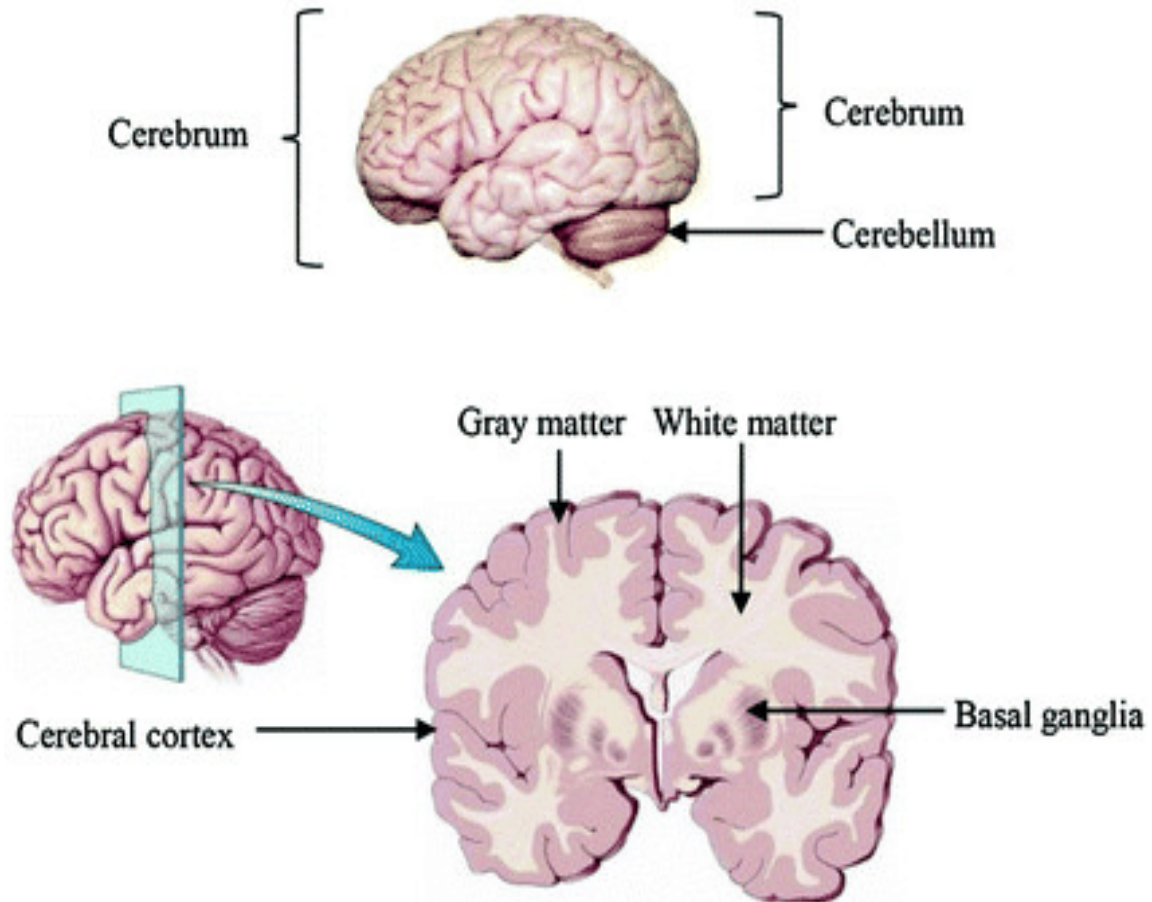


kraniometrický bod
ve střední čáře frontonazálního švu

antropometrický měrný bod
odpovídající výstupku
na kosti týlní uprostřed šupiny

- <https://www.biofeedback-rhb.cz/eeg-biofeedback/>

Mozková kůra



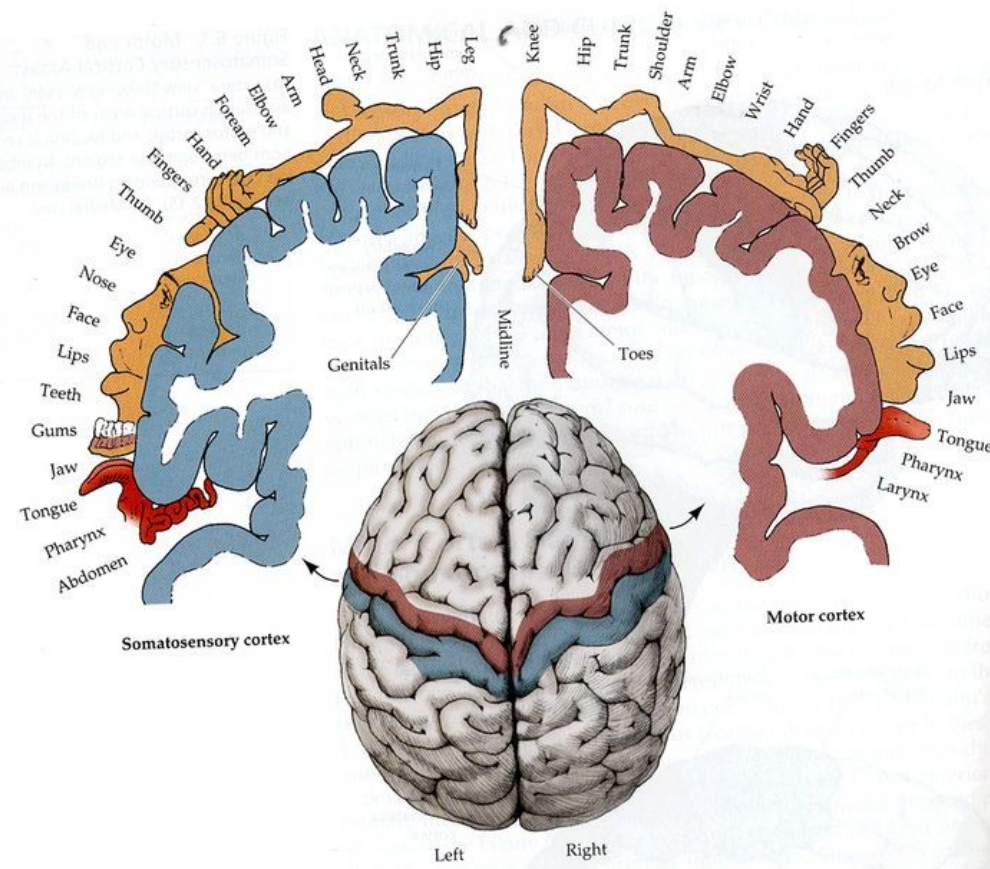
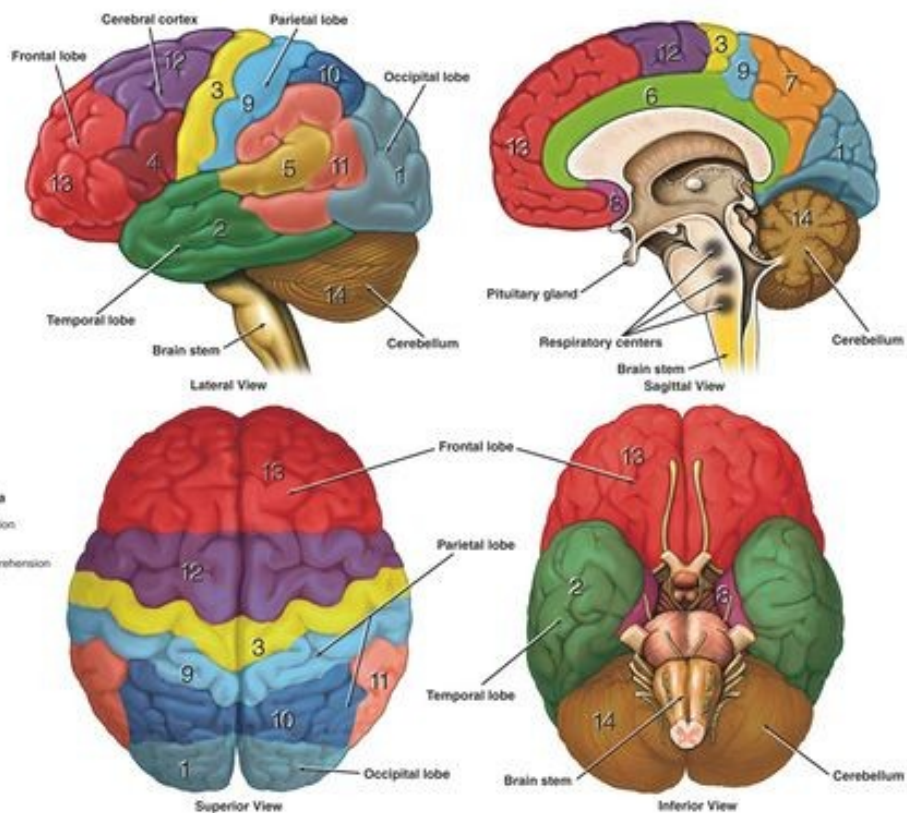
Mozková kůra

Functional Areas of the Cerebral Cortex

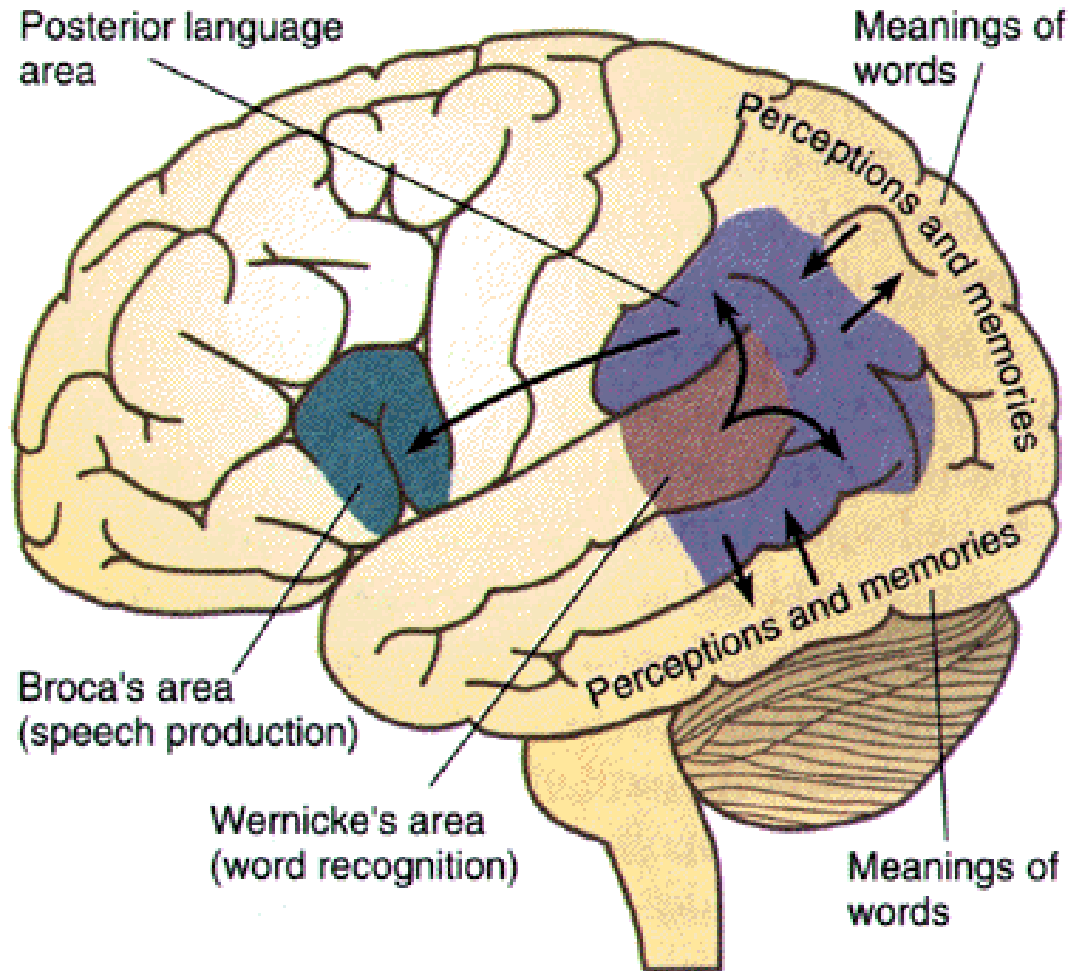
- 1 **Visual Area:**
Sight
Image recognition
Image perception
- 2 **Association Area**
Short-term memory
Equilibrium
Emotion
- 3 **Motor Function Area**
Initiation of voluntary muscles
- 4 **Broca's Area**
Muscles of speech
- 5 **Auditory Area**
Hearing
- 6 **Emotional Area**
Pain
Hunger
"Fight or flight" response
- 7 **Sensory Association Area**
- 8 **Olfactory Area**
Smelling
- 9 **Sensory Area**
Sensation from muscles and skin
- 10 **Somatosensory Association Area**
Evaluation of weight, texture, temperature, etc. for object recognition
- 11 **Wernicke's Area**
Written and spoken language comprehension
- 12 **Motor Function Area**
Eye movement and orientation
- 13 **Higher Mental Functions**
Concentration
Planning
Judgment
Emotional expression
Creativity
Inhibition

Functional Areas of the Cerebellum

- 14 **Motor Functions**
Coordination of movement
Balance and equilibrium
Posture

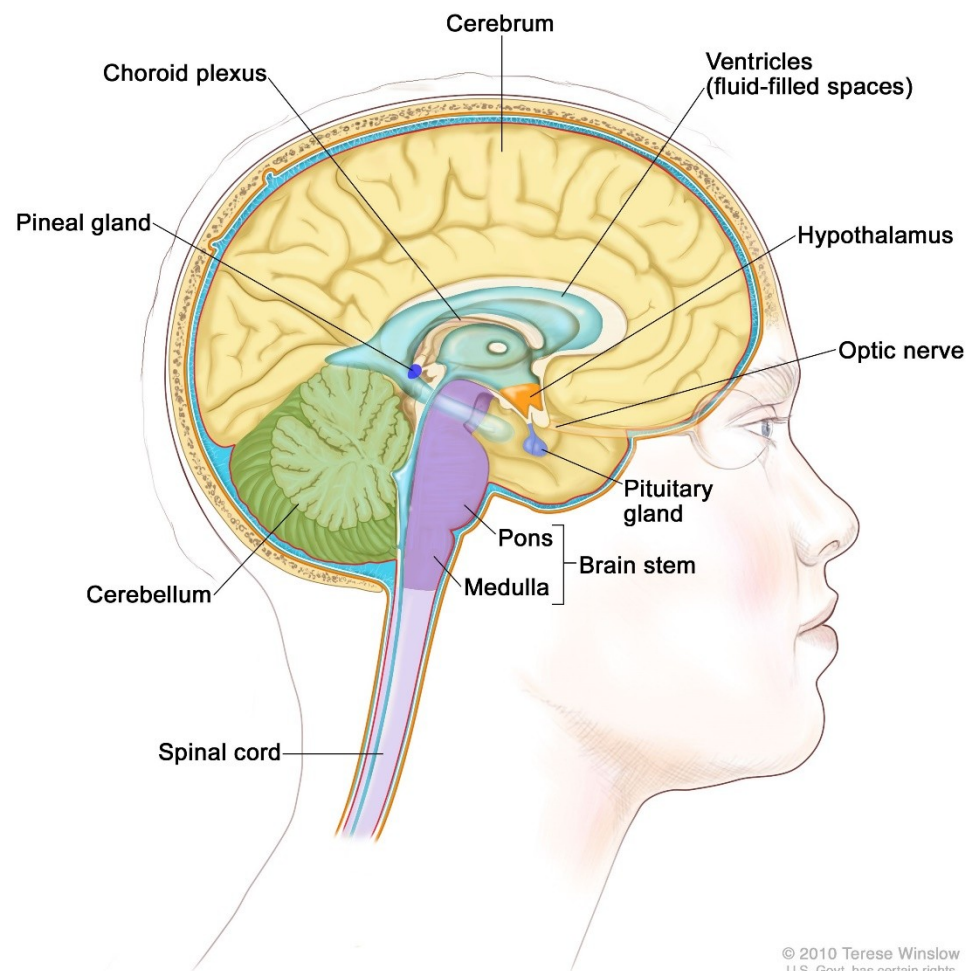


Řeč



- Afázie
- Motorická
- Senzorická
- Anamnestická

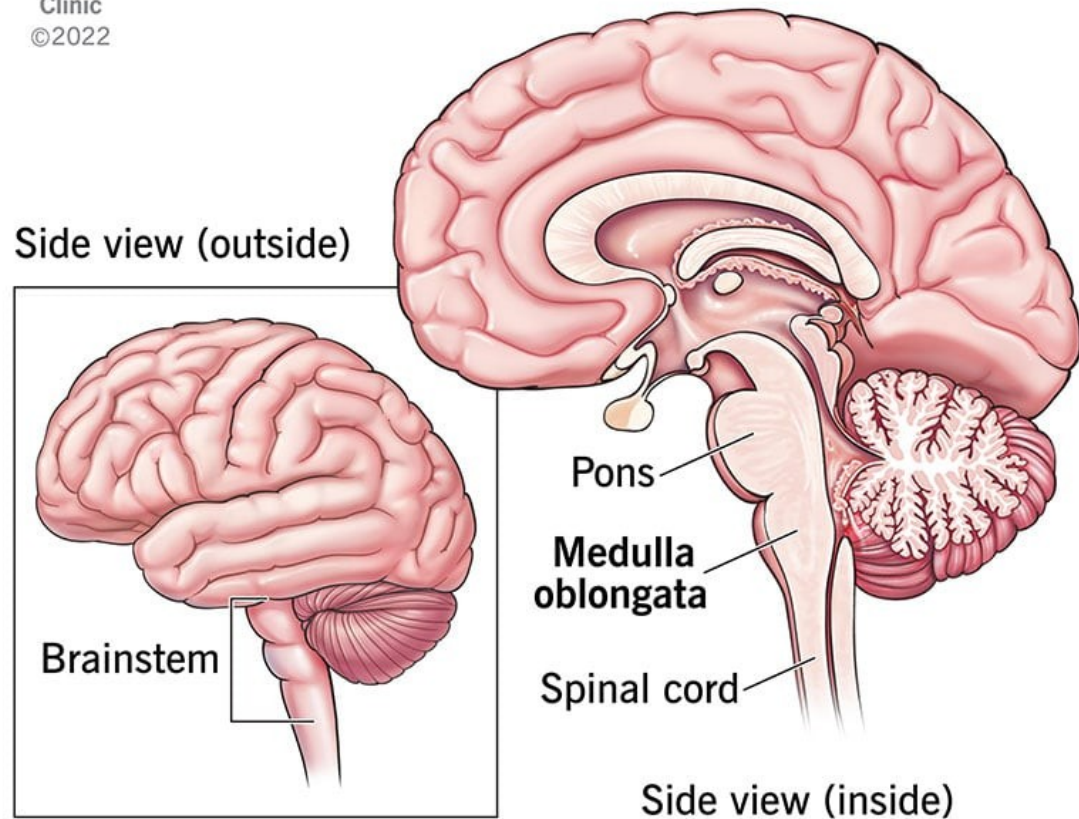
Prodloužená mícha



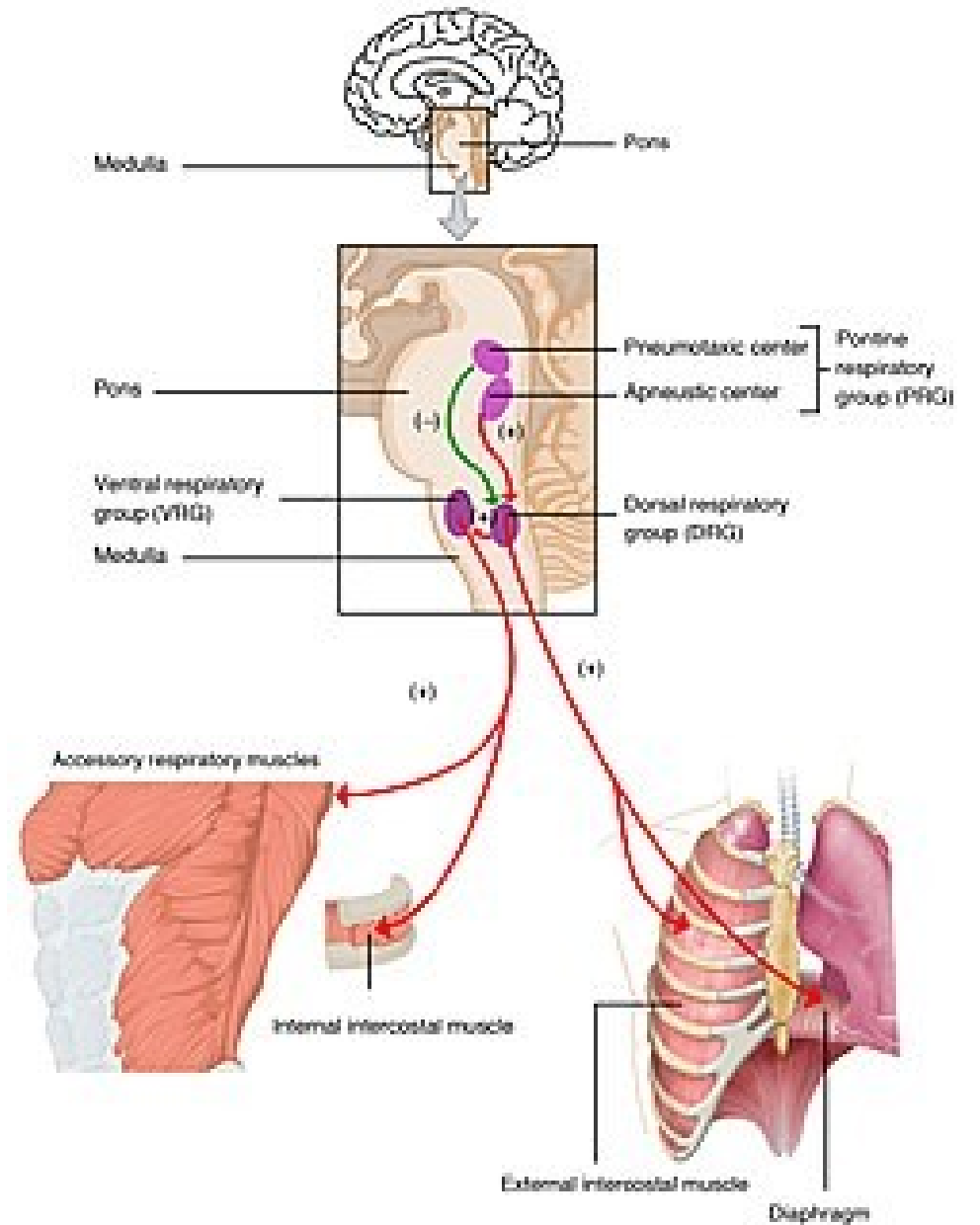
© 2010 Terese Winslow
U.S. Govt. has certain rights

Cleveland
Clinic
©2022

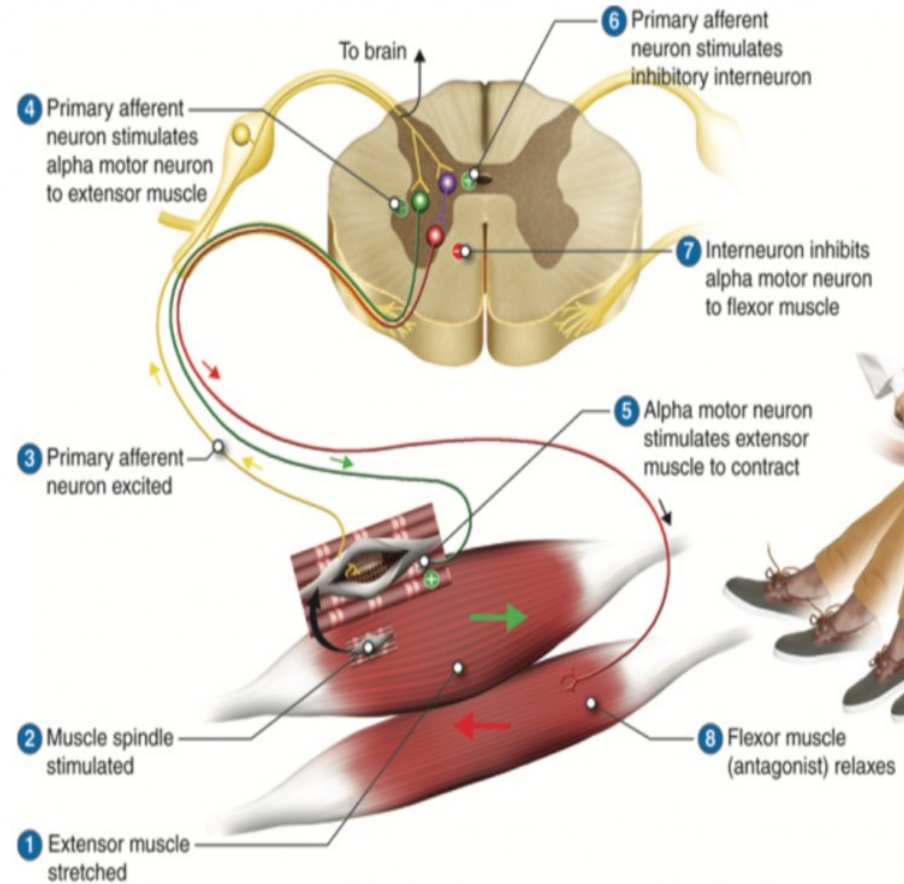
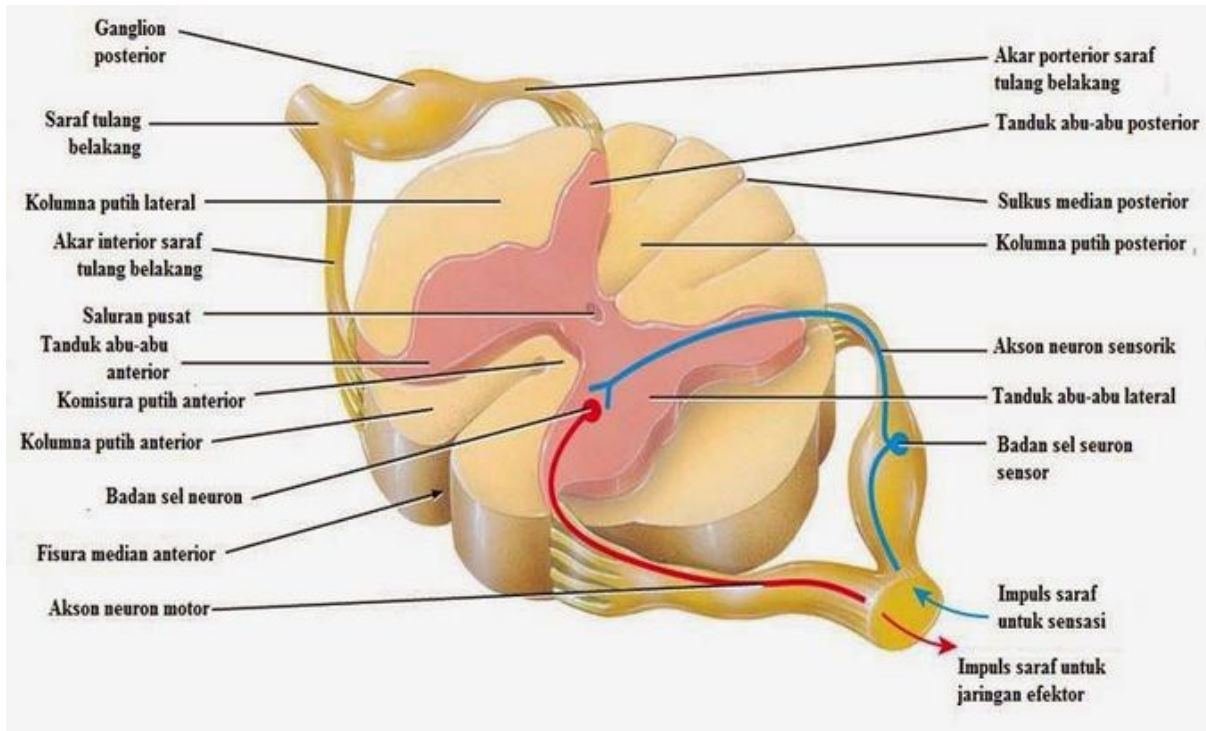
Medulla oblongata



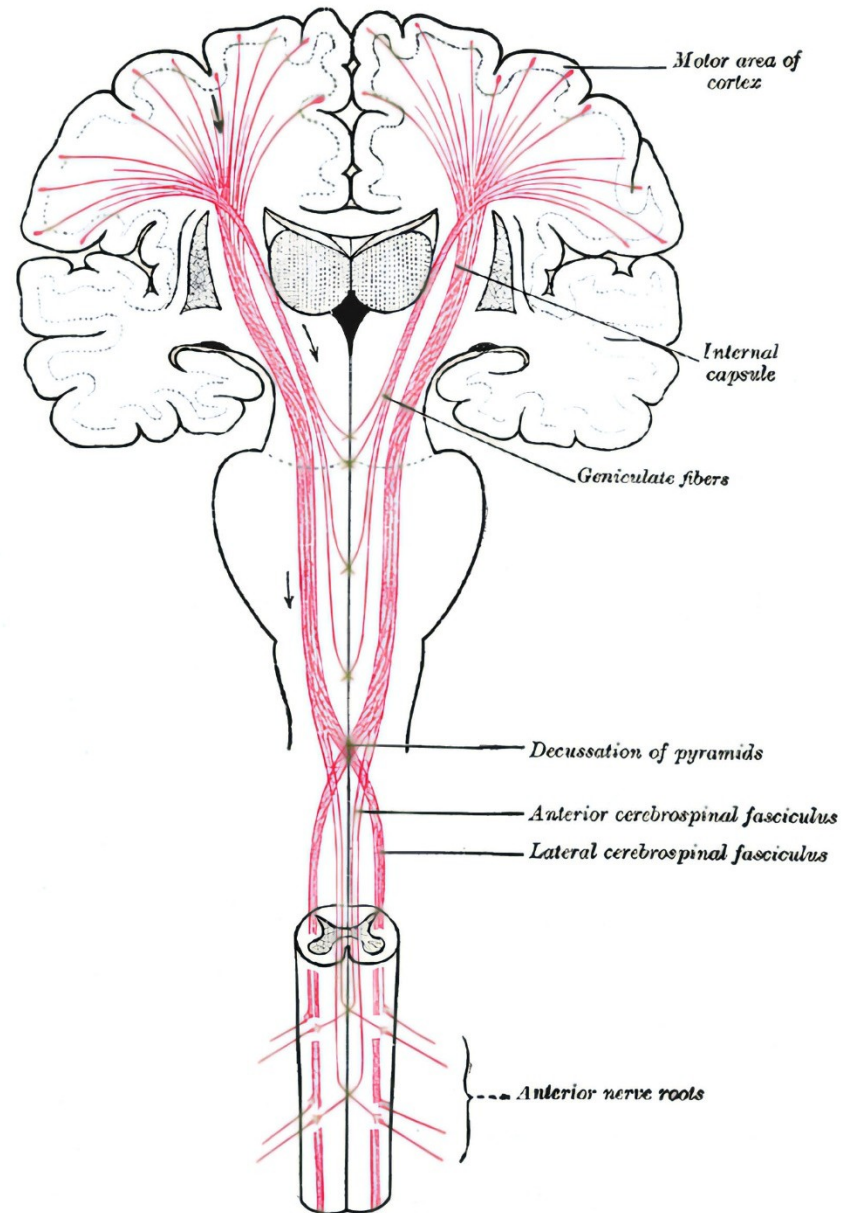
Prodloužená mícha



Mícha, lat. medulla spinalis, reflexní oblouk



Pyramidová dráha



- Tractus corticospinalis
- Hlavní motorická dráha
 - Jednoneuronová: z mozkové kůry do míchy
 - 80% vláken se v úrovni prodloužené míchy kříží-
decussatio pyramidum
- Fce: volní motorika
- Poruchy: hemiplegie
- Tractus corticobulbaris
- Fce: volní motorika obličeje a krku

Extrapiramidová dráha

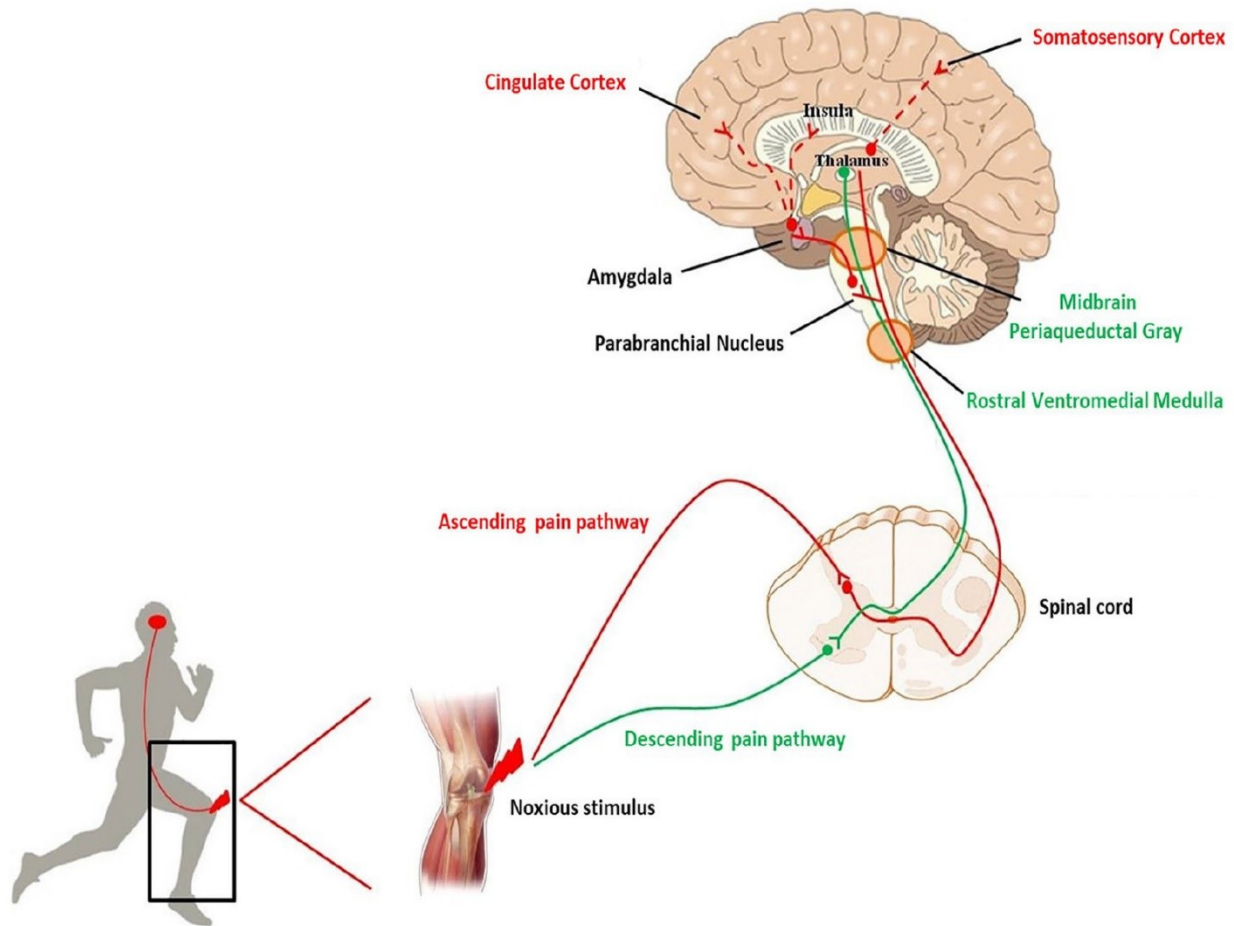
- Basální ganglia
- Mícha

- <https://youtu.be/B88BNYWVkwE>

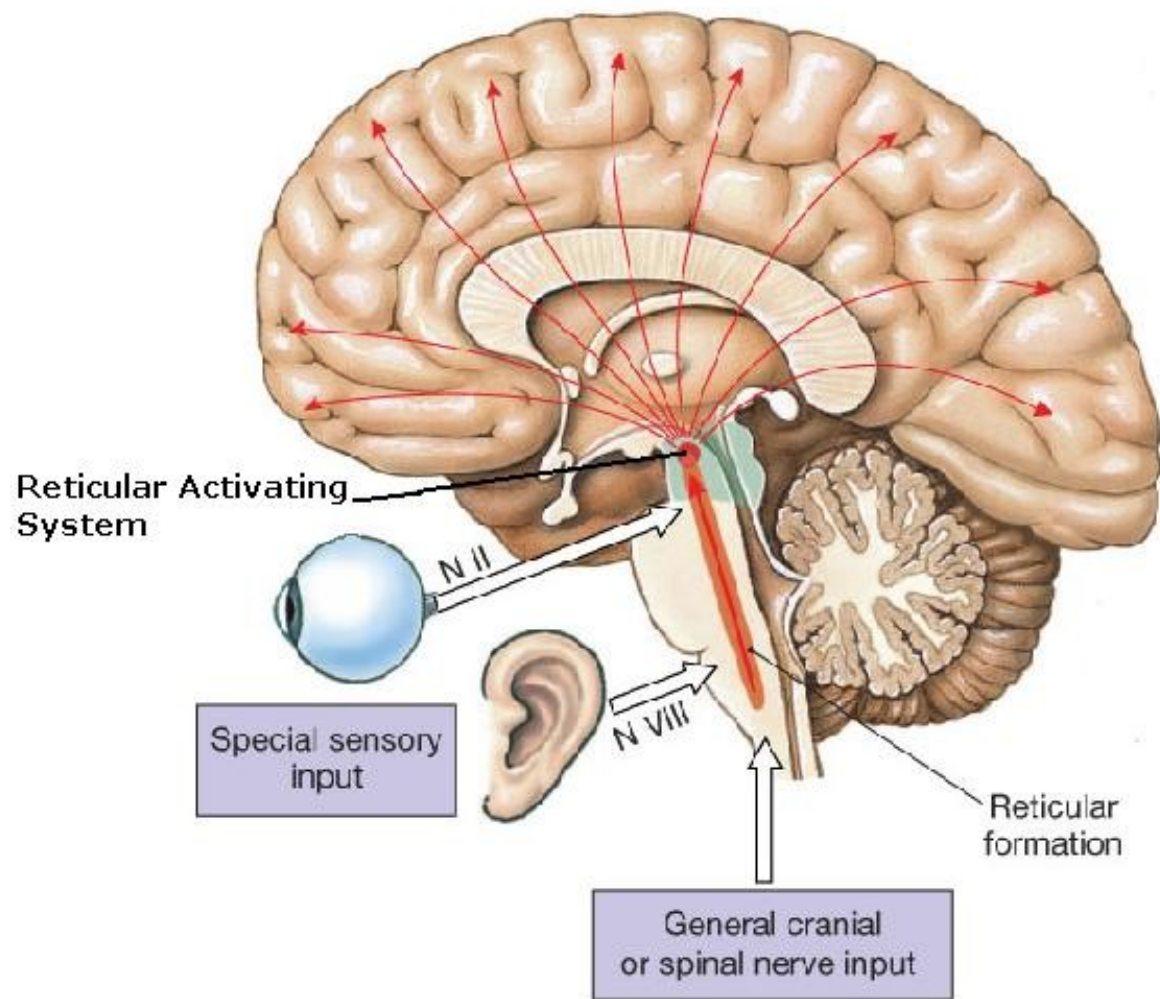
- <https://www.gastroepato.it/en/discinesie.htm>

- Poruchy:
- Chorea
- Atetóza
- Parkinsonova choroba

Dráha bolesti



Retikulární formace



Retikulární formace

A. nuclei raphes

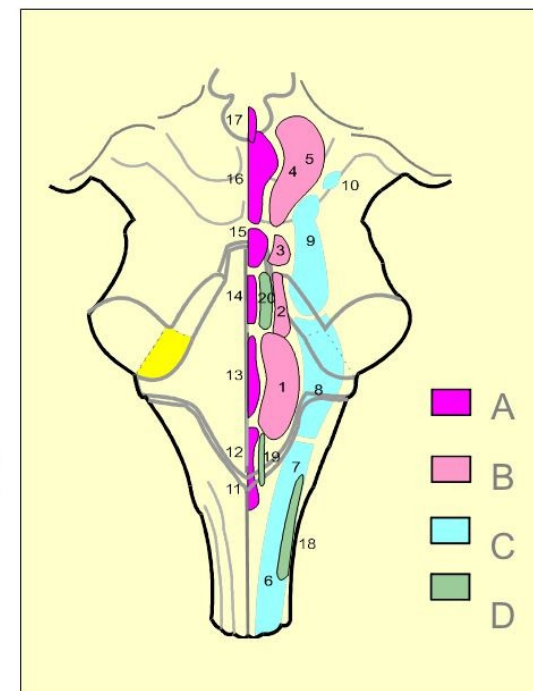
B. mediální skupina jader

C. laterální skupina jader

D. předmozečková

(precerebelární) retikulární jadra

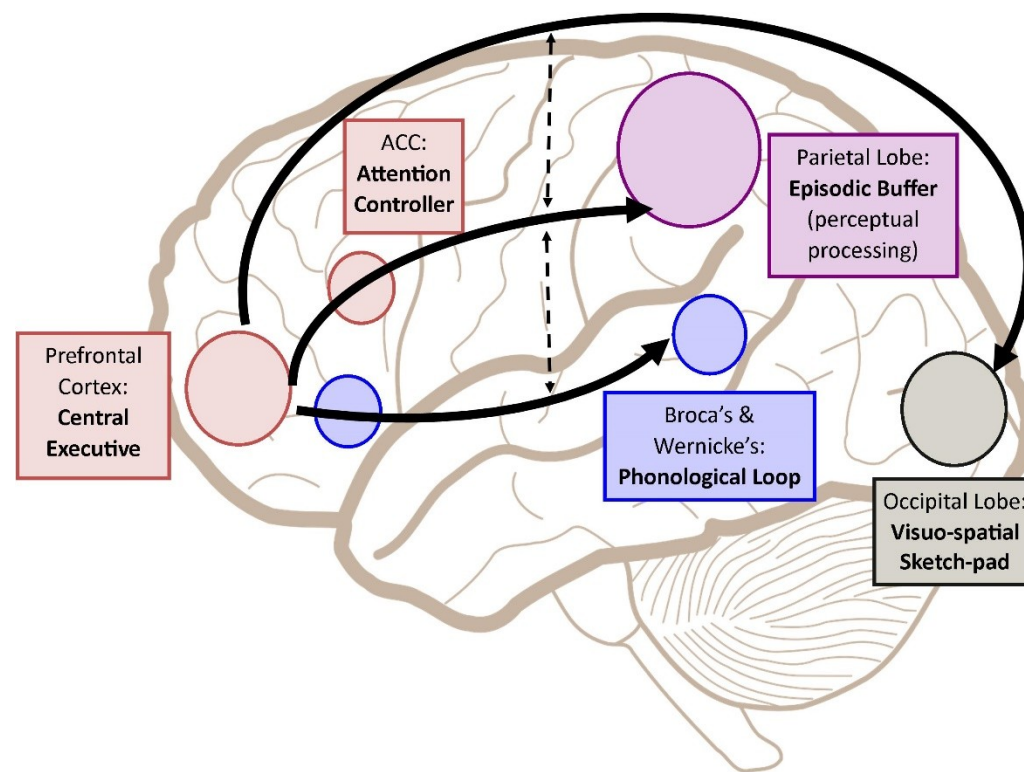
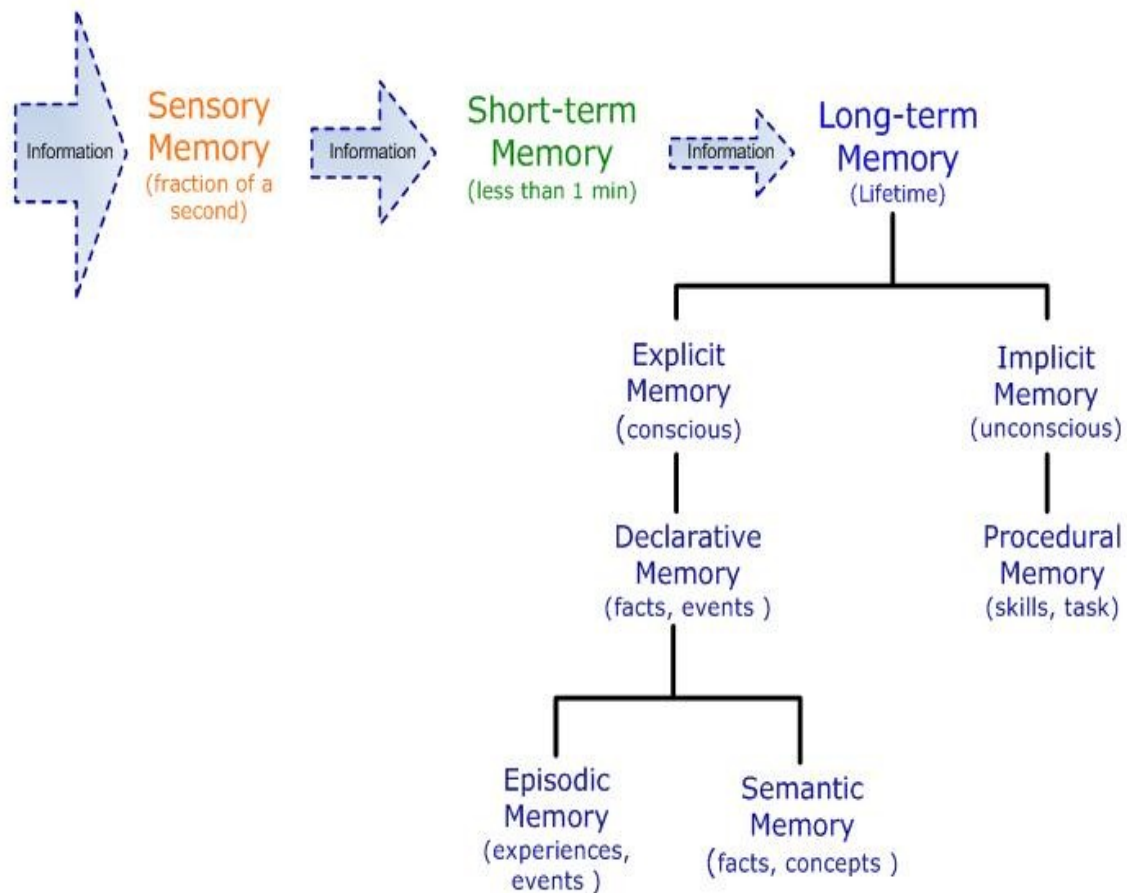
E. monoaminergní jadra



Retikulární formace

- https://cs.wikipedia.org/wiki/Retikul%C3%A1rn%C3%AD_formace

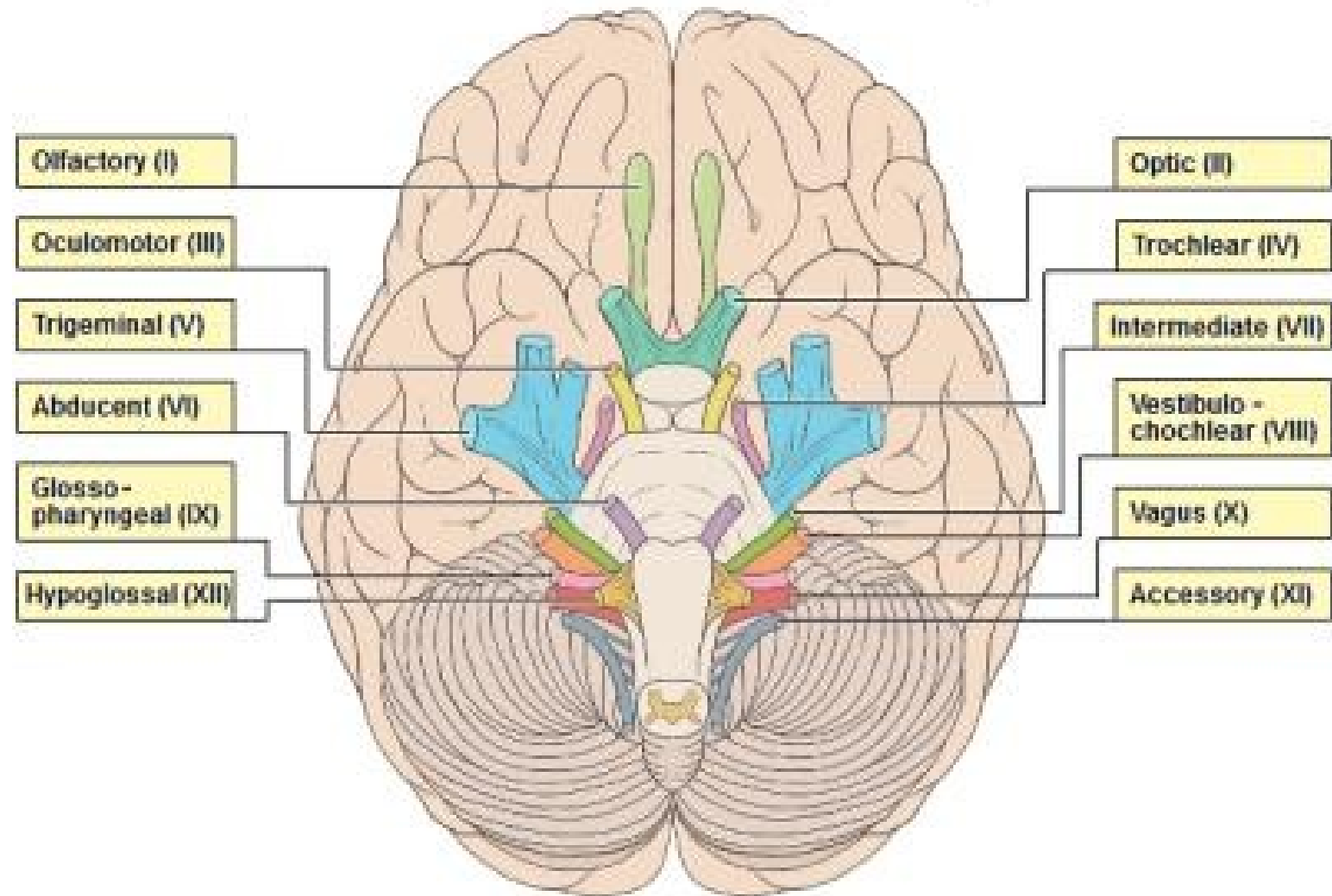
Paměť



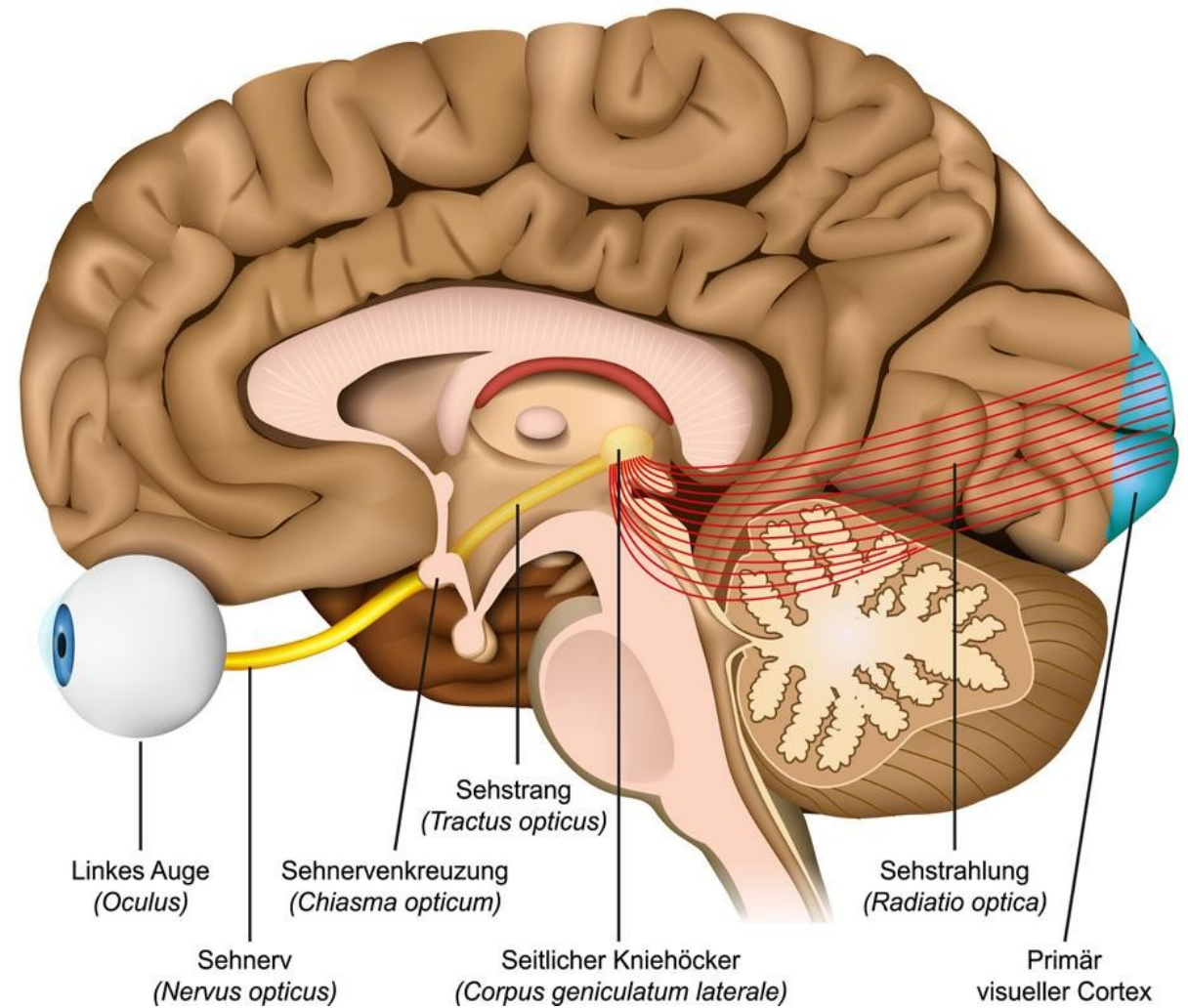
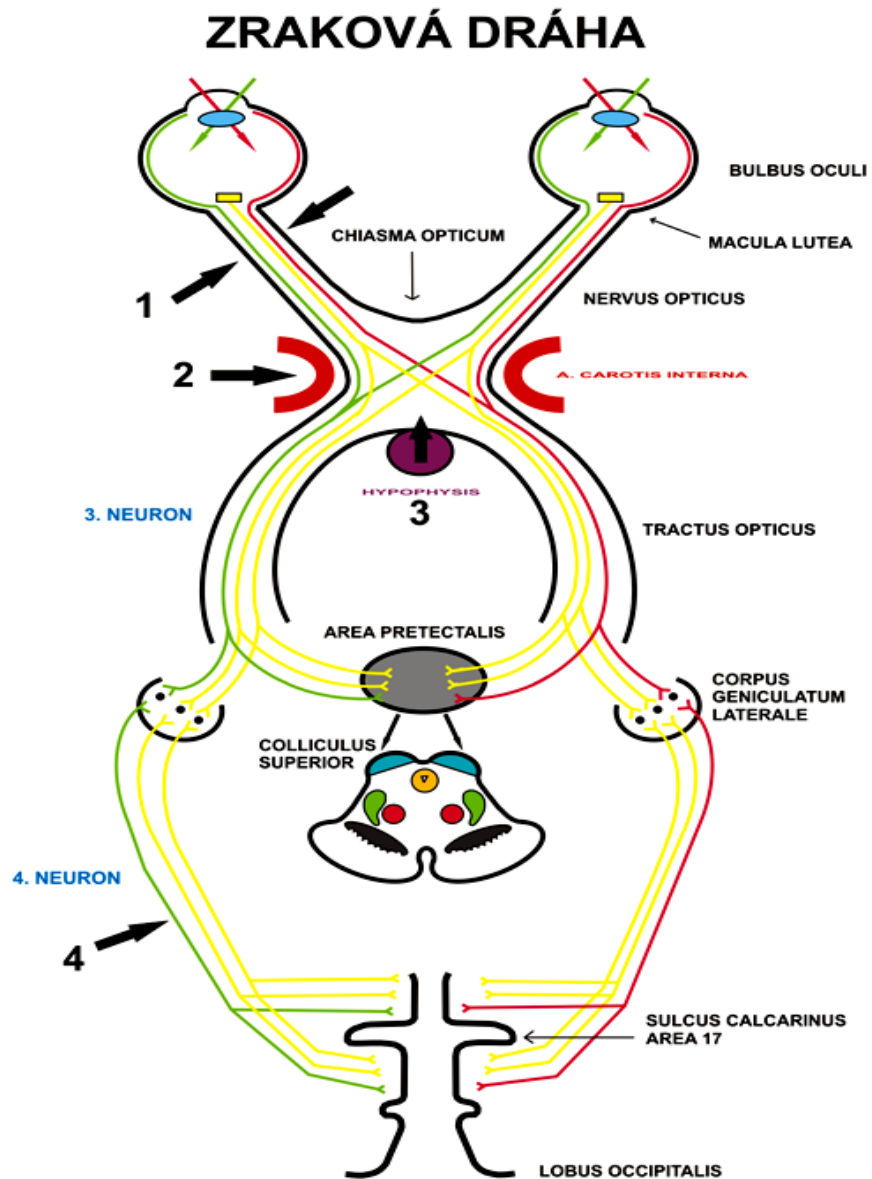
Mícha

Hlavové nervy

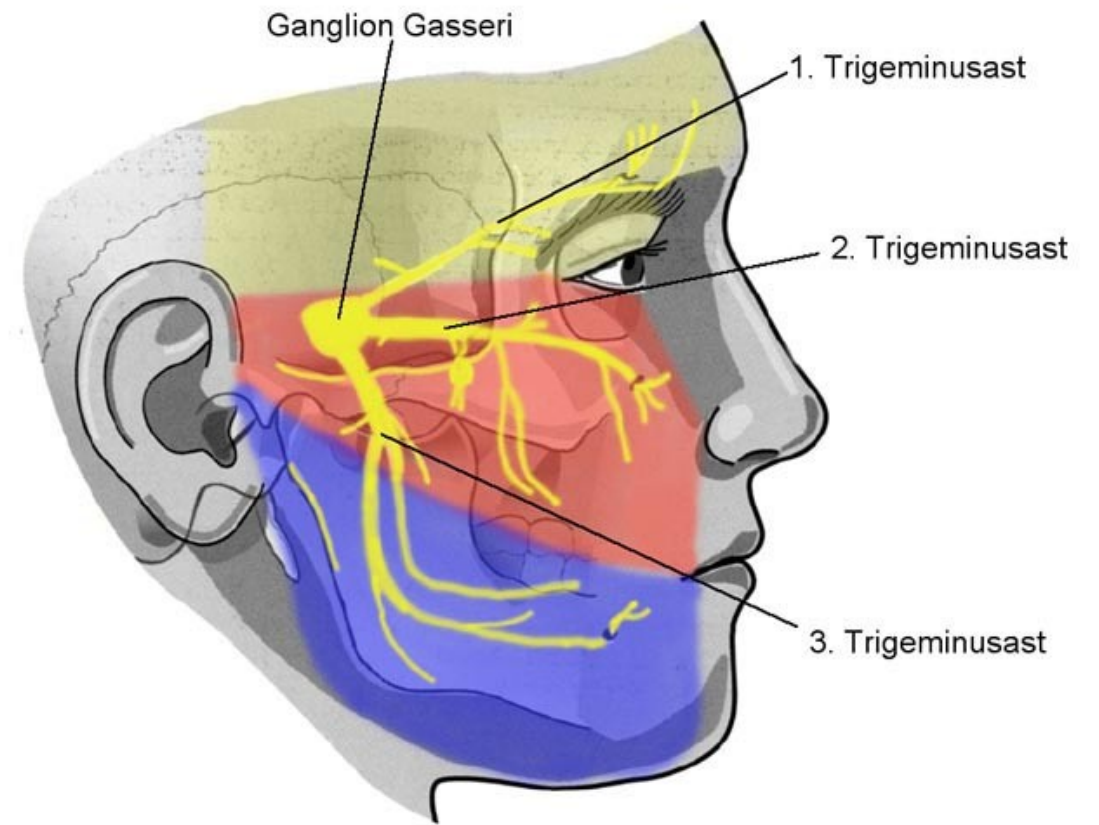
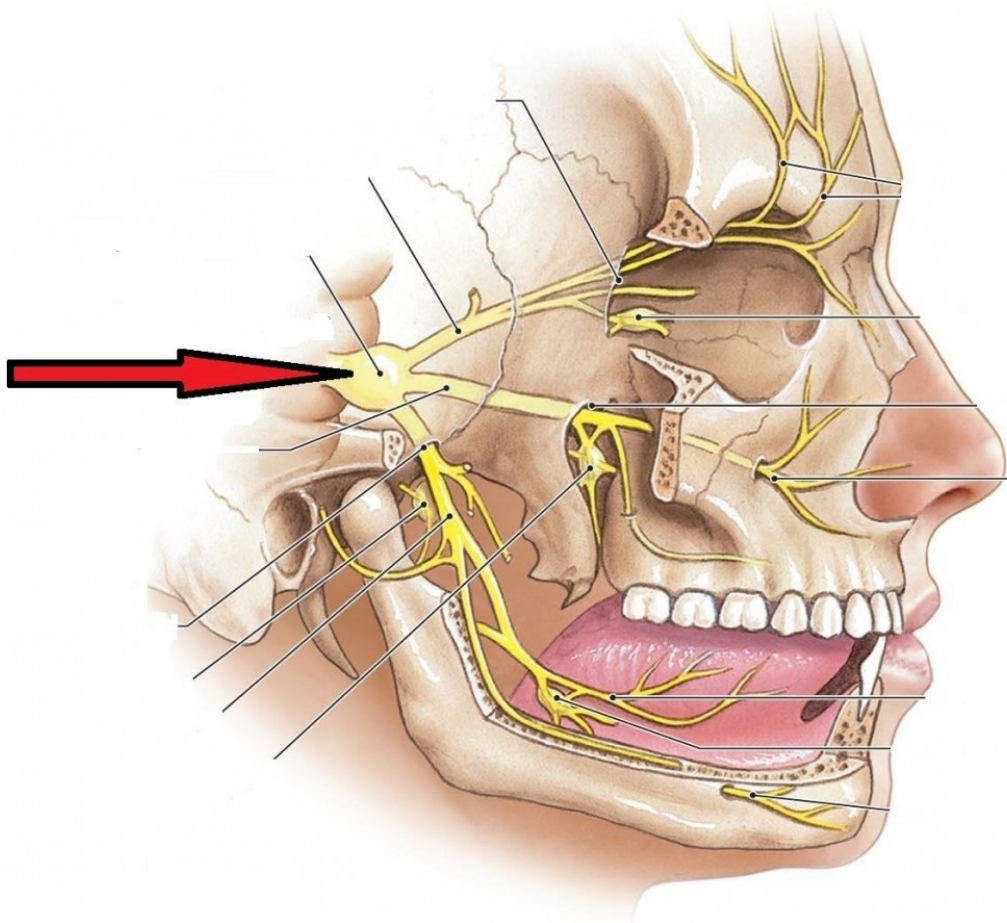
Cranial Nerves (I - XII)



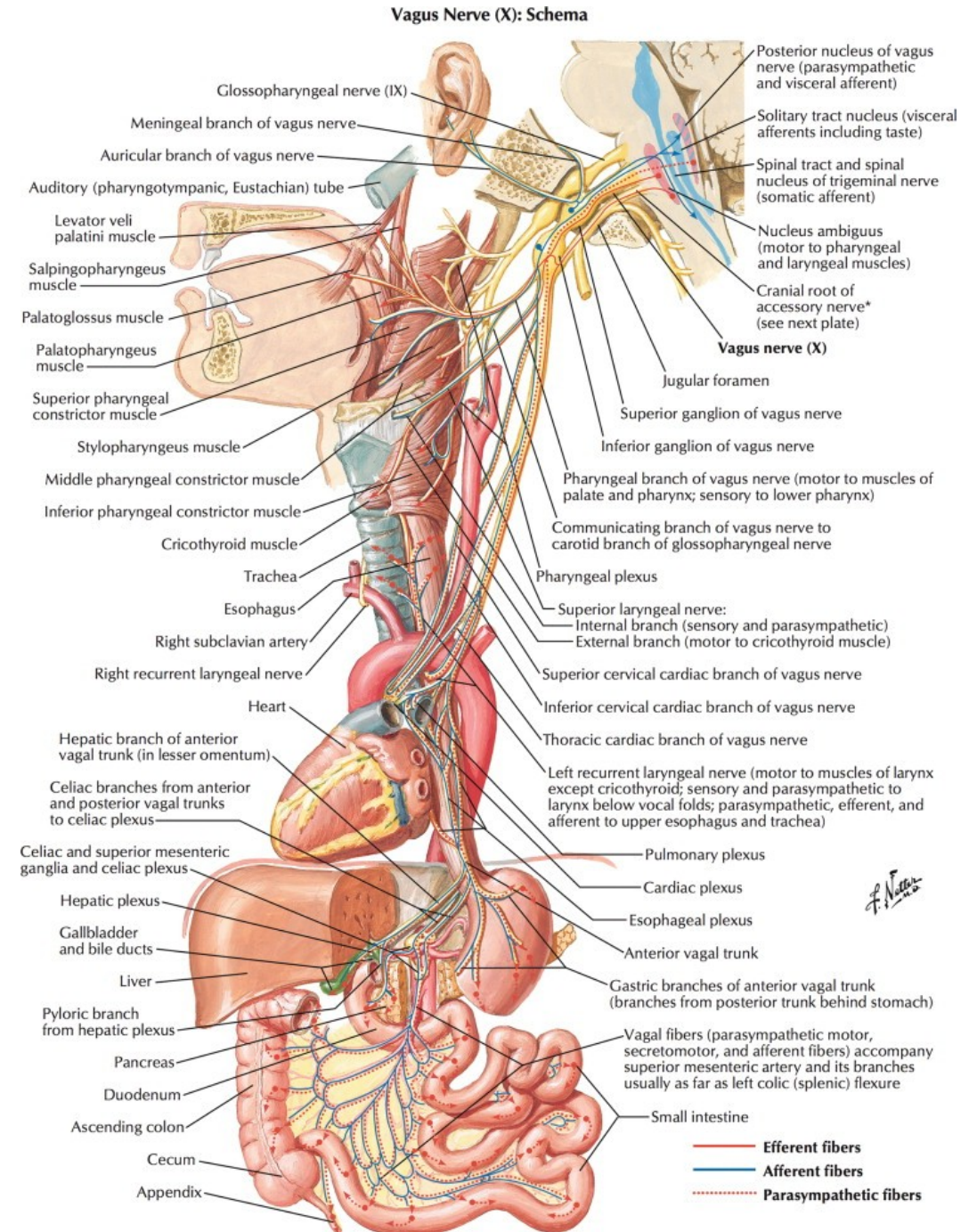
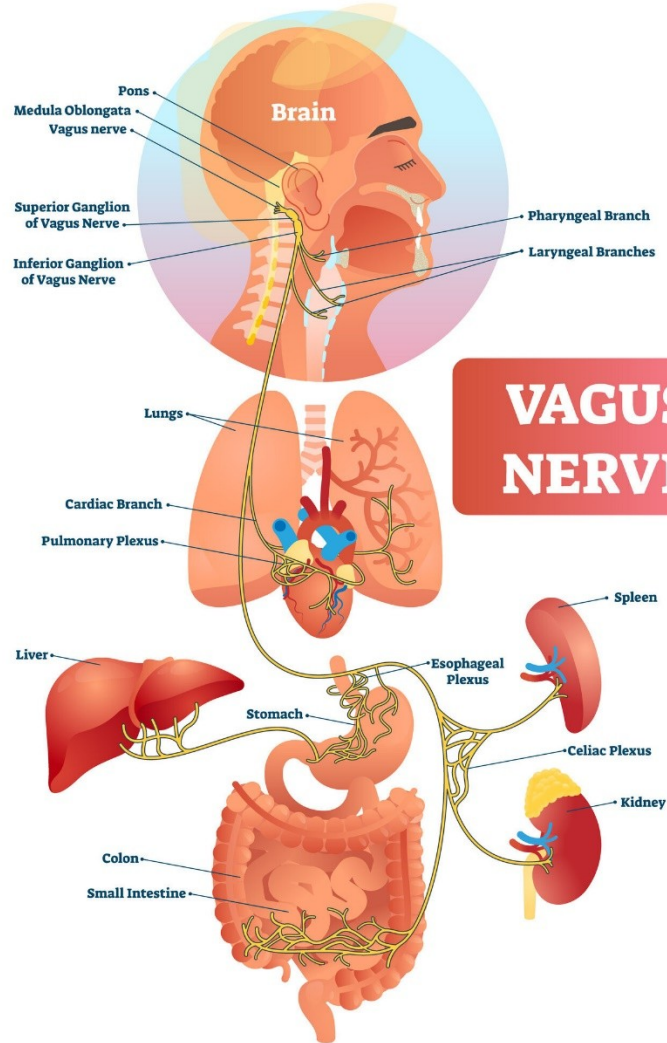
Nervus opticus

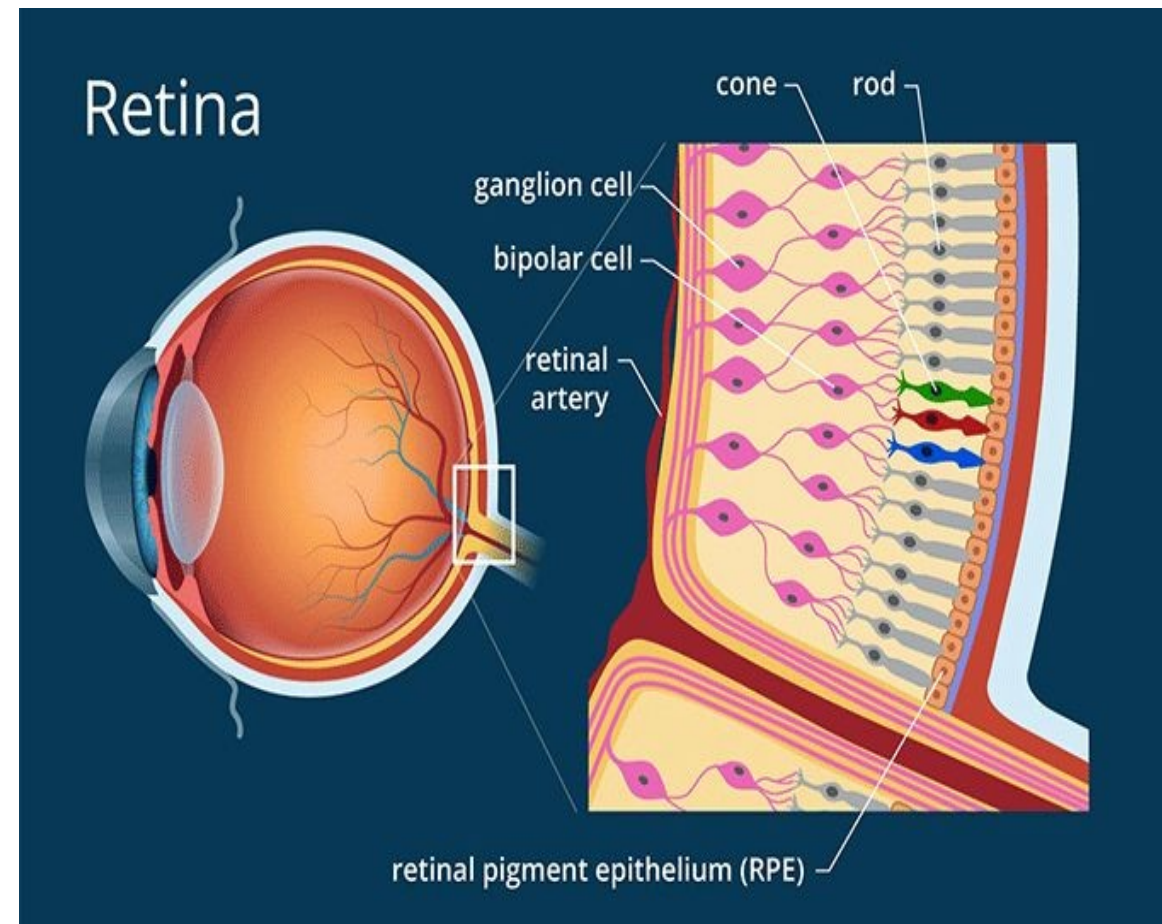
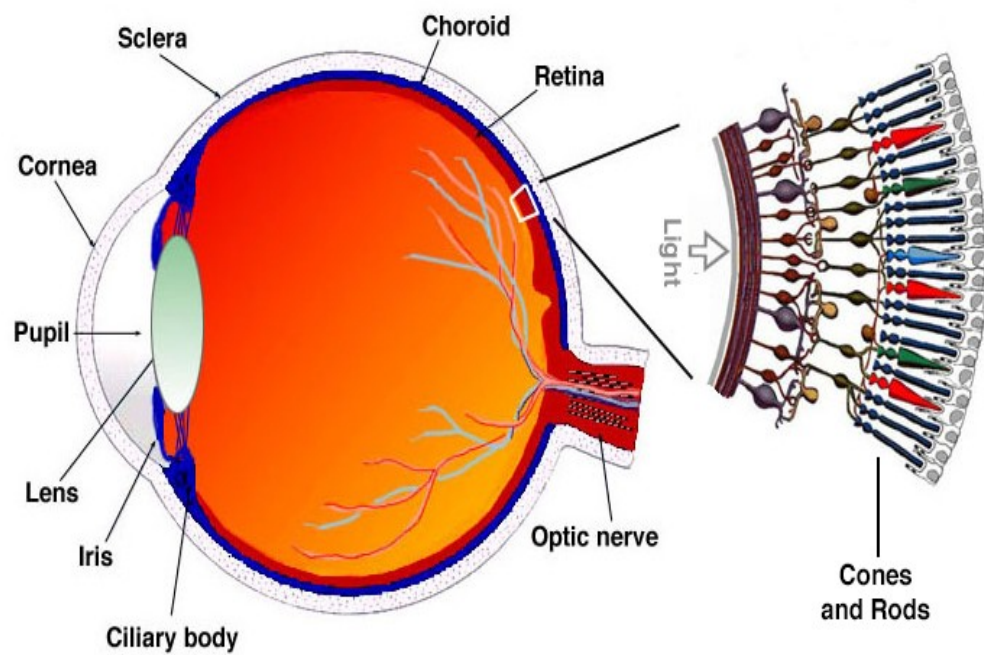


Nervus trigeminus

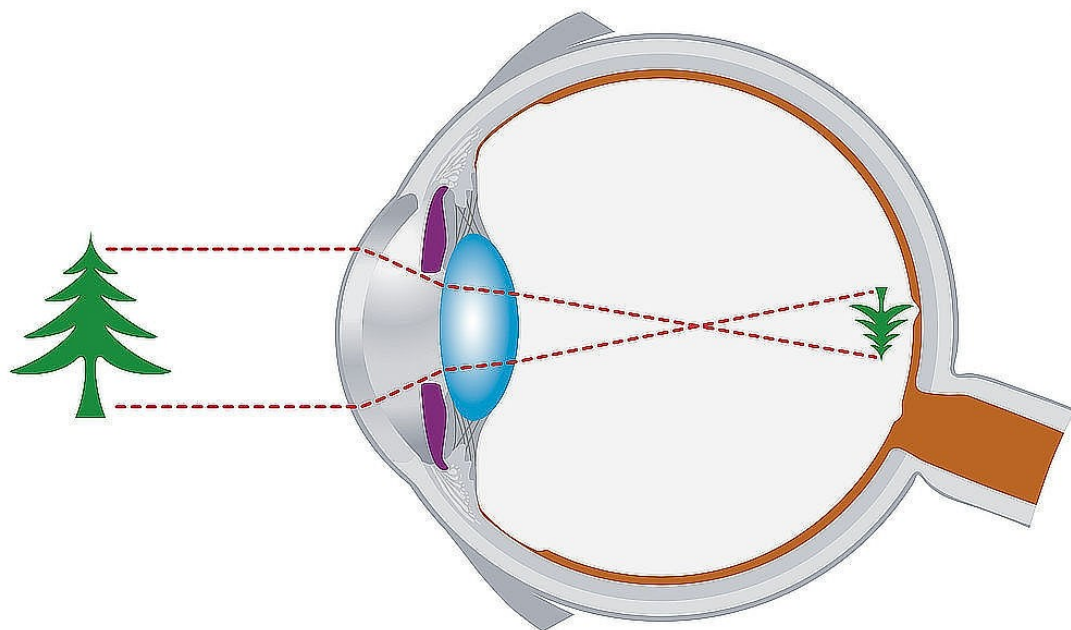


Nervus vagus

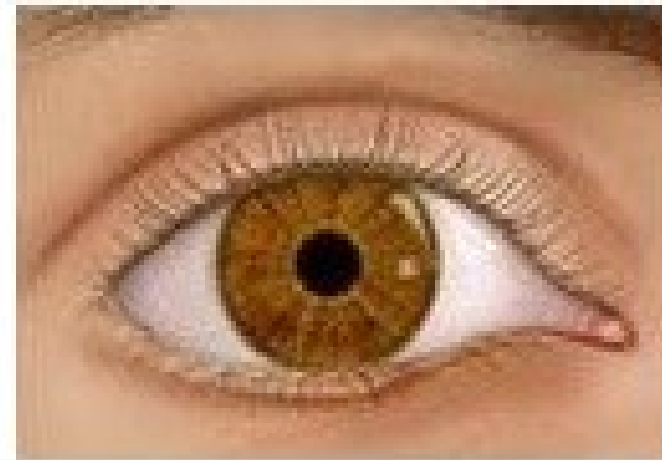



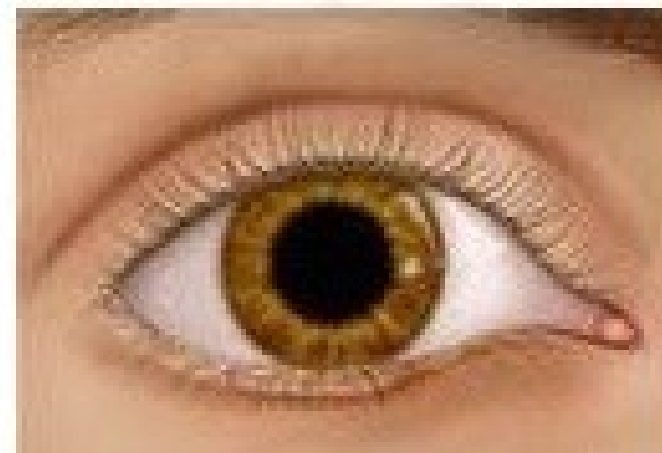Optický systém oka



Pohled na blízký předmět

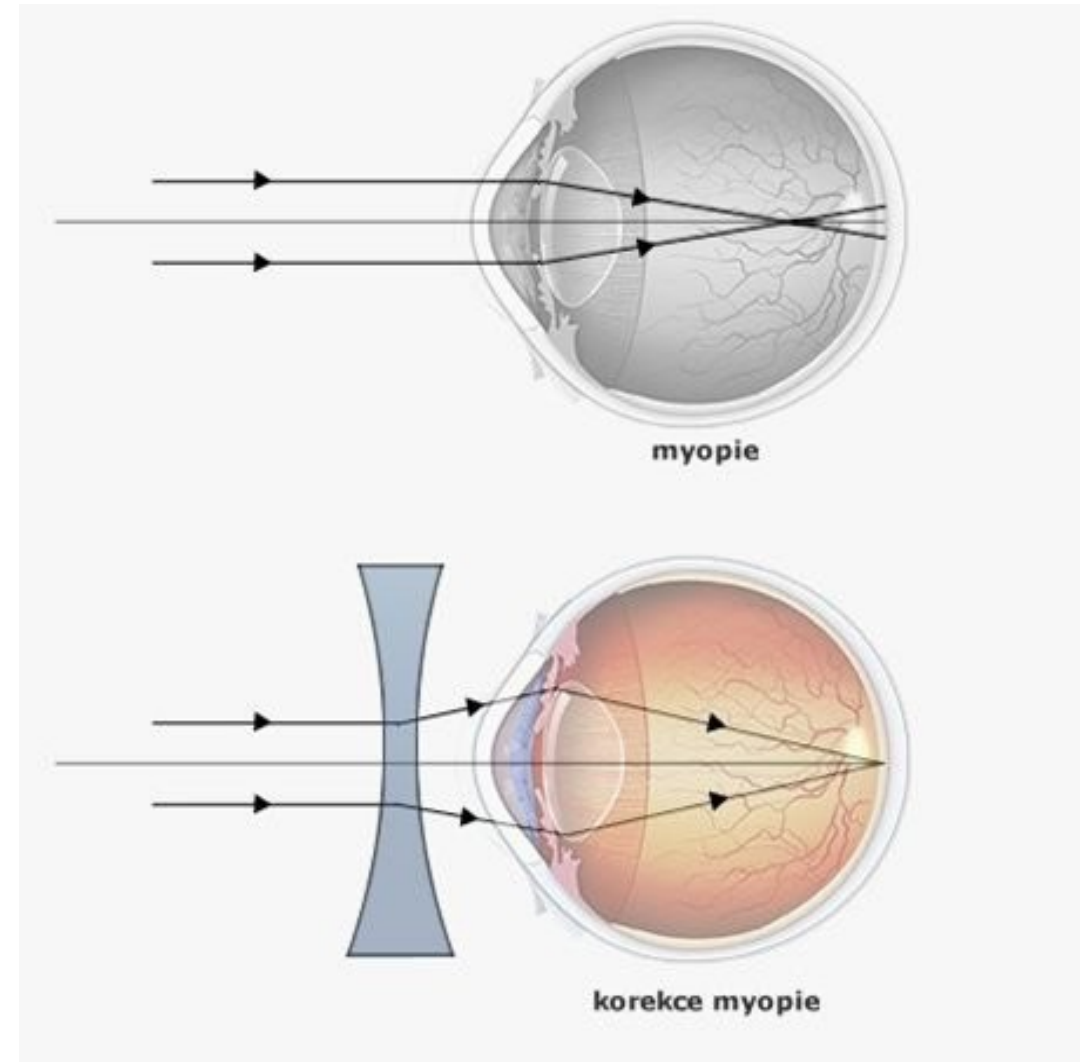
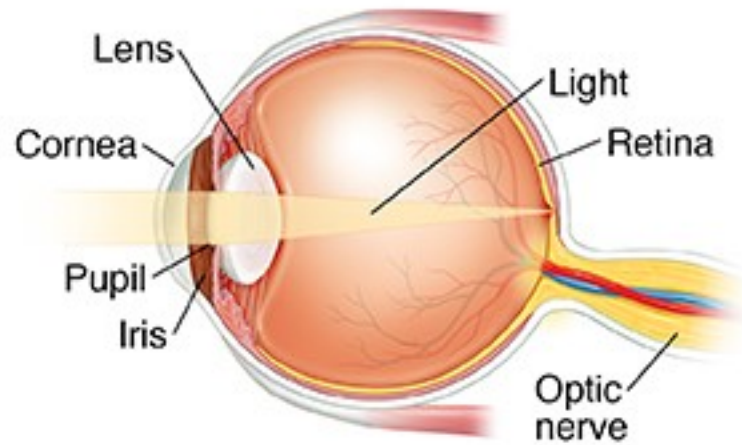


Pohled na vzdálený předmět

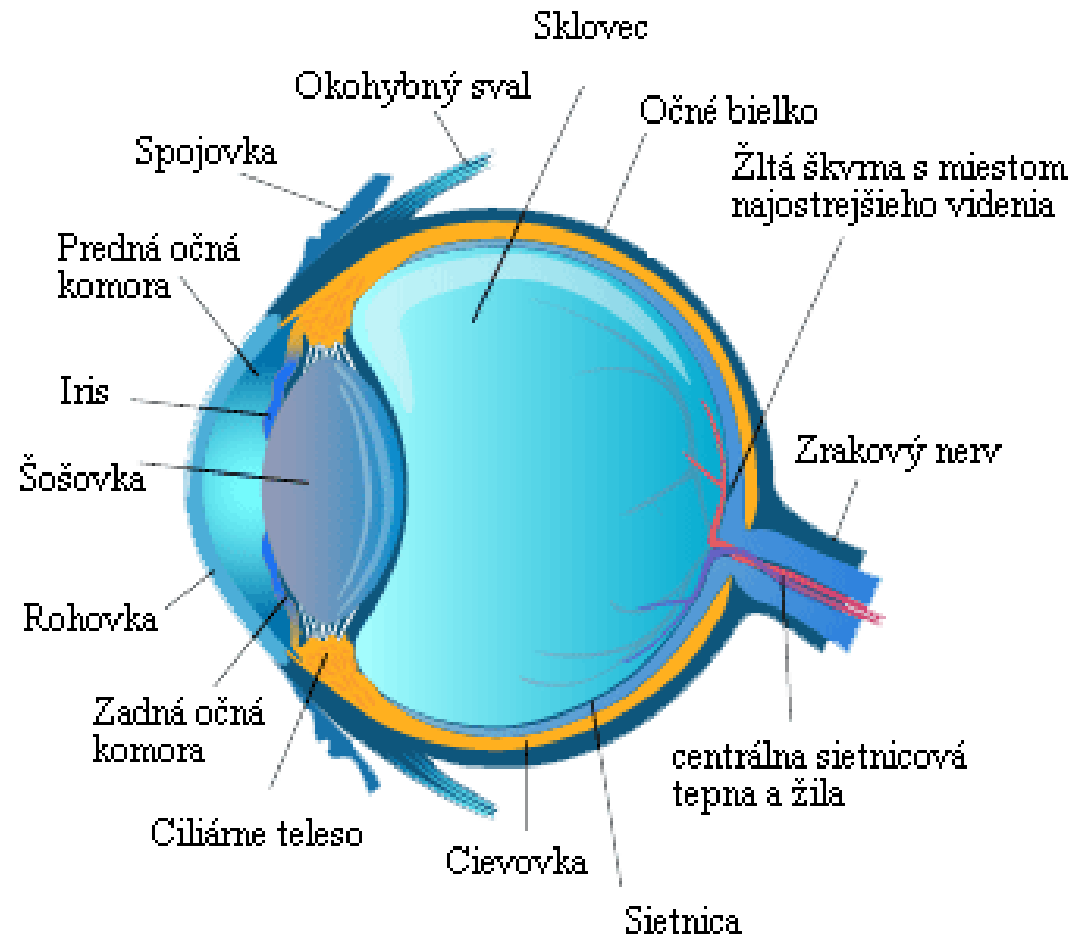


https://www.google.com/search?q=optick%C3%BD+syst%C3%A9m+oka&tbm=isch&ved=2ahUKEwjX24uAgYD8AhUGSRoKHYIQA_QQ2-cCegQIABAA&oeq=optick%C3%BD+syst%C3%A9m+oka&gs_lcp=CgNpbWcQAzIFCAAQgAQ6BwgAEIAEEBg6CAgAEIAEELEDOgsIABCABBCxAxCDAToECAAQZoICAAQsQMogwE6BAGAEAM6BQgAELEDULQGWJQ1YI86aABwAHgAgAE5iAGeDZIBAjMymAEoAEBqgELZ3dzLXdpei1pbWewAQDAAQE&scient=img&ei=VI-dY9fYM4aSaYmhjaAP&bih=505&biw=1003#imgrc=x9ReLWdn1gUpmM

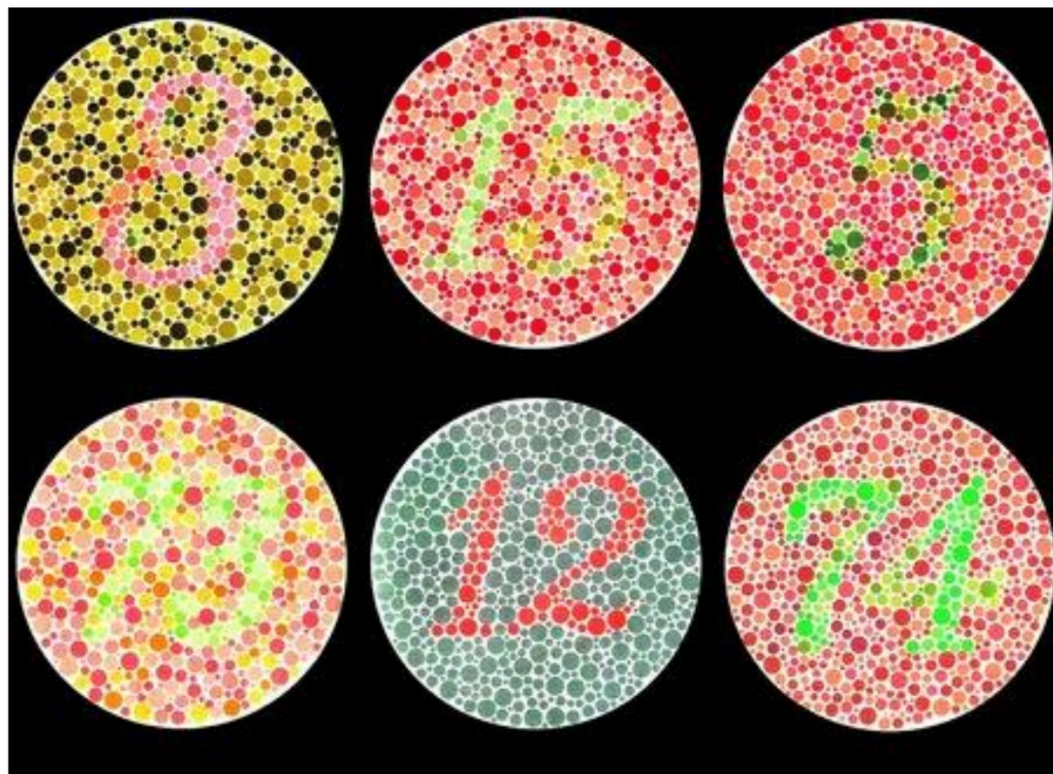
Refrakční vady



Komorový systém oka



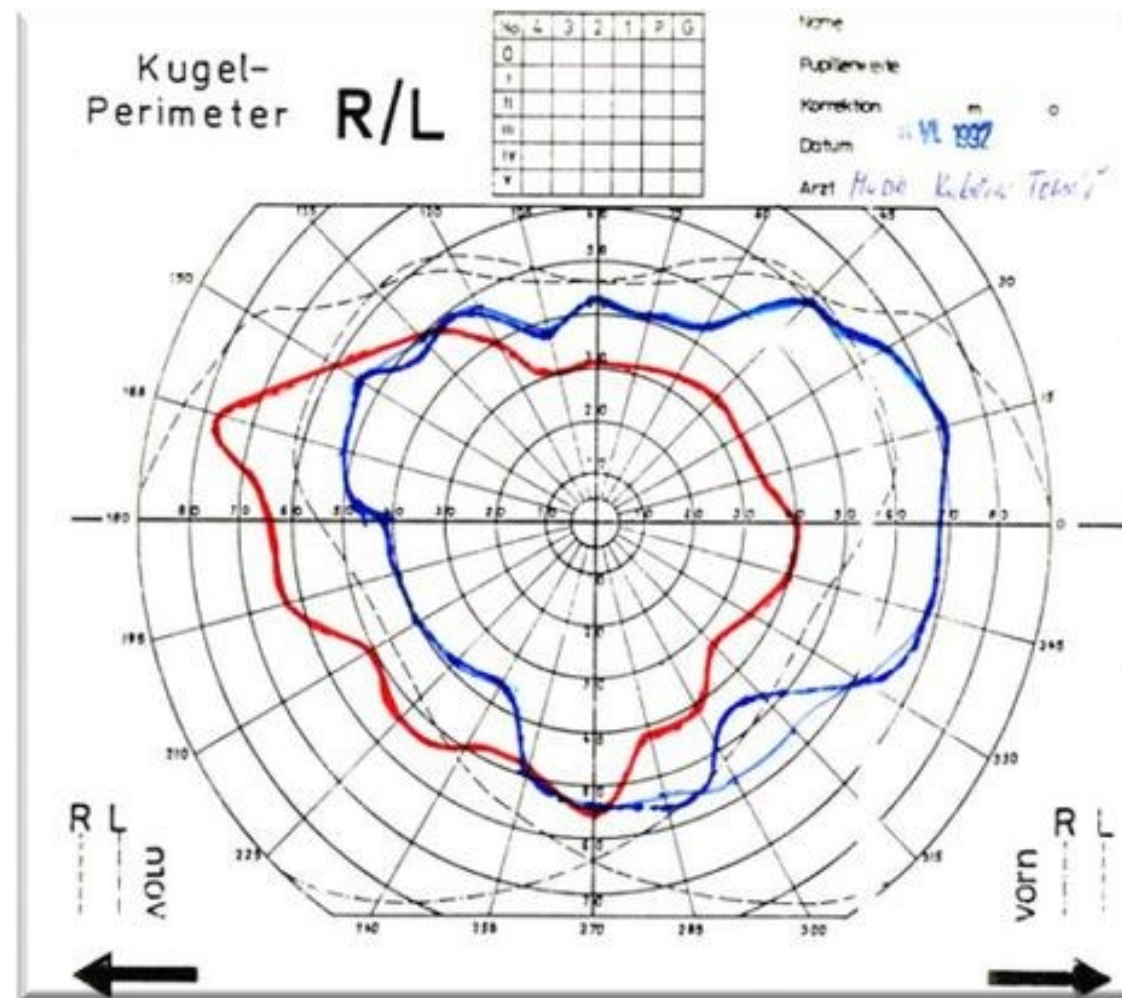
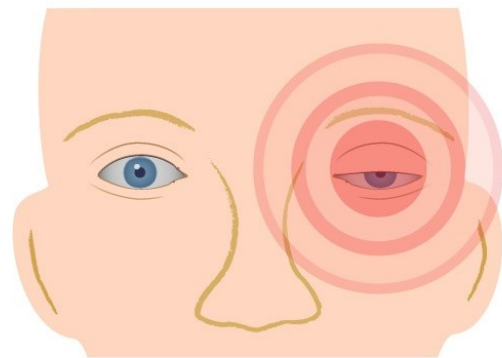
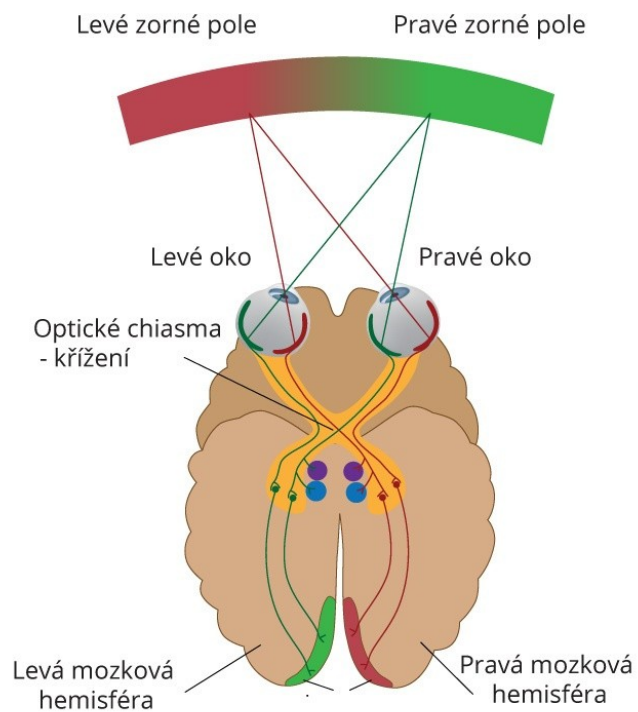
Daltonismus



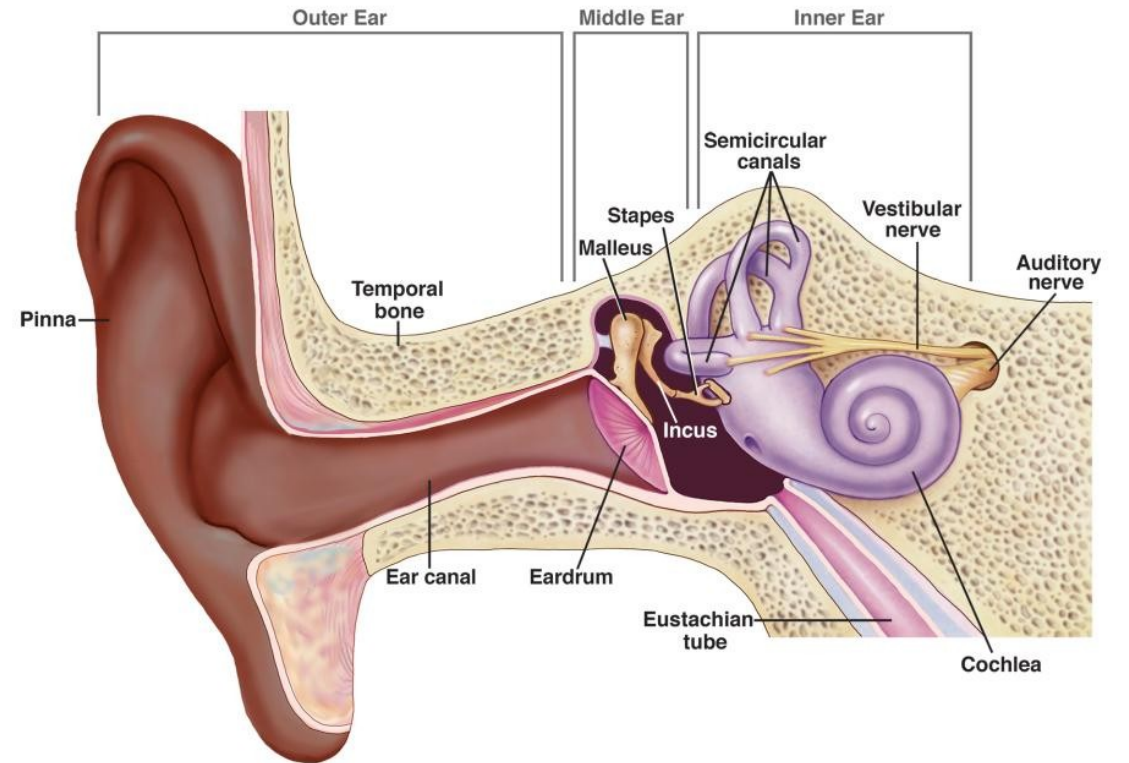

- <https://cs.wikipedia.org/wiki/Bavroslepost>
- Protanopie č
- Deuteranopie z
- Tritanopie m

Zorné pole, výpadky (skotomy)

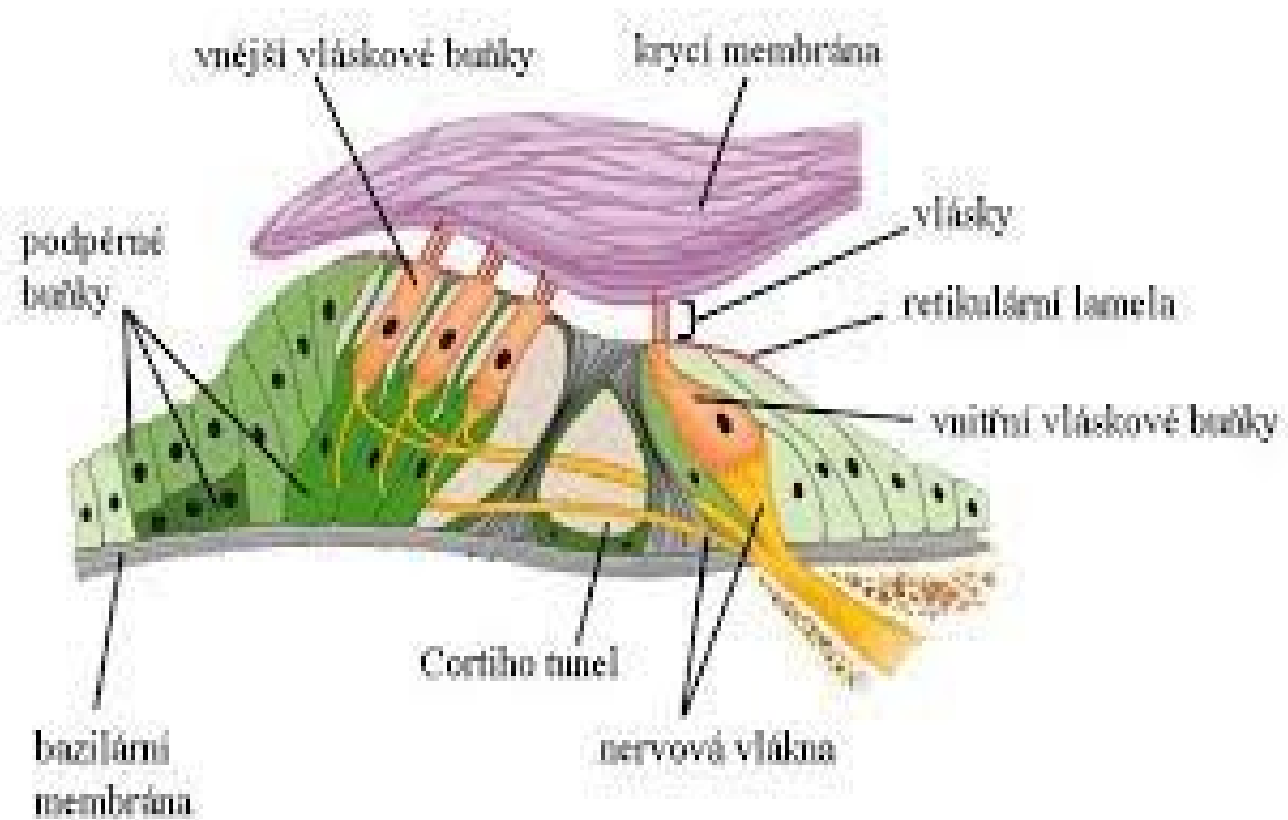
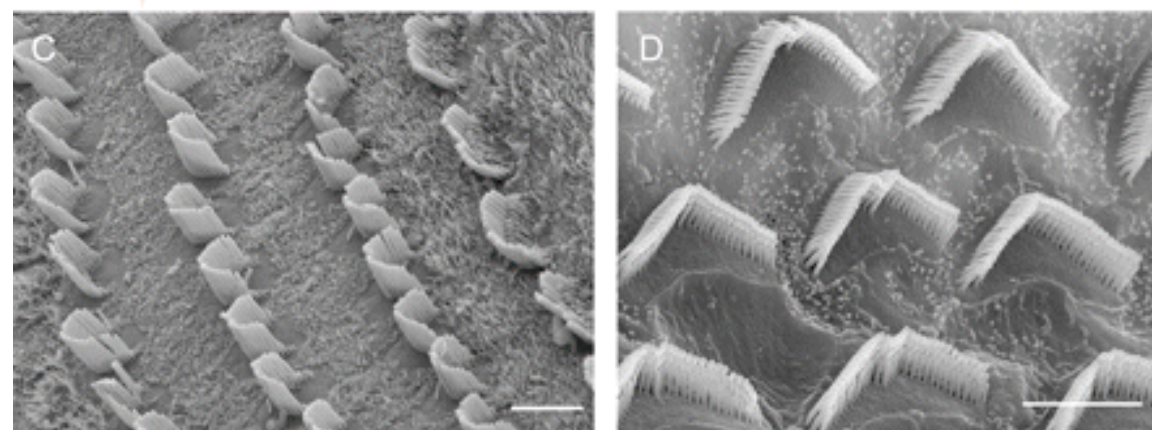
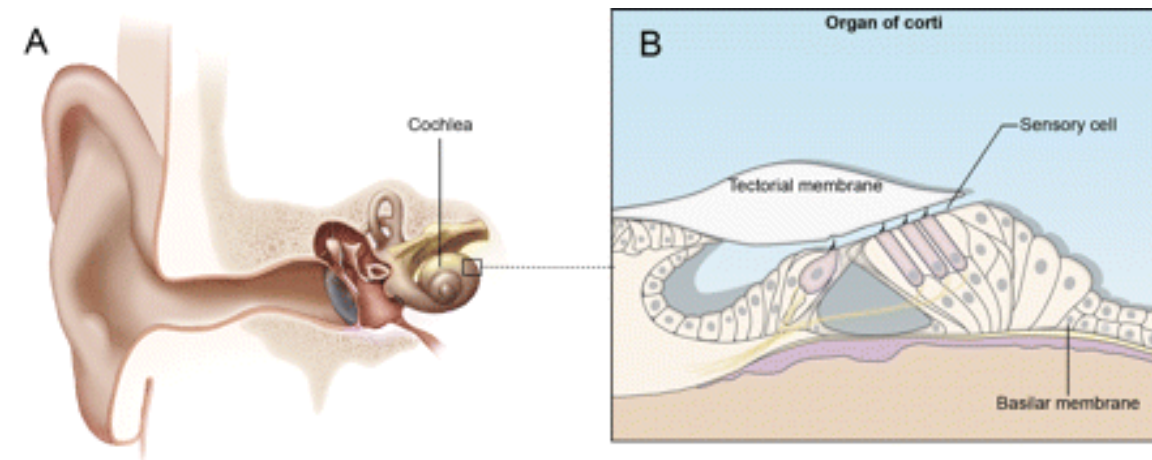
Výpadek zorného pole (skotom)



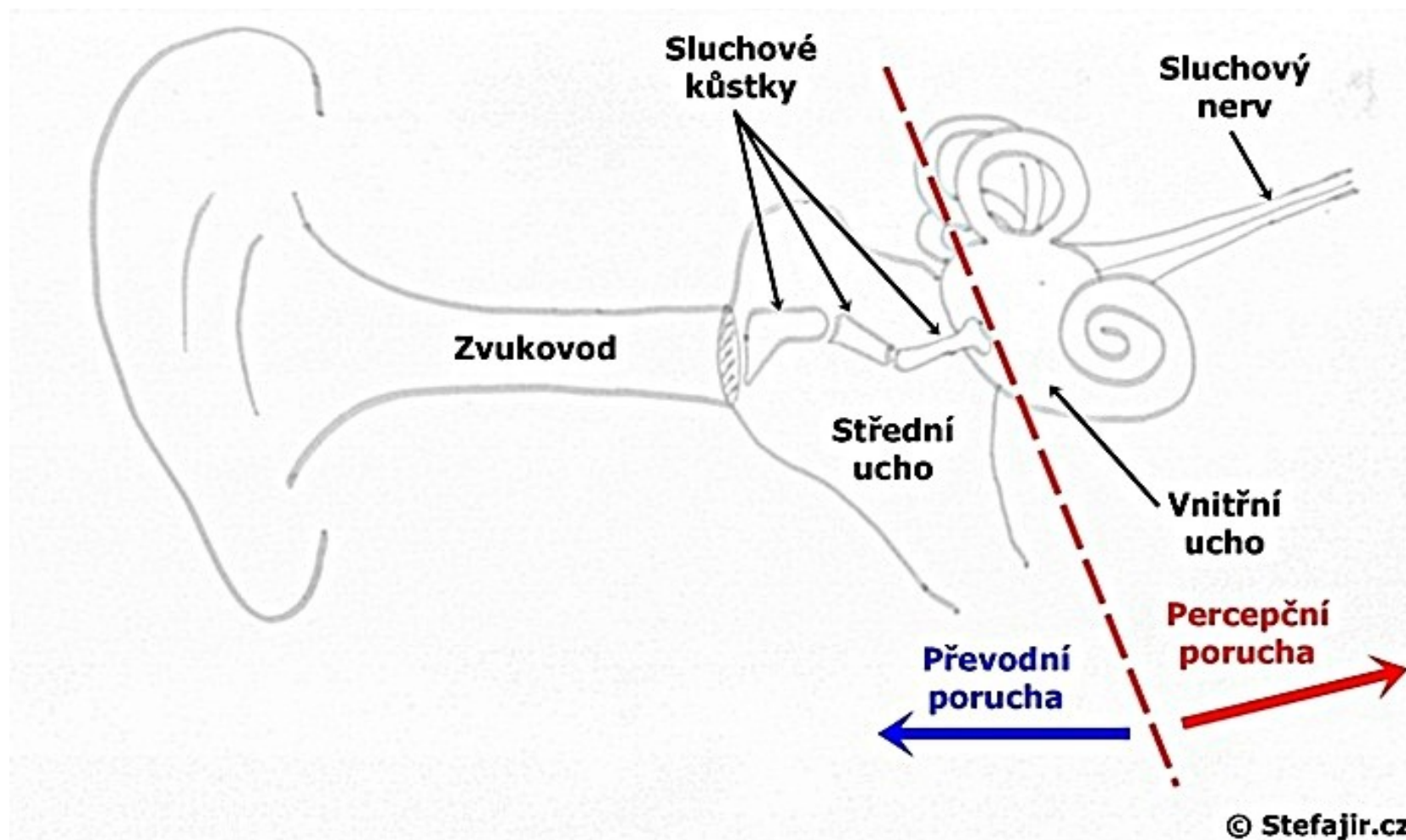
Ucho, lat. auris



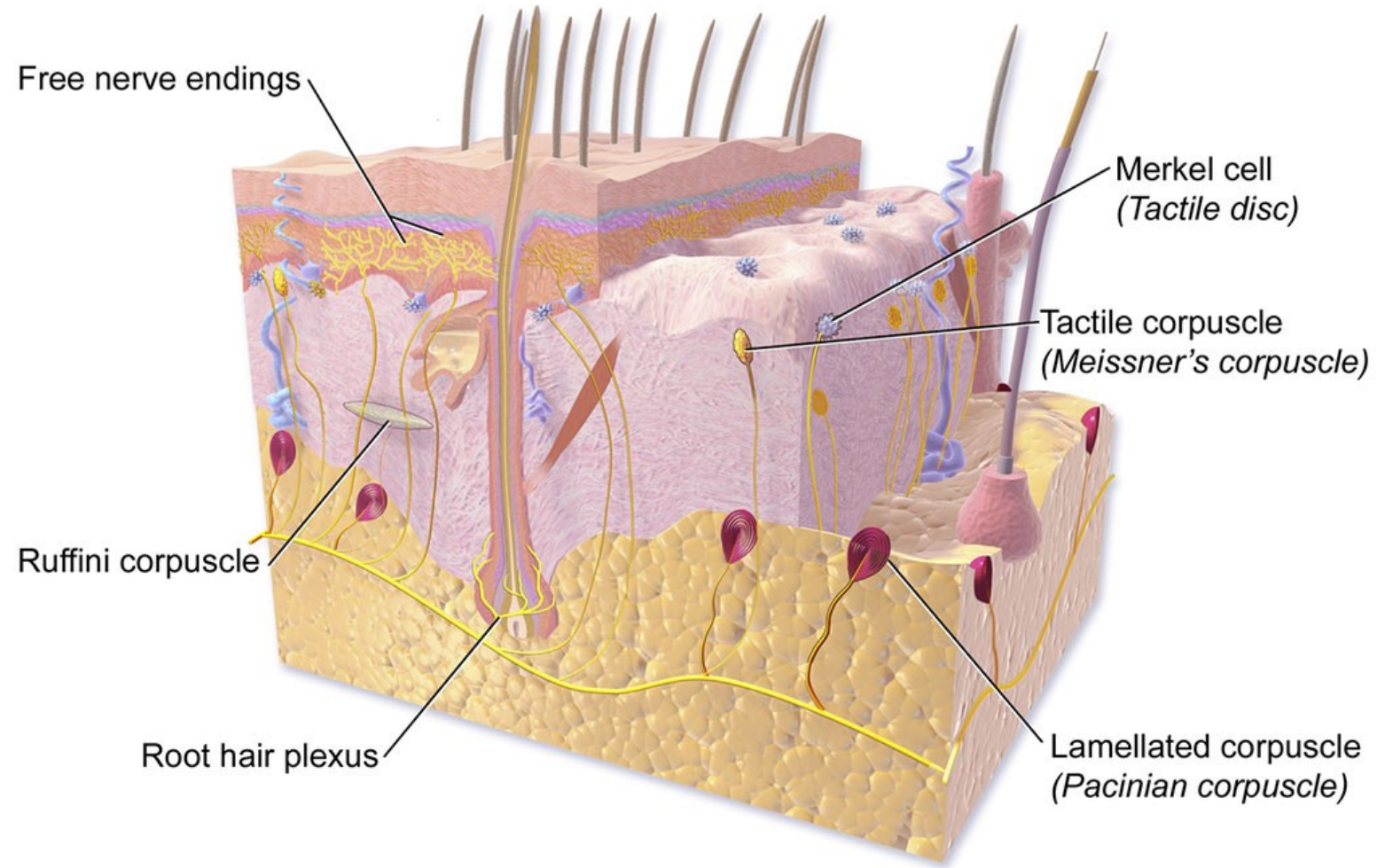
Sluch



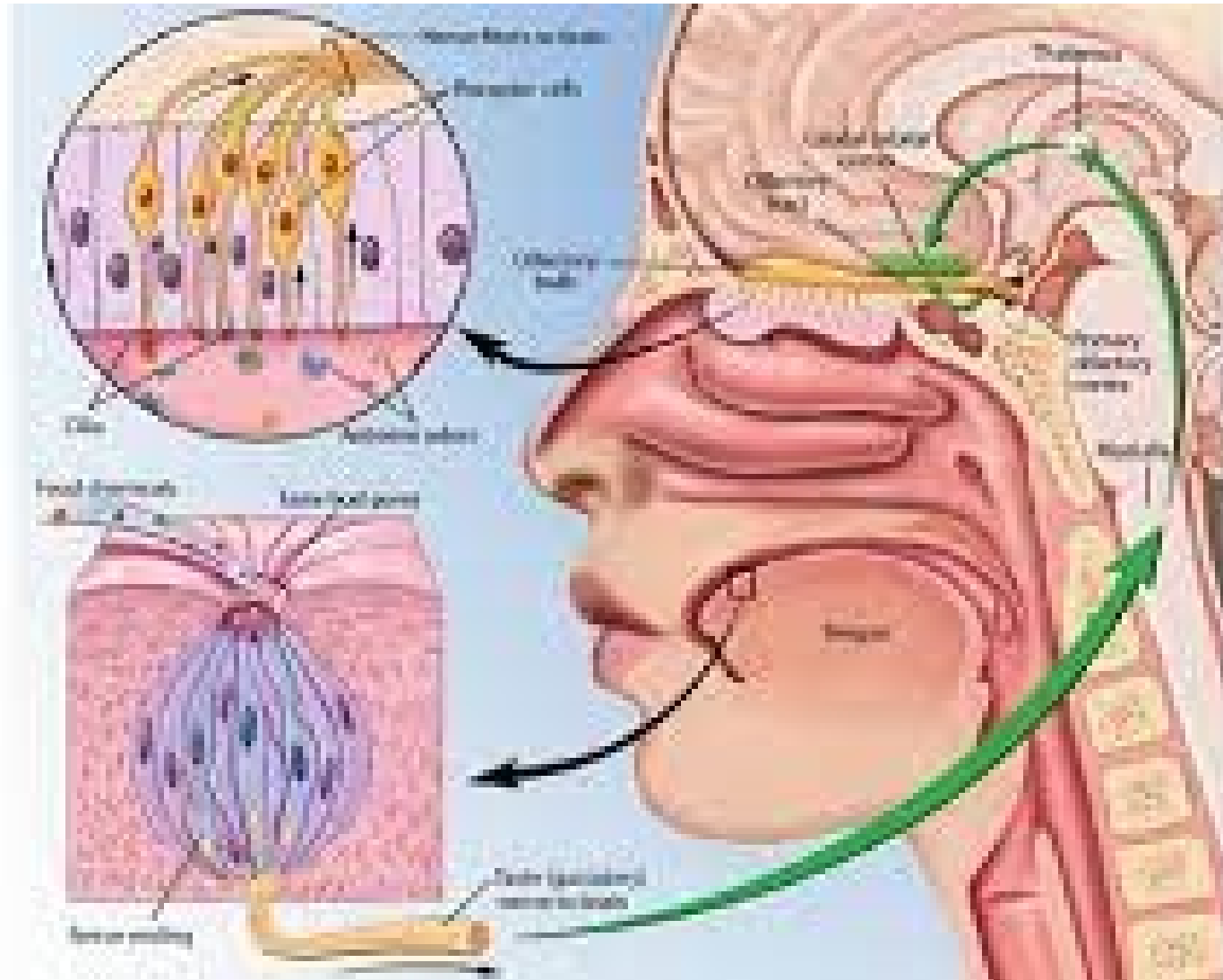
Poruchy sluchu



Hmat



Čich



Chut'

