The Journal of Emergency Medicine, Vol. 61, No. 5, pp. 590–591, 2021
© 2021 Elsevier Inc. All rights reserved.
0736-4679/$ - see front matter

https://doi.org/10.1016/j.jemermed.2021.07.071

Visual Diagnosis in Emergency Medicine

Penetrating Intracranial Taser Injury

Brandon Delavar, and Maxwell A. Thompson

University of Alabama at Birmingham, Birmingham, Alabama
Reprint Address: The University of Alabama at Birmingham, AB 990J, 701 20th St South Birmingham, AL 35233.

☐ **Keywords—penetrating; intracranial; taser; Trauma; CT scan; images**

Case Report

A 22-year-old man presented to the emergency department after a taser injury. The patient was in an altercation with law enforcement when he received a taser shot to his forehead from approximately 6 feet away (Figures 1 and 2). The patient reported a loss of consciousness during the event and complained of a headache, but was otherwise neurologically intact with Glasgow Coma Scale score of 15. Computed tomography imaging demonstrated a taser barb invading the inner cortex of the right frontal bone (Figures 3 and 4). The patient was admitted to the neurosciences intensive care unit, where neurosurgery attempted bedside removal (Figure 5). Bedside removal failed, as part of the taser end piece remained, crossing the inner table of the right frontal calvarium extending slightly into the right frontal extra-axial space, and the patient was taken to the operating room for complete removal. Postoperatively, the patient made an unremarkable and complete recovery.

Figure 1. Image of patient with taser barb to forehead.

Figure 2. Image of patient with taser barb to forehead.

Discussion

We present a case of penetrating intracranial taser injury. Penetrating taser injuries to the head represent a potentially dangerous scenario that usually requires operative removal or bedside removal under sedation (1,2). This case highlights the dangers of taser injuries to the head causing cranial injury, while other reports have also demonstrated injury causing seizures or ocular trauma (3,4). Including our patient, most case reports demonstrate full neurologic recovery of patients. As with our case and multiple previous case reports, bedside removal typically fails, as the taser lead generally breaks during attempted removal, leaving part of the device embedded

Received: 18 June 2021; Final submission received: 26 July 2021;
Accepted: 31 July 2021

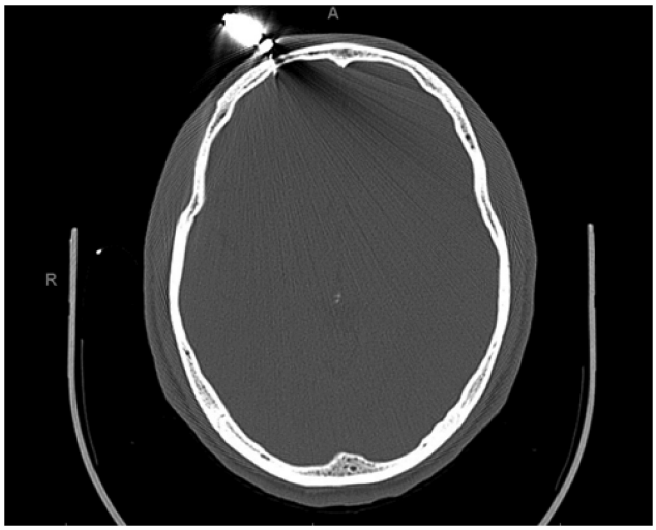

Figure 3. Axial view of taser barb invading the inner cortex of the right frontal bone.

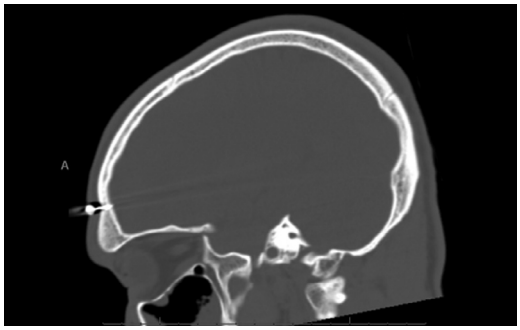

Figure 4. Sagittal view of taser barb invading the inner cortex of the right frontal bone.

Figure 5. Image of taser barbwithout presence of end piece after attempted bedside removal.

in the cranial vault (1). However, there is at least one case report of successful bedside removal (2).

References

1. Kaloostian P, Tran H. Intracranial taser dart penetration: literature review and surgical management. J Surg Case Rep 2012;2012(6):10.
2. Chandler J, Martin BP, Graham DD. TASER® injury to the forehead. J Emerg Med 2013;44:e67–8.
3. Bui ET, Sourkes M, Wennberg R. Generalized tonic-clonic seizure after a taser shot to the head. CMAJ 2009;1180:625–6.
4. Ng W, Chehade M. Taser penetrating ocular injury. Am J Ophthalmol 2005;139:713–15.